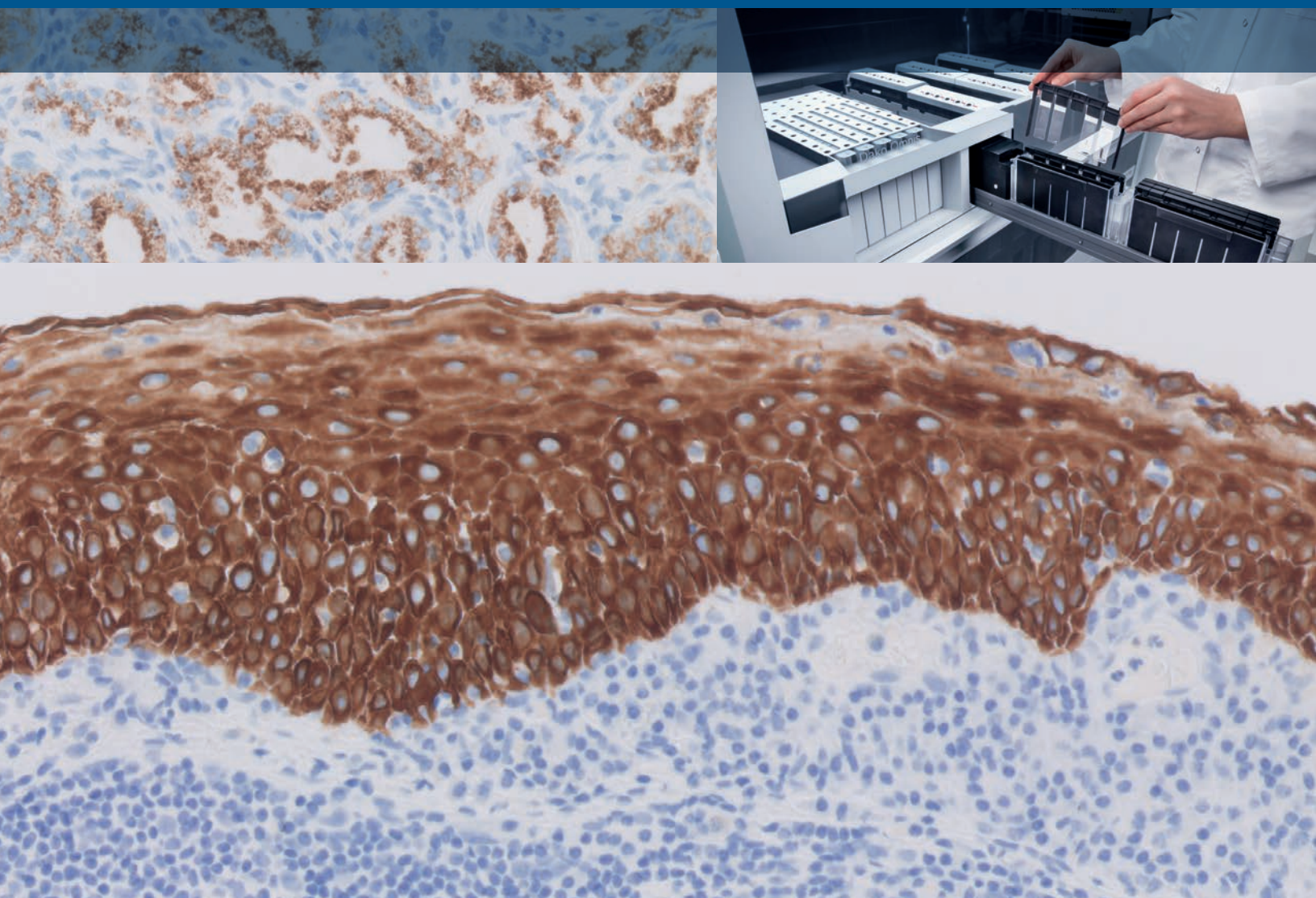


# FLEX Ready-to-Use Atlas of Controls

First Edition





# Comitted to raising the bar for higher quality

For years, pathology laboratories around the world have had to face and adapt to an increasing number of challenges, while continuing to strive to deliver accurate IHC results for patients. One of the most important of these challenges is to make continuous improvements to maintain the quality of staining, and to be a professional counterpart and key resource to oncologists and other clinicians. To help with this, organizations such as CAP, UK NEQAS, cIQc, and NordiQC have successfully implemented many initiatives to improve standardization in immunohistochemistry (IHC).

The Dako FLEX Ready-to-Use (RTU) primary antibodies work on formalin-fixed, paraffin-embedded tissue sections as a set of dedicated reagents for clinical routine diagnostics. The FLEX RTU concept is unique, since it focuses on delivering the correct diagnostic end-result while improving time to diagnosis, reducing manual error rates, and simplifying information retrieval through bar-coded labeling. Equally important, it maintains and delivers reliable staining performance.

The FLEX RTU concept was launched in 2008, and the staining performance of the products was developed in collaboration with leading pathologists and their laboratory managers. In the process of ensuring desired staining performance, a panel of these distinguished anatomic pathology experts specified the relevant criteria and reviewed the staining results obtained during development of all the antibodies. We wish to thank the members of our expert panel and their laboratory managers for sharing their knowledge and insight: Mr. Andrew Dodson, Royal Liverpool University Hospital, UK • Prof. Dr. Alvin Martin, University of Louisville School of Medicine Department of Pathology, USA • Mr. Søren Nielsen, Aalborg Hospital, Department of Pathology, Denmark • Prof. Dr. Robert Osamura, Tokai University School of Medicine, Japan • Dr. Clive Taylor, Keck School of Medicine of USC, USA • Ms. Sheron Lear, University of Louisville School of Medicine Department of Pathology, USA • Dr. David Dabbs, Magee Women's Hospital, USA • Dr. Miguel Piris Centro Nacional de Investigaciones Oncologicas Carlos III, Spain • Dr. Kengo Takeuchi, Japanese Foundation for Cancer Research, Japan • Prof. Dr. Bharat Jasani, Cardiff University, UK • Ms. Lydia Sánchez Verde Centro Nacional de Investigaciones Oncologicas Carlos III, Spain • Dr. Assia Bassarova, Radiumhospitalet, Norway • Dr. John Gosney, Royal Liverpool University Hospital, UK • Ms. Kim McManus, Magee Women's Hospital, USA • Dr. Jahn Nesland, Radiumhospitalet, Norway. We also would like to thank Cooperative Human Tissue Network (funded by the National Cancer Institute) for providing valuable human tissues for our studies.

For this new Atlas of Controls, Søren Nielsen, in his current role as Director of NordiQC, Denmark, has reviewed all stains and carefully selected representative area of stained sections containing relevant high and low expression structures for quality control for each antibody.

**This Atlas of Controls is by no means intended to override the information contained in the Instructions for Use and the professional judgment of a certified pathologist. The contents and descriptions of staining patterns are provided to add additional information and suggestions for quality control only, and Agilent neither claims nor warrants the universal validity of the information provided, as there are national and professional differences in the acceptance of the relevance of various markers and related quality control tissues.**

# They key to successful IHC results is control tissue

Despite great advances in genetic testing, especially in next generation sequencing, immunohistochemistry is still the most important technique in diagnostic pathology and is an essential daily tool for cancer classification in most laboratories worldwide. There is an ongoing focus on utilizing and expanding IHC for purposes such as implementation of new markers, use of established markers in new areas and optimization of immunohistochemical techniques.

Many laboratories are now participating in external quality assessment (EQA) schemes which detect differences of IHC quality between laboratories and provide guidance on how to achieve optimal and comparable results. Still, there is a need for improvements and for communication in the field of IHC, particularly due to the considerable variations in both standards and routines among laboratories.

To obtain appropriate sensitivity and specificity in developing the FLEX RTU system, the performance of each primary antibody has been tested on a wide range of cancers which reflect the diagnostic applications of the specific antibody. Each primary antibody has also been tested on various benign tissues to identify positive controls that could be recommended. Identification of benign tissue for recommended control and the precise description and photographs of microscopic reaction patterns in the Atlas of Controls are truly unique and will greatly facilitate final quality evaluation of the antibody markers in laboratories. By providing access to a photo gallery and library of detailed information on appropriate controls in the use of antibodies – and how to interpret control and reaction patterns – the Atlas of Controls should prove to be a valuable tool for all laboratories that perform IHC from local clinics and hospitals to large university laboratories. To obtain the performance portrayed in the Atlas of Controls, the Dako FLEX RTU antibodies must be used within the system frames established by Agilent.



Søren Nielsen

Director, NordiQC  
Aalborg University Hospital  
Denmark

## FLEX RTU Concept

Several requirements must be fulfilled for a stain to be optimal. The variation in the staining intensity is a sum of the total variation of all possible influencing factors.

- **Biological variances.** The protocol must be able to identify the antigen in normal tissue, with both high and low expression, and more importantly unknown levels of expression in abnormal tissue. Tumors are known to exhibit very heterogeneous antigen expression.
- **Ischemic time.** The protocol should ideally 'iron out' different degrees of antigen degradation and retrieval (to a certain point).
- **Time of fixation.** The protocol must be able to identify the same level of antigen expression, independent of the time of fixation within the overall validated timeframe.
- **Fixative types.** The widespread use of formalin fixation has narrowed this factor.
- **Tissue thickness.** The protocol should encompass the effects of differences in section thickness on staining intensity.

The aim when developing optimal IHC protocols is to achieve a robust and correct visualization of the target antigen in clinical samples with unknown expression levels, thereby contributing to a valid diagnosis.

## Optimal protocols

Creating an optimal protocol is – in theory – quite simple: Optimize the protocol parameters to stain:

- Normal tissue elements with high expression of the antigen (HE)
- Normal tissue elements with low expression of the antigen (LE)
- Background staining of non-expressing elements (NE) should not cause risk of misinterpretation of any positive signal

This "HELENE" concept should be achieved using the same protocol settings for the antibody. Abnormal tissues of interest should preferably express the antigen within the upper and lower limits of the control tissue elements.

## Control Tissue

Atlas of Controls, first edition, shows stains of control tissue for each FLEX RTU antibody in our portfolio. The stains can be used as guidelines for ensuring that optimal staining results have been achieved when using any of our FLEX RTU antibodies on our staining platforms.

- **High Expression:** The tissue type(s) should provide **moderate** to **strong** staining intensity in the specified cell types and cellular structures. Background staining should be non-existing or minimal.
- **Low expression:** The tissue type(s) should provide **weak** to **moderate** staining intensity in the specified cell types and cellular structures.
- **Non-expression:** The cell type(s) that should be negative are typically intrinsic, meaning no extra tissue types are needed for this control.

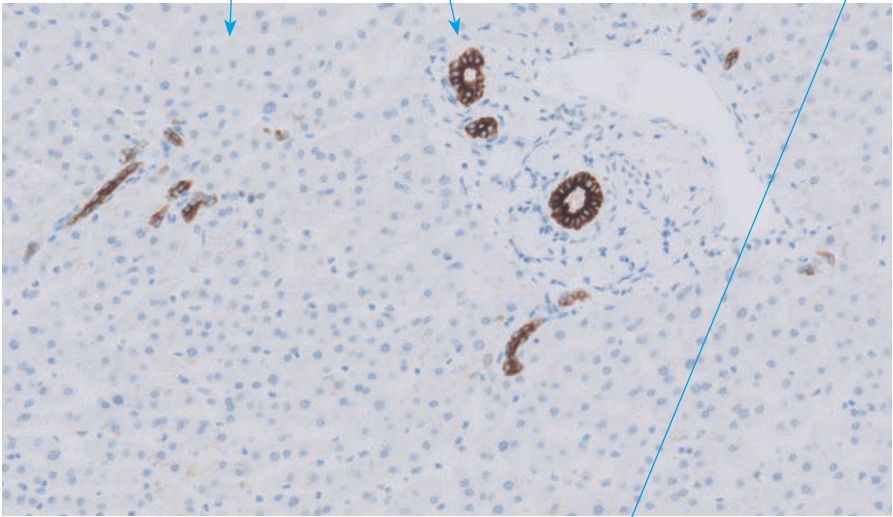
# How to read

**Antibody:** Monoclonal Mouse Anti-Human Cytokeratin 19  
**Clone:** RCK108  
**Code:** GA615 | IR615

Cellular location of staining reaction

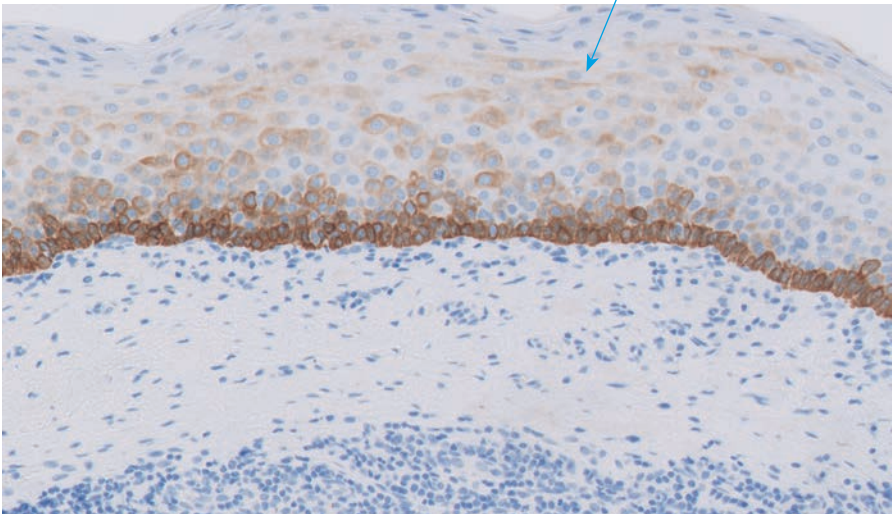
Not applicable

Reaction Location	Cytoplasm	
Quality Control	Liver	Tonsil
High Expression	Epithelial cells of bile ducts show a moderate to strong staining reaction.	NA
Low Expression	NA	Squamous epithelial cells focally show a weak to moderate staining reaction that is strongest in the basal layer.
Non-expression	Hepatocytes	NA



Tissue type and magnification

Liver (10x)



Tonsil (20x)

The basis for evaluating the quality of IHC performance is the use of proper controls. Benign tissue that is easily accessible and interpretable is recommended as control for most antibodies in the FLEX RTU system. Accompanying photos illustrate the reaction pattern of the cell types and/or cellular structures which should be identified in the control tissue. These cell types and/or cellular structures are important to identify in order to monitor appropriate FLEX RTU performance. The quality indicators are divided into high expression (HE, moderate to strong) and low expression (LE, weak to moderate) structures. When using the FLEX RTU system on control tissue, it will be normal to find a strong staining reaction in some structures (HE structures) along with a less strong staining reaction in other structures (LE structures). Negative cells (NE structures) that are important for evaluation are noted in the non-expression row.

**Please note that for some antibodies only HE structures are identified, and for some antibodies no benign control tissue exists. Usually, many cell types will be negative for each antibody and only important cell types will be indicated in the Non-expression row.**



All stains presented in Atlas of Controls were made by Histology-DK, R&D, Agilent Technologies, Glostrup, Denmark. All stainings were done according to the protocols in the Instructions for Use for each FLEX RTU antibody on Dako Omnis or Autostainer Link 48 staining platform, respectively. The slides were scanned on Philips IntelliSite Pathology Solution and relevant areas of the whole slide image were selected and described by Søren Nielsen, Director of NordiQC.

## Atlas of Controls - Table of Contents

Actin (Muscle)	10
Actin (Smooth Muscle)	11
Alpha-1-Antitrypsin	12
Alpha-1-Fetoprotein	13
AMACR	14
Amyloid A	15
B-Cell-Specific Activator Protein	16
BCL2 Oncoprotein	17
BCL6 Protein	18
Beta-Catenin	19
CA 125	20
Calcitonin	21
Caldesmon	22
Calretinin	23
Carcinoembryonic Antigen	24
CD1a	25
CD2	26
CD3	27
CD4	28
CD5	29
CD7	30
CD8	31
CD10	32
CD15	33
CD19	34
CD20cy	35
CD21	36
CD23	37
CD30	38
CD31, Endothelial Cell	39
CD34, Class II	40
CD43	41
CD45, Leucocyte Common Antigen	42
CD56	43
CD57	44
CD68	45
CD68	46
CD79a	47
CD99, MIC2 Gene Products, Ewing's Sarcoma Marker	48
CD138	49
CD246, ALK Protein	50
CDX-2	51
Chorionic Gonadotropin	52
Cyclin D1	53
Cytokeratin	54
Cytokeratin 5/6	55
Cytokeratin 7	56
Cytokeratin 8/18	57
Cytokeratin 17	58
Cytokeratin 18	59
Cytokeratin 19	60
Cytokeratin 20	61
Cytokeratin, High Molecular Weight	62
Cytomegalovirus	63
Desmin	64
E-Cadherin	65
Epithelial Antigen	66
Epithelial Membrane Antigen	67
Epstein-Barr Virus, LMP	68
ERCC1	69

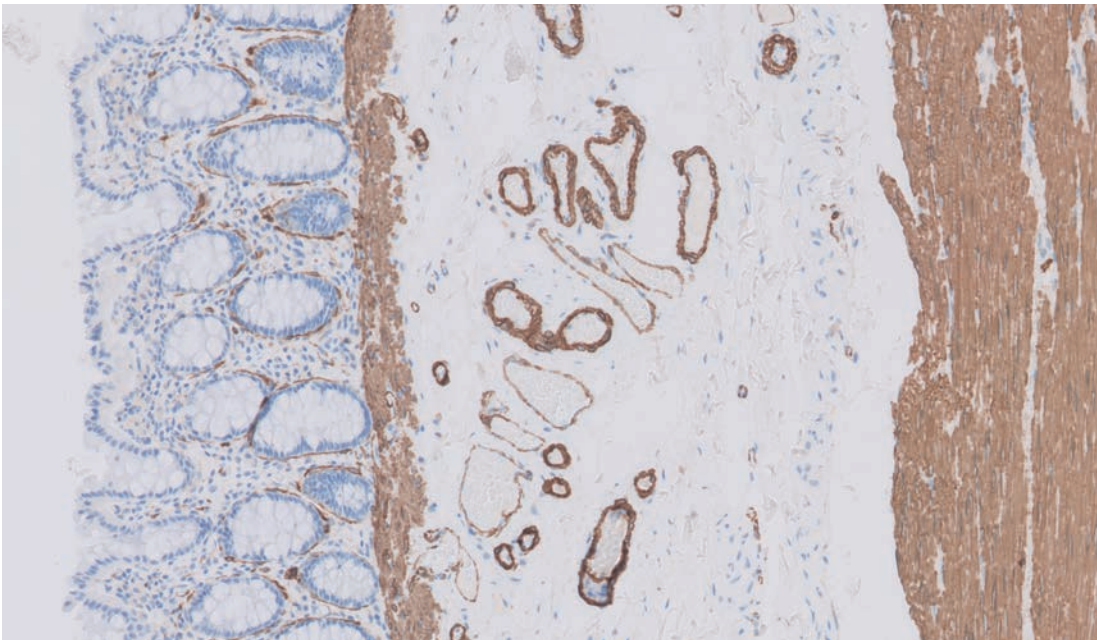


## Atlas of Controls - Table of Contents

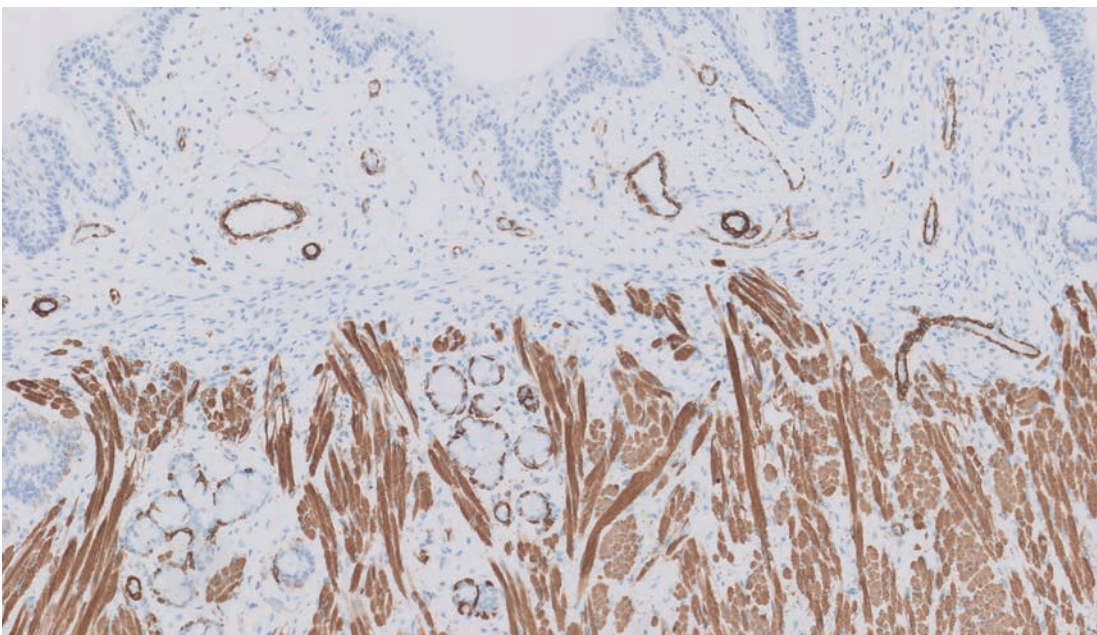
Estrogen Receptor $\alpha$ .....	70
Estrogen Receptor $\alpha$ .....	71
Ets-Related Gene (ERG).....	72
Gastrin.....	73
GCDFP-15.....	74
Glial Fibrillary Acidic Protein.....	75
Helicobacter Pylori.....	76
Hepatocyte.....	77
Herpes Simplex Virus Type 1.....	78
IgA.....	79
IgD.....	80
IgG.....	81
IgM.....	82
Inhibin $\alpha$ .....	83
Insulin.....	84
Kappa Light Chains.....	85
Ki-67 Antigen.....	86
Lambda Light Chains.....	87
Mammaglobin.....	88
Mast Cell Tryptase.....	89
Melan-A.....	90
Melanosome.....	91
MUC2.....	92
MUC5AC.....	93
MUM1 Protein.....	94
MutL Protein Homolog 1 (MLH1).....	95
MutS Protein Homolog 2 (MSH2).....	96
MutS Protein Homolog 6 (MSH6).....	97
Myeloperoxidase.....	98
Myogenin.....	99
Myosin Heavy Chain (Smooth Muscle).....	100
Neurofilament Protein.....	101
Neuron-Specific Enolase.....	102
Nucleophosmin.....	103
Octamer-Binding Transcription Factor 3/4.....	104
p53 Protein.....	105
p63 Protein.....	106
Placental Alkaline Phosphatase.....	107
Pneumocystis Jiroveci.....	108
Podoplanin.....	109
Postmeiotic Segregation Increased 2 (PSM2).....	110
Progesterone Receptor.....	111
Progesterone Receptor.....	112
Prostate-Specific Antigen.....	113
Prostate-Specific Membrane Antigen.....	114
Prostein.....	115
Renal Cell Carcinoma Marker.....	116
S100.....	117
Synaptophysin.....	118
Terminal Deoxynucleotidyl Transferase (TdT).....	119
Thyroglobulin.....	120
Thyroid Transcription Factor.....	121
Tyrosinase.....	122
Villin.....	123
Vimentin.....	124
Von Willebrand Factor.....	125
Wilms' Tumor 1 Protein.....	126
ZAP-70.....	127

**Antibody:** Monoclonal Mouse Anti-Human  
**Clone:** Actin (Muscle)  
**Code:** HHF35  
 IR700

Reaction Location	Cytoplasm	
Quality Control	Colon/Appendix	Tongue
High Expression	The smooth muscle cells in the lamina muscularis mucosa show a moderate to strong staining reaction.	The striated muscle cells in tongue show a moderate to strong staining reaction.
Low Expression	NA	The myoepithelial cells lining the mucous/salivary glands show a weak to moderate staining reaction.
Non-expression	Epithelial cells.	NA



Colon (10x)

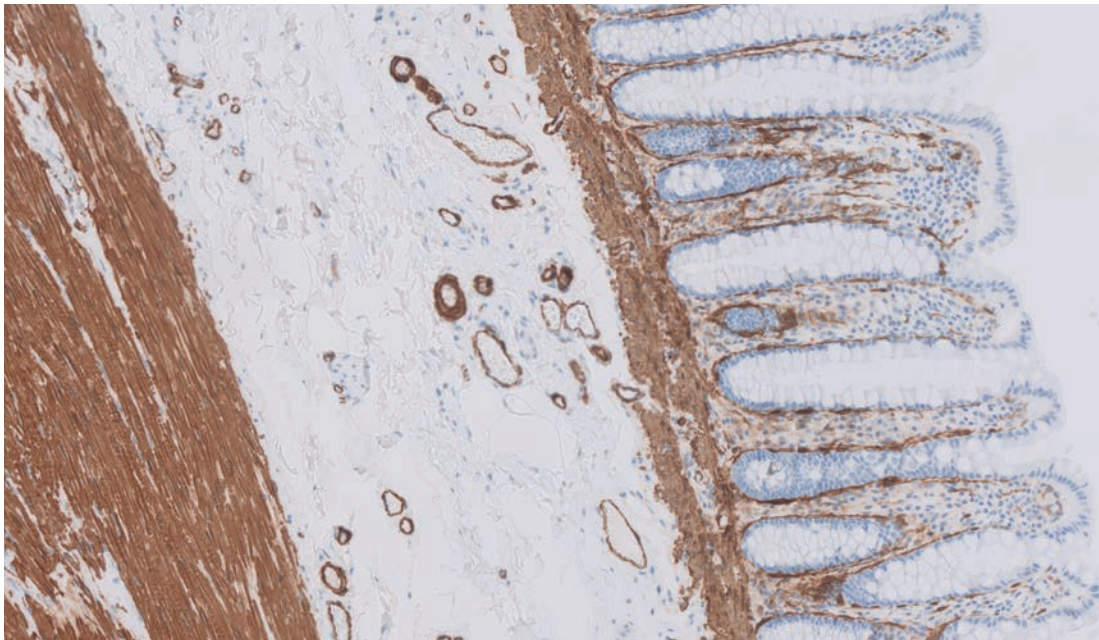


Tongue (10x)

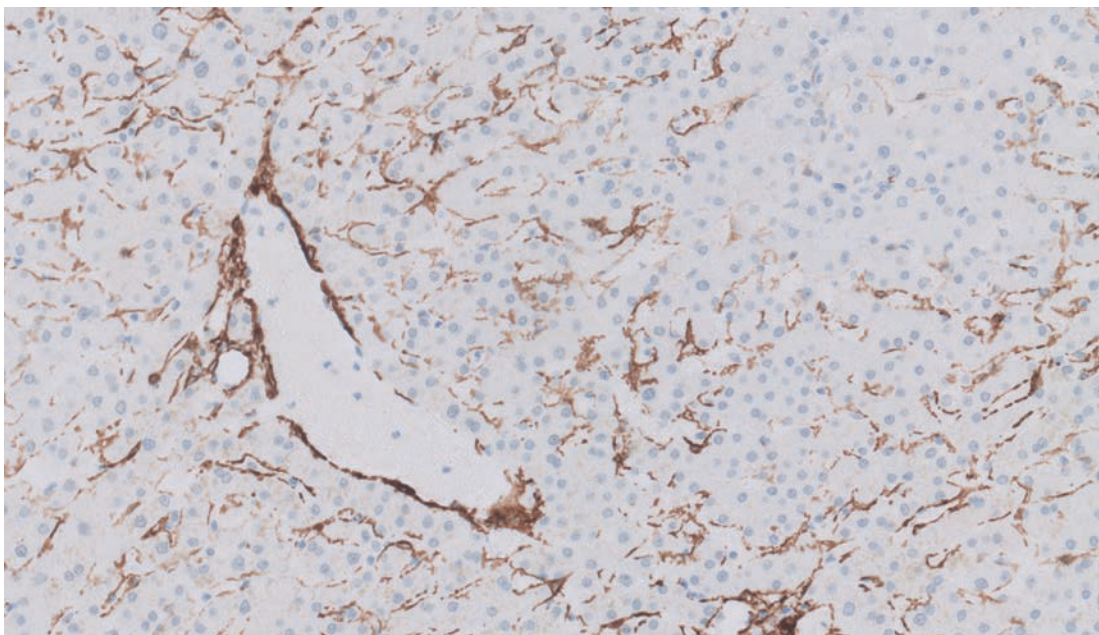
**Antibody:** Monoclonal Mouse Anti-Human  
**Clone:** Actin (Smooth Muscle)  
**Code:** 1A4  
 GA611 | IR611

Reaction Location	Cytoplasm	
Quality Control	Colon/Appendix	Liver
High Expression	Smooth muscle cells in the lamina muscularis mucosa show a moderate to strong staining reaction.	Smooth muscle cells in large vessels show a moderate to strong staining reaction.
Low Expression	NA	Smooth muscle cells lining the liver sinusoids show a weak to moderate staining reaction.
Non-expression	Epithelial cells.	Hepatocytes

Note: No staining reaction should be seen in appendiceal columnar epithelial cells, lymphocytes or liver cells.



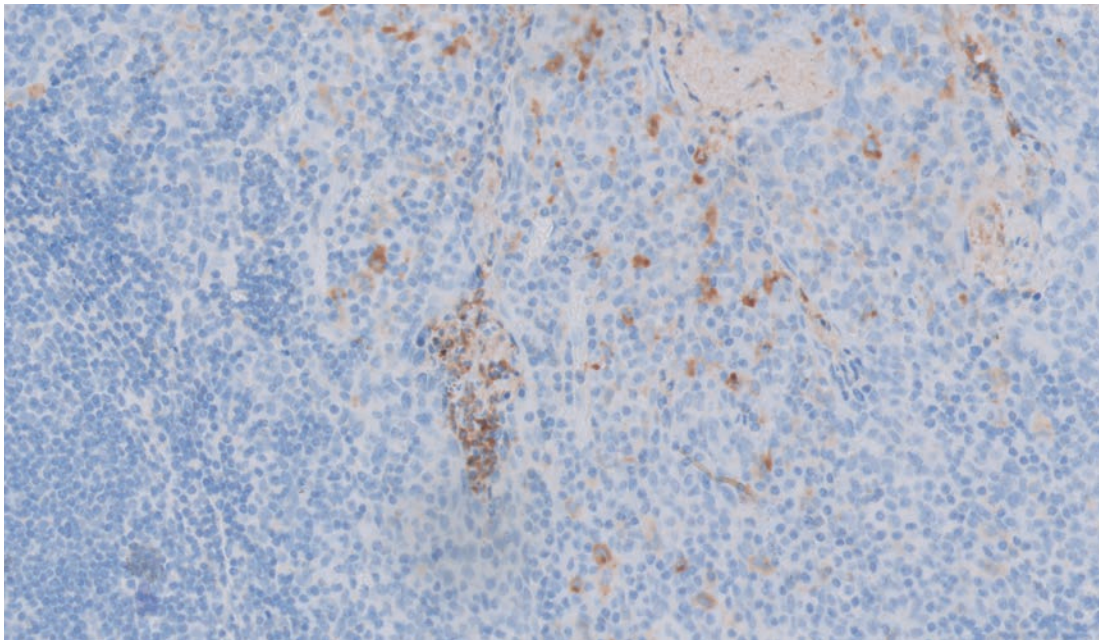
Colon (20x)



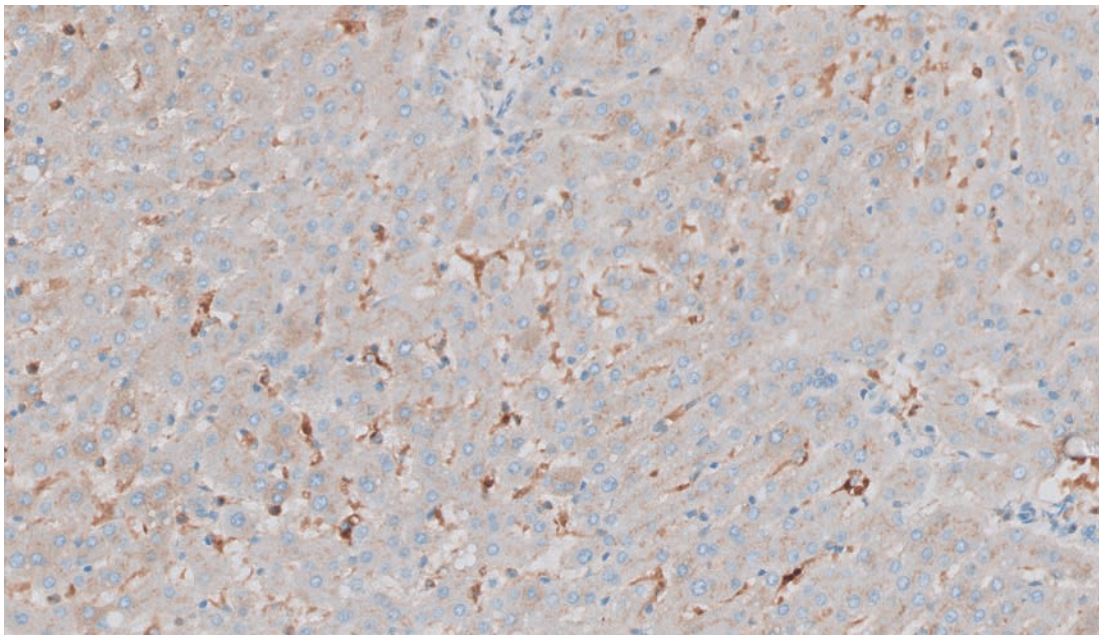
Liver (20x)

**Antibody:** Polyclonal Rabbit Anti-Human  
**Alpha-1-Antitrypsin**  
**Clone:** Polyclonal  
**Code:** GA505 | IR505 *Not available in the US*

Reaction Location		Cytoplasm	
Quality Control		Tonsil	Liver
High Expression		Macrophages and neutrophil granulocytes show a moderate to strong staining reaction.	Kupffer cells show a moderate to strong staining reaction.
Low Expression		NA	Hepatocytes show a weak to moderate staining reaction.
Non-expression		Lymphocytes	NA



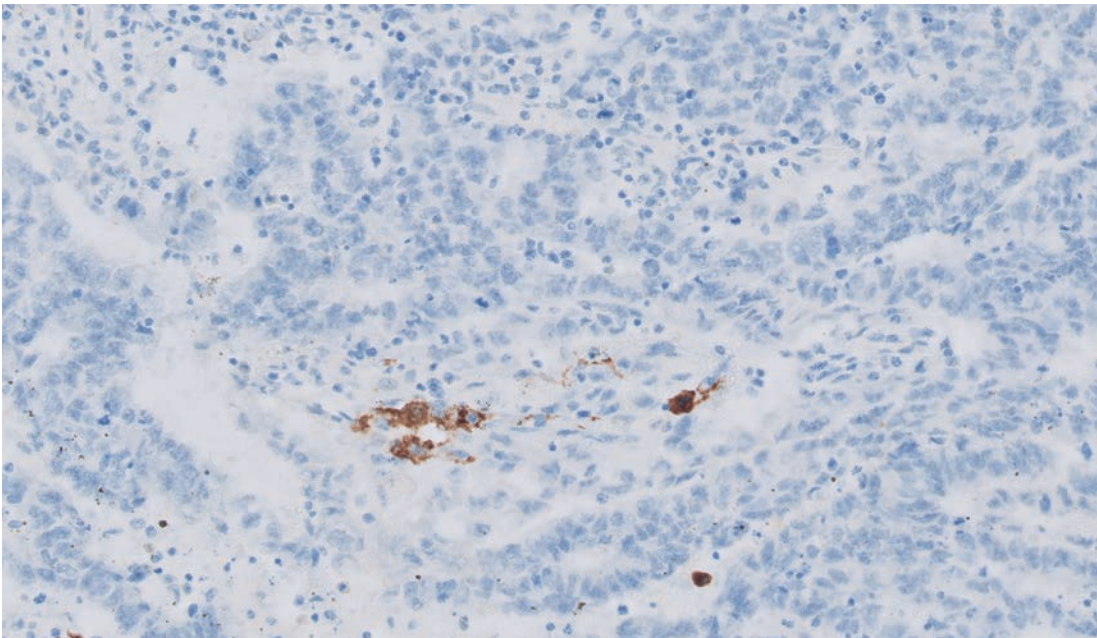
Tonsil (20x)



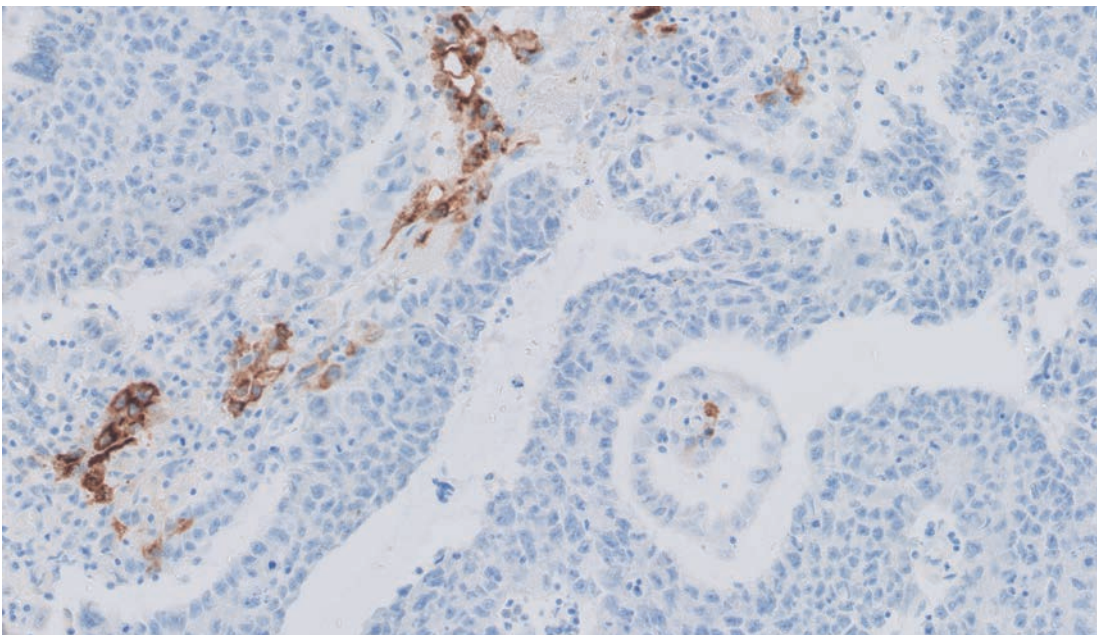
Liver (20x)

**Antibody:** Polyclonal Rabbit Anti-Human  
**Alpha-1-Fetoprotein**  
**Clone:** Polyclonal  
**Code:** GA500 | IR500

Reaction Location	Cytoplasm
Quality Control	<b>Embryonal carcinoma</b>
High Expression	Focally, neoplastic cells of embryonal carcinoma show a moderate to strong staining reaction.
Low Expression	NA
Non-expression	NA



Embryonal carcinoma (20x)

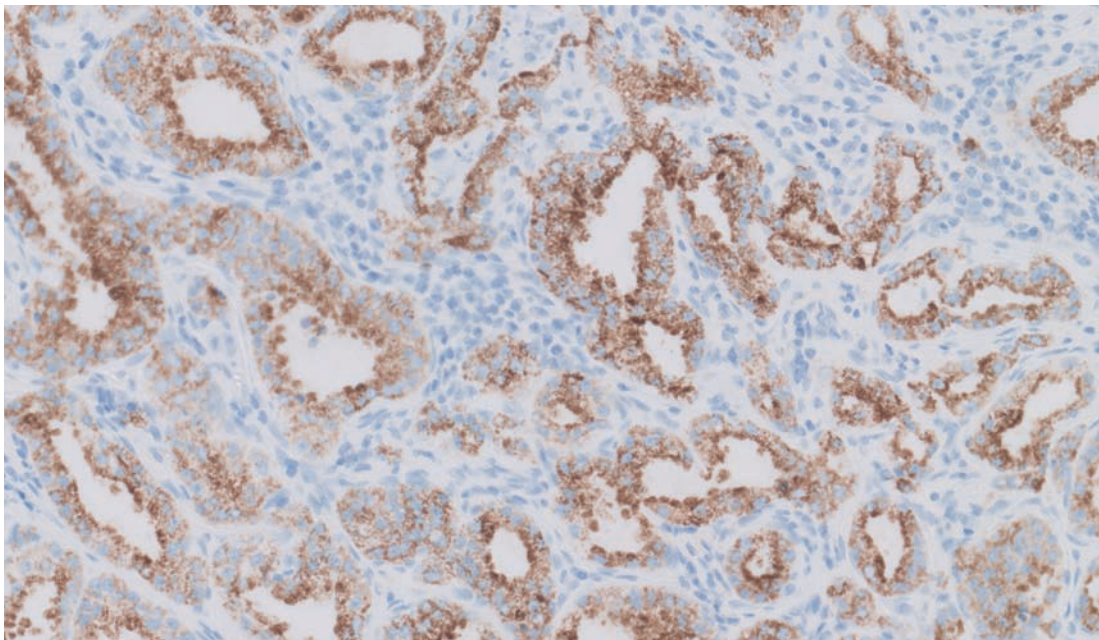


Embryonal carcinoma (20x)

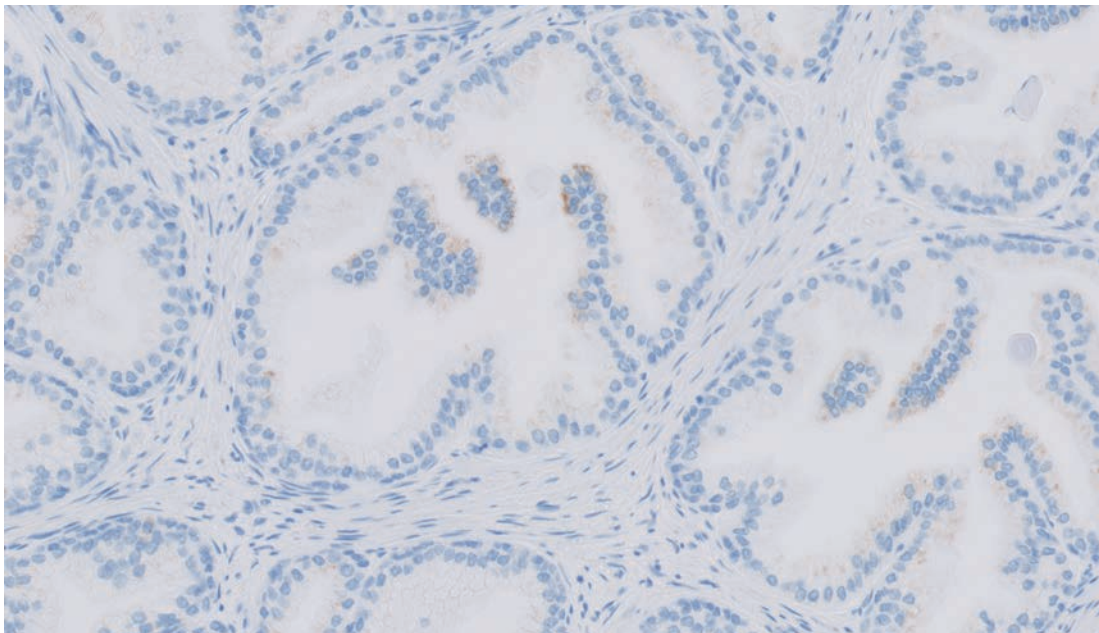
**Antibody:** Monoclonal Mouse Anti-Human  
**Clone:** AMACR  
**Code:** 13H4  
 GA060 | IR060

Reaction Location	Cytoplasm	
Quality Control	Prostate adenocarcinoma	Benign prostatic hyperplasia
High Expression	The majority of neoplastic cells show a moderate to strong staining reaction.	NA
Low Expression	NA	NA
Non-expression	NA	The epithelial cells of hyperplastic prostate glands are negative or only show a weak focal staining reaction.

Note: The epithelial cells in normal prostate should be negative or only show a focal staining reaction.



Prostate adenocarcinoma (20x)

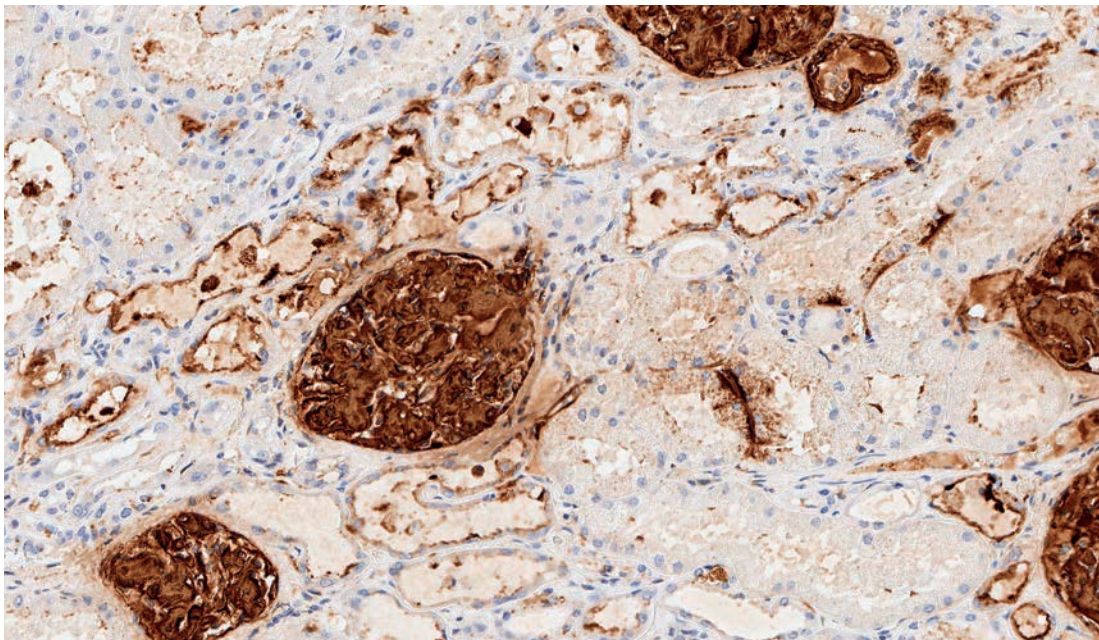


Benign prostatic hyperplasia (20x)

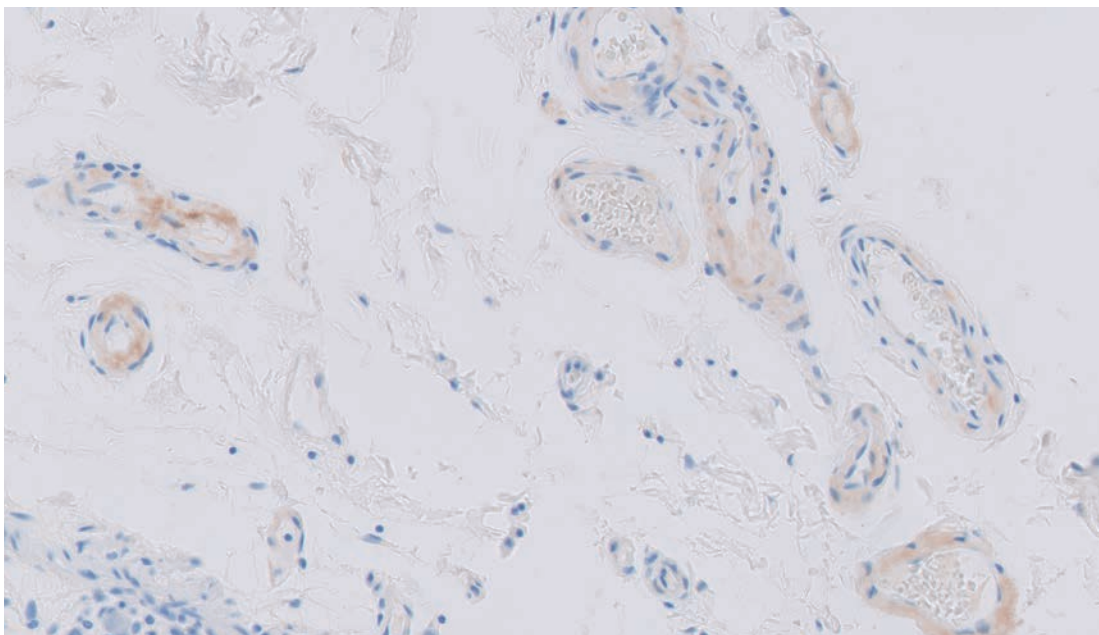
Antibody: Monoclonal Mouse Anti-Human  
 Clone: Amyloid A  
 mc1  
 Code: GA605 | IR605

Reaction Location	Extracellular and cytoplasm	
Quality Control	Kidney with amyloidosis	Colon with amyloidosis
High Expression	Large smooth muscle cells with deposits of amyloid A show a weak to strong staining reaction.	NA
Low Expression	Large smooth muscle cells with deposits of amyloid A show a weak to strong staining reaction.	Basal cells with amyloid A deposits show a weak to moderate staining reaction.
Non-expression	Normal tissue should be negative.	Normal tissue should be negative.

Note: The antibody occasionally labels serum.



Kidney (20x)

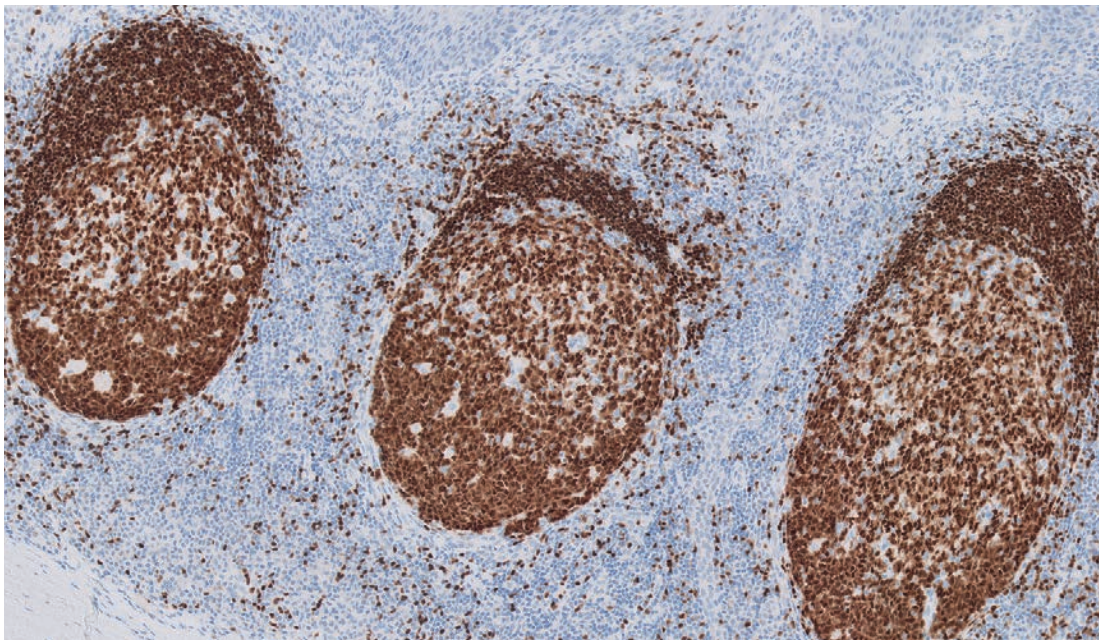


Colon (20x)

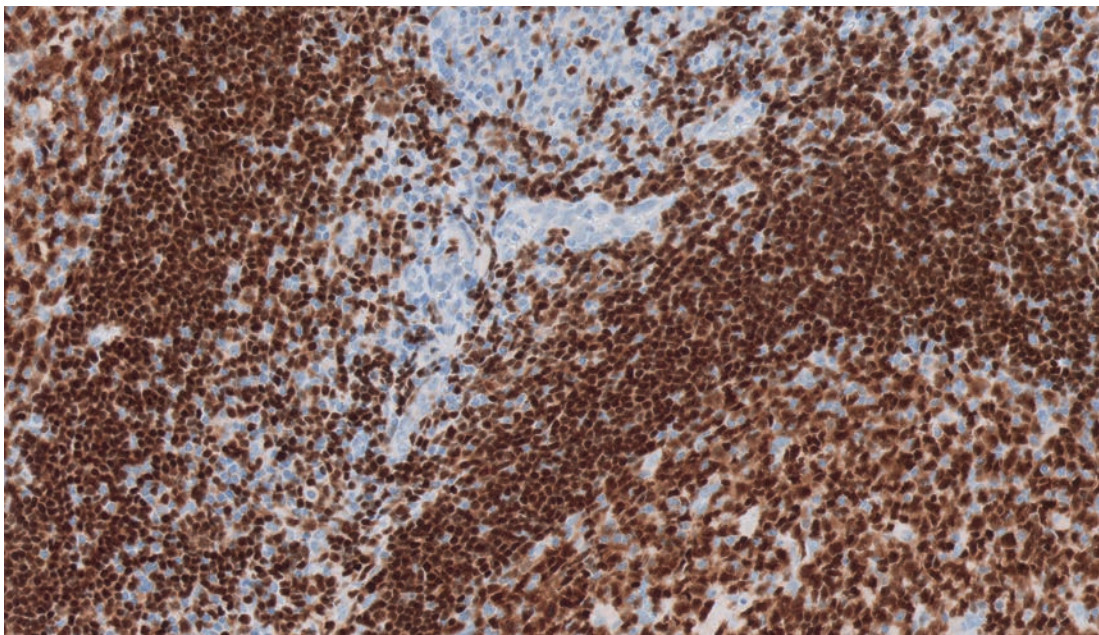
**Antibody:** Monoclonal Mouse Anti-Human  
B-Cell-Specific Activator Protein  
**Clone:** DAK-Pax5  
**Code:** GA650 | IR650

Reaction Location	Nucleus
Quality Control	Tonsil
High Expression	B cells in the mantle zone and in the germinal center show a moderate to strong staining reaction.
Low Expression	NA
Non-expression	Squamous epithelial cells.

Note: A diffuse cytoplasmic staining reaction can be observed in cells with intense nuclear staining reaction.



Tonsil (10x)



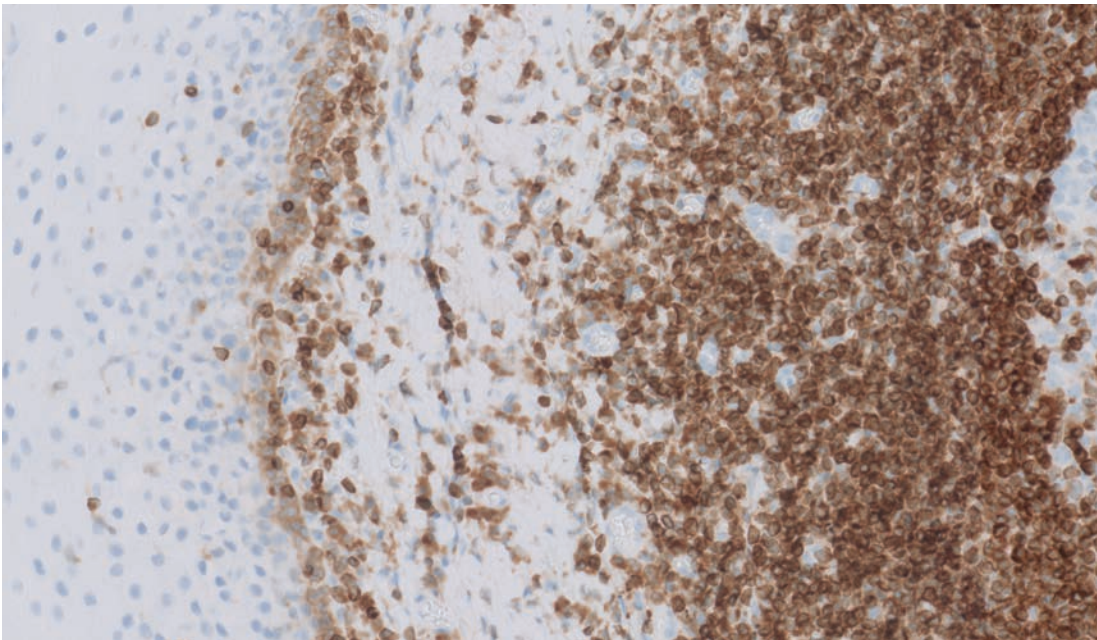
Tonsil (20x)



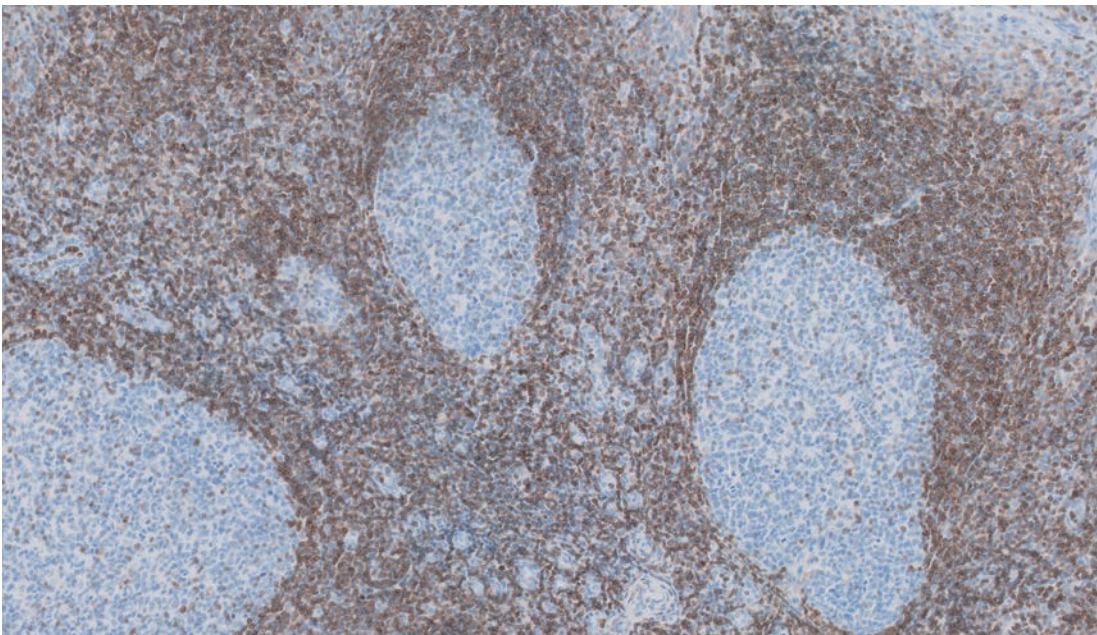
**Antibody:** Monoclonal Mouse Anti-Human  
**Clone:** BCL2 Oncoprotein  
**Code:** 124  
**Code:** IR614

Reaction Location	Cytoplasm
Quality Control	<b>Tonsil</b>
High Expression	Interfollicular and mantle zone lymphocytes in the peripheral mantle zone and interfollicular lymphocytes show a moderate to strong staining reaction.
Low Expression	Basal squamous epithelial cells show a weak to moderate staining reaction.
Non-expression	Germinal center B cells.

Note: Some follicular lymphomas may be negative due to mutations in the epitope recognized by the antibody.



Tonsil (20x)

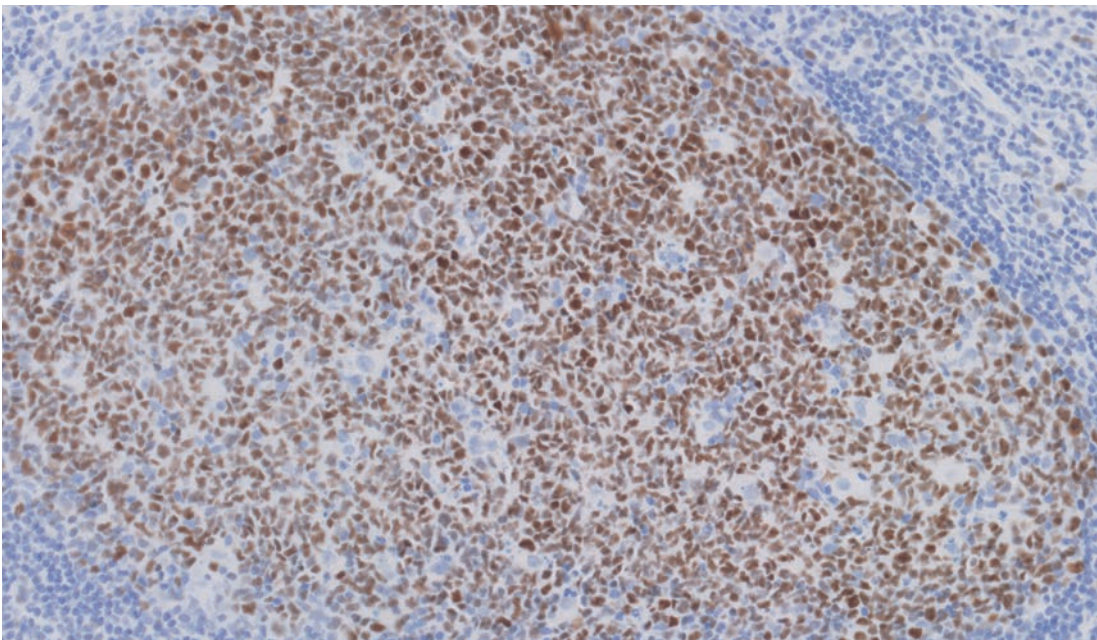


Tonsil (10x)

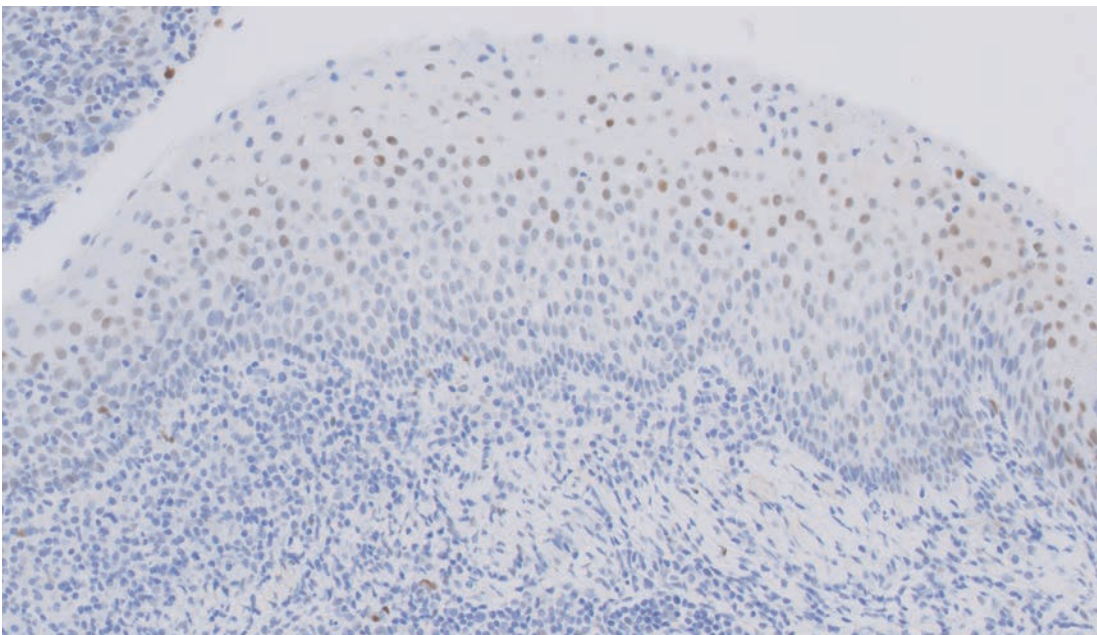
**Antibody:** Monoclonal Mouse Anti-Human  
**Clone:** BCL6 Protein  
**Code:** PG-B6p  
GA625 | IR625

Reaction Location	Nucleus
Quality Control	Tonsil
High Expression	Germinal center B cells show a moderate to strong staining reaction.
Low Expression	Squamous epithelial cells show a weak to moderate staining reaction.
Non-expression	NA

Note: Approximately 10% of germinal center T cells in tonsil are labeled.



Tonsil (20x)

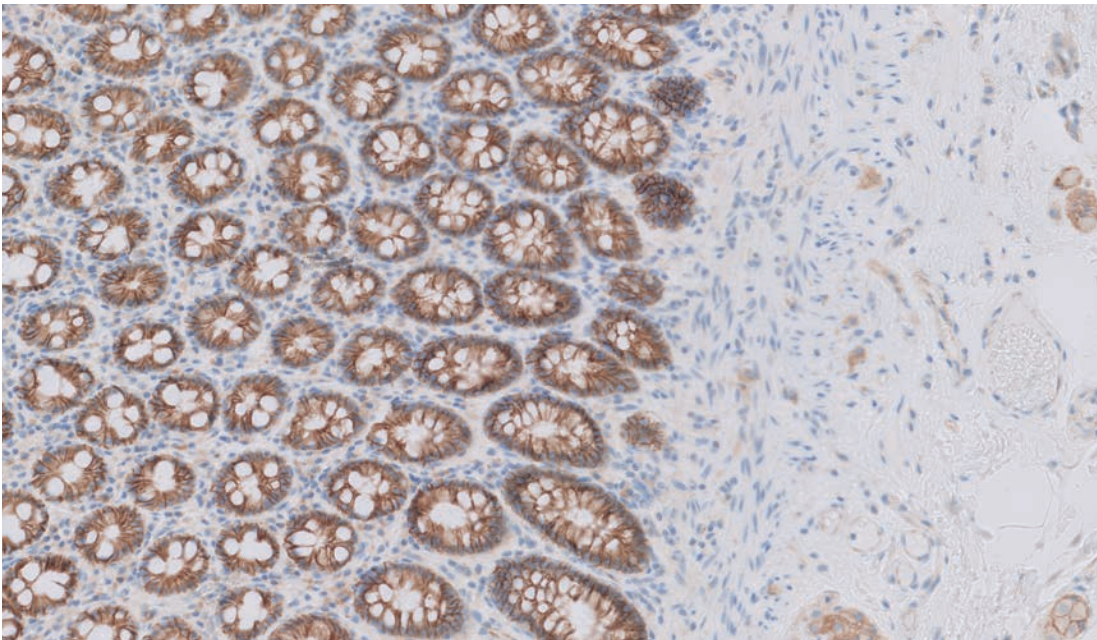


Tonsil (20x)

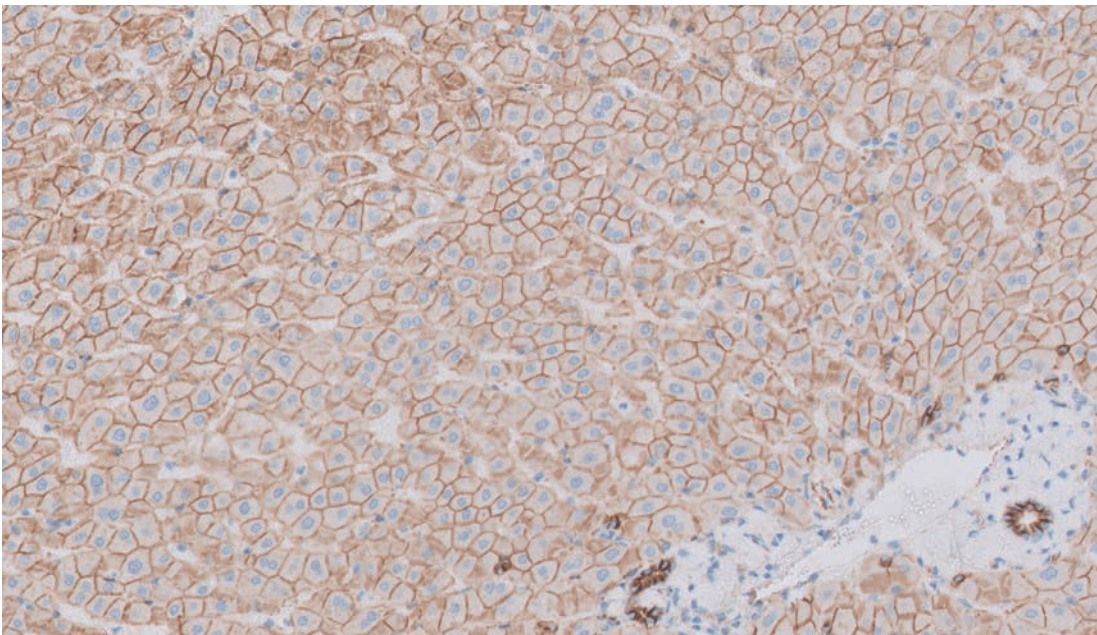
**Antibody:** Monoclonal Mouse Anti-Human  
**Clone:** **Beta-Catenin**  
**Code:**  $\beta$ -Catenin-1  
 GA702 | IR702

Reaction Location	Membrane	
Quality Control	Colon/Appendix	Liver
High Expression	Epithelial cells show a moderate to strong staining reaction.	Epithelial cells of bile ducts show a moderate to strong staining reaction.
Low Expression	NA	Hepatocytes show a weak to moderate staining reaction.
Non-expression	NA	NA

Note: A weak cytoplasmic reaction is accepted.



Colon (10x)

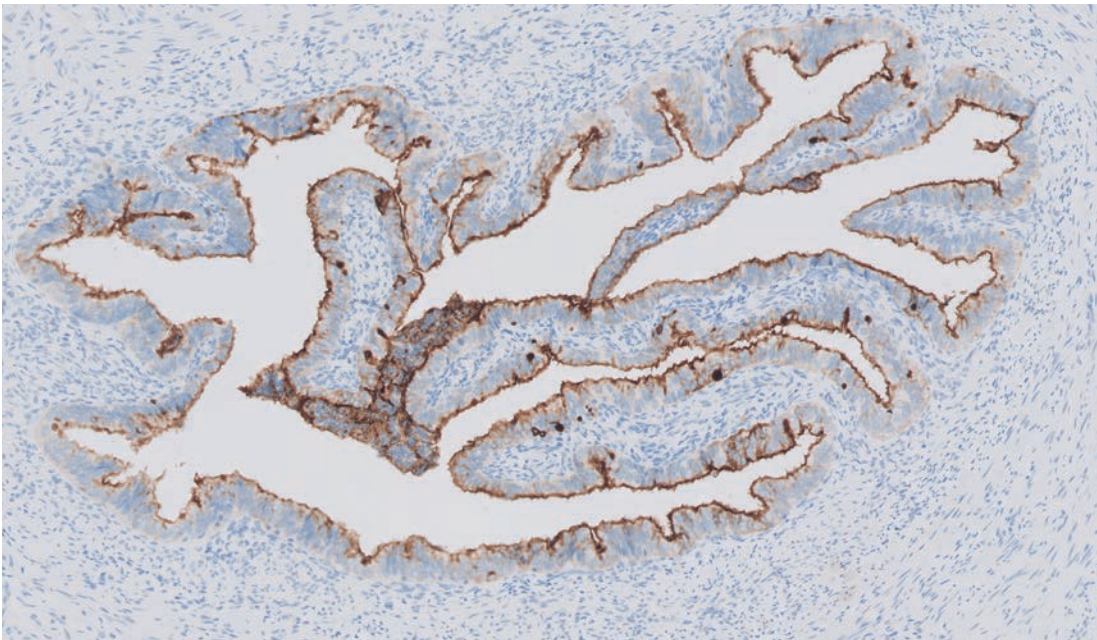


Liver (20x)

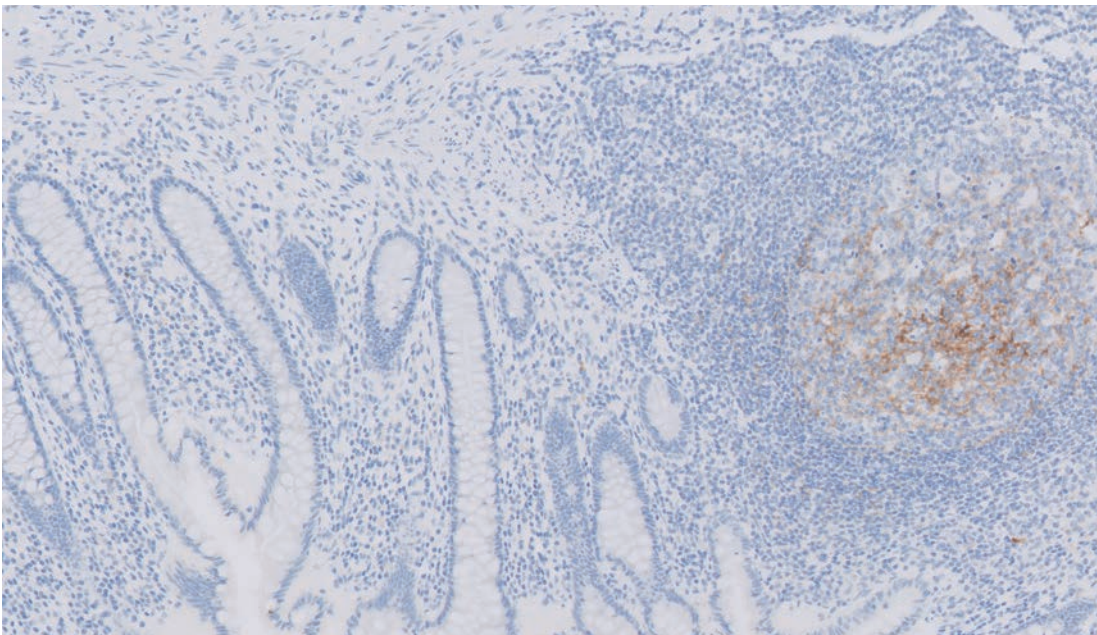
**Antibody:** Monoclonal Mouse Anti-Human  
**Clone:** CA 125  
**Code:** M11  
 GA701 | IR701

Reaction Location	Membrane and cytoplasm	
Quality Control	Fallopian tube	Appendix
High Expression	The apical brush border of the epithelial cells show a moderate to strong staining reaction.	NA
Low Expression	NA	Follicular dendritic cells in germinal centers of Peyer's patches show a weak to moderate staining reaction.
Non-expression	NA	Epithelial cells.

Note: Scattered epithelial cells in fallopian tube also show a cytoplasmic reaction.



Fallopian tube (10x)

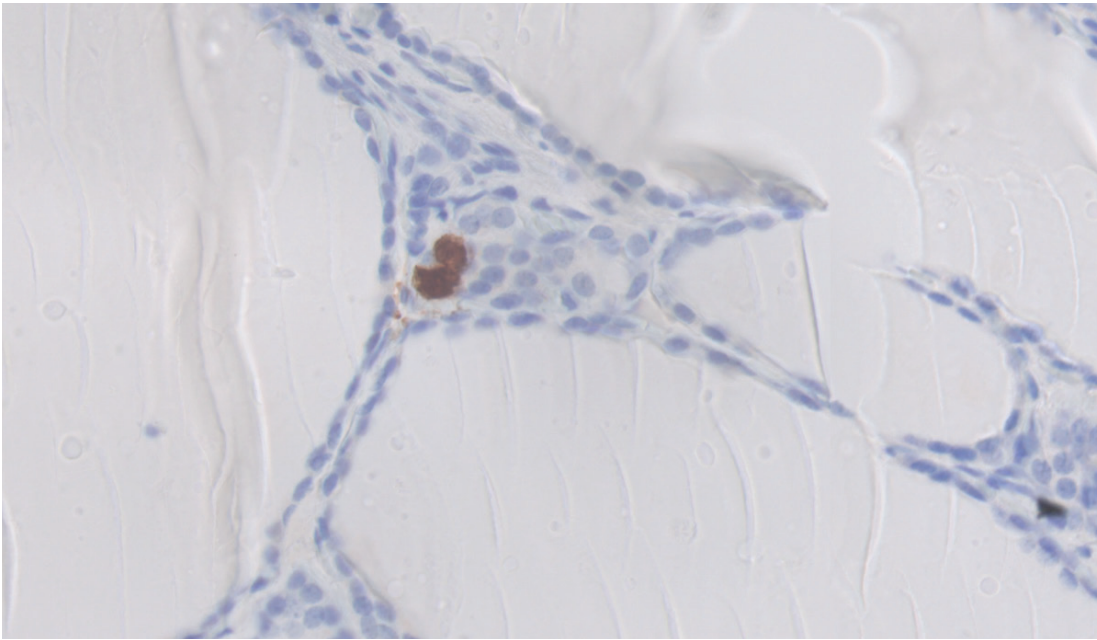


Appendix (10x)

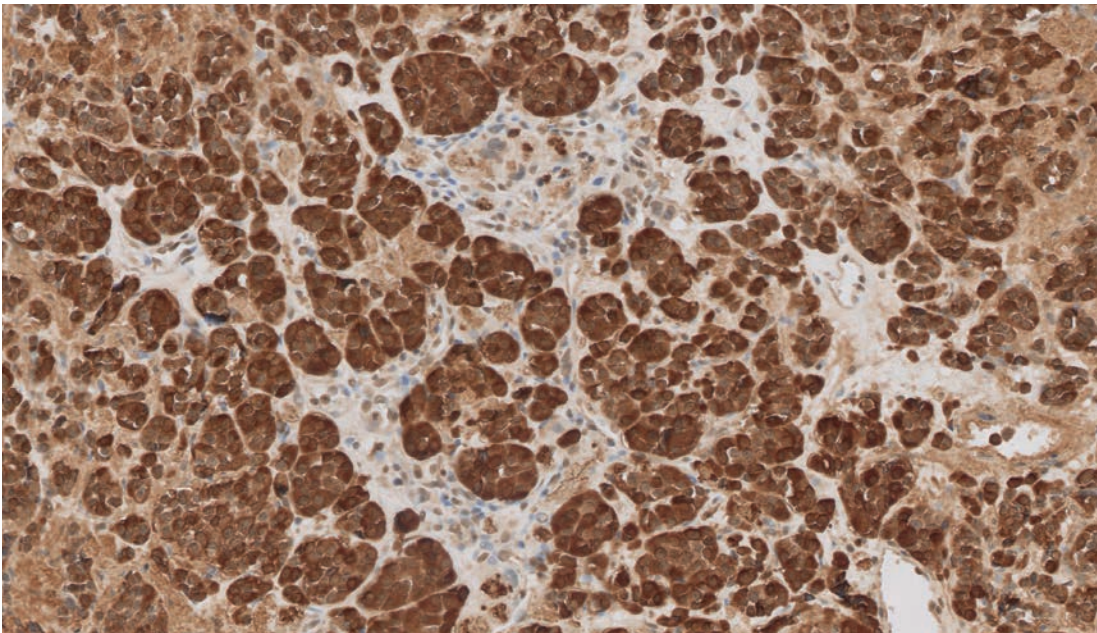
**Antibody:** Polyclonal Rabbit Anti-Human  
**Clone:** Calcitonin  
**Code:** Polyclonal  
 GA515 | IR515

Reaction Location	Cytoplasm	
Quality Control	Thyroid	Medullary thyroid carcinoma
High Expression	Scattered parafollicular C cells show a moderate to strong staining reaction.	Parafollicular C cells show a moderate to strong staining reaction.
Low Expression	NA	NA
Non-expression	NA	NA

Note: It is suggested to include a medullary thyroid carcinoma as control.



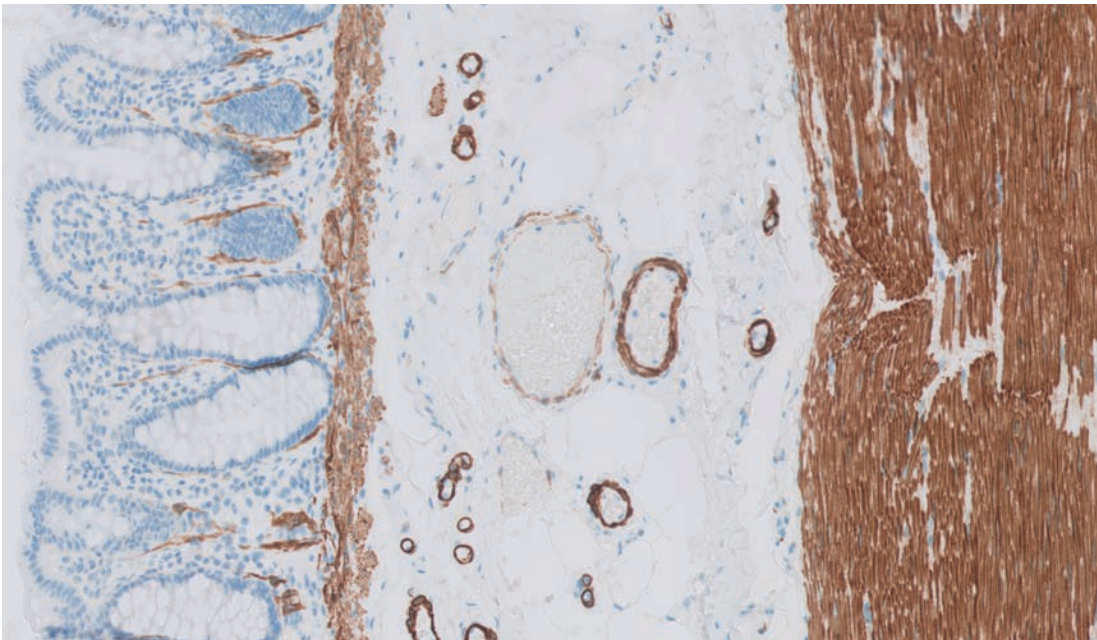
Thyroid (20x)



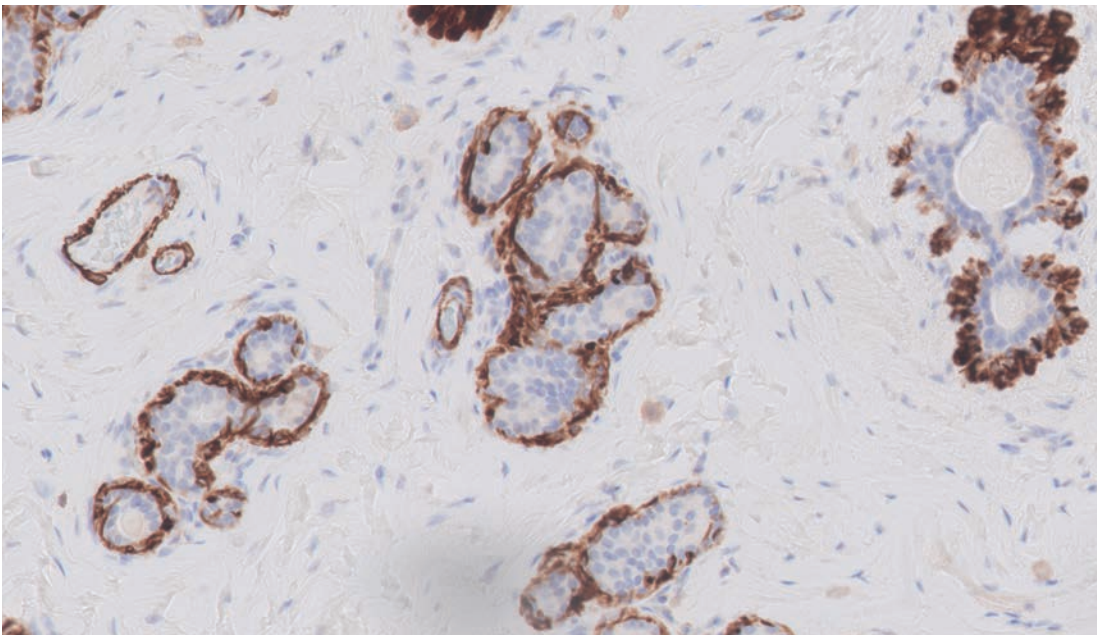
Medullary thyroid carcinoma (20x)

**Antibody:** Monoclonal Mouse Anti-Human  
**Clone:** Caldesmon  
**Code:** h-CD  
 GA054 | IR054

Reaction Location	Cytoplasm	
Quality Control	Colon/Appendix	Breast or breast hyperplasia
High Expression	Smooth muscle cells in the tunica muscularis show a moderate to strong staining reaction.	Myoepithelial cells around the ducts show a moderate to strong staining reaction. Muscle cells in blood vessels show a strong staining reaction.
Low Expression	NA	NA
Non-expression	Epithelial cells.	Epithelial cells.



Colon (10x)

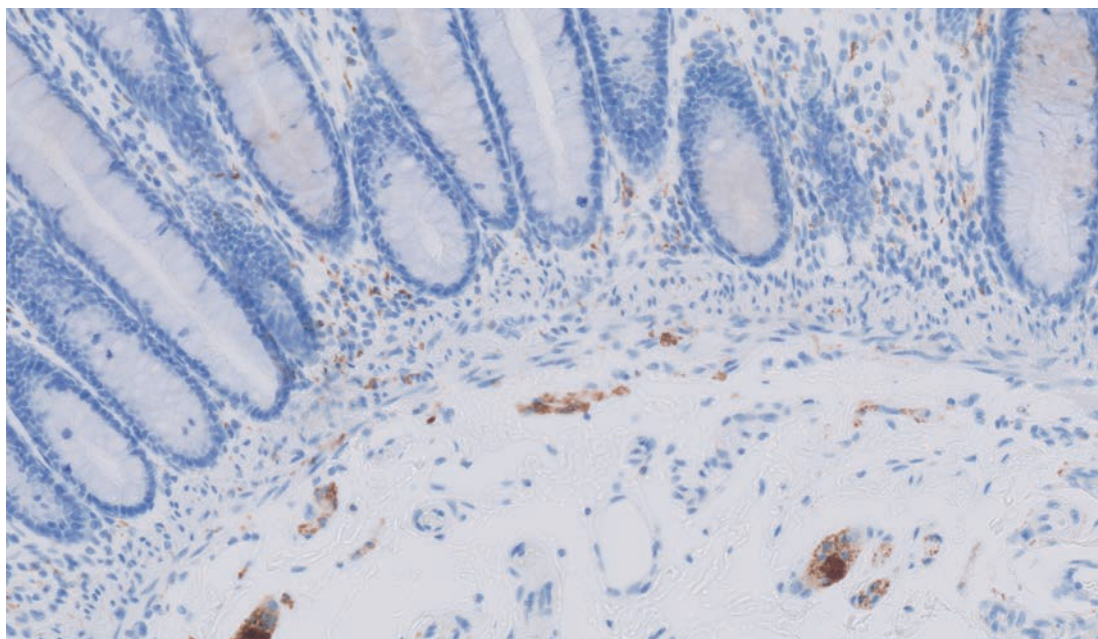


Breast (20x)

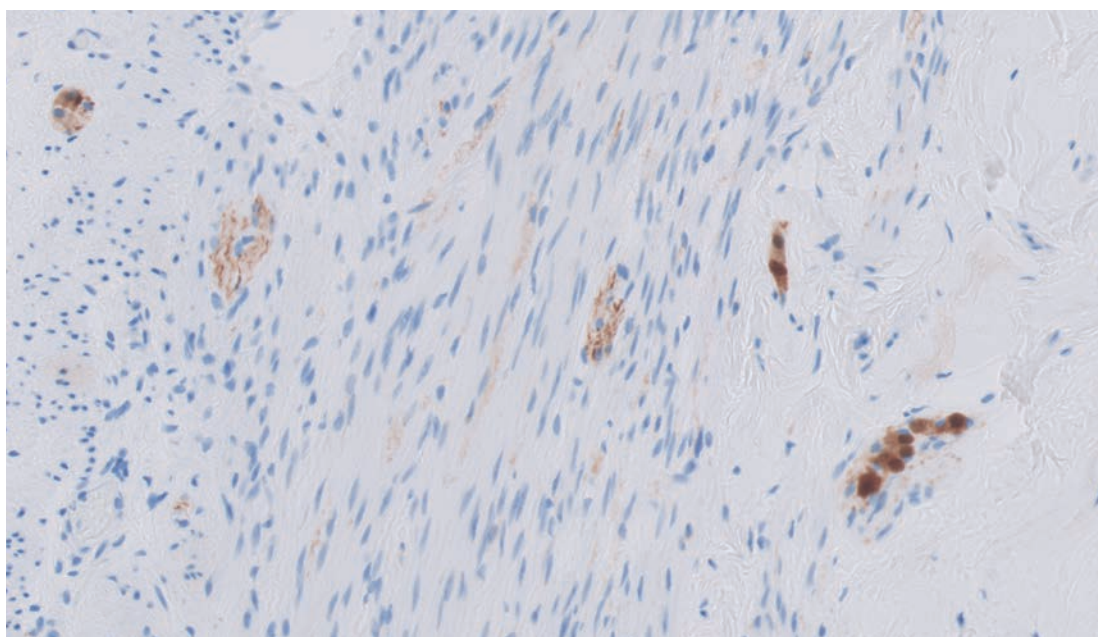
**Antibody:** Monoclonal Mouse Anti-Human  
**Clone:** Calretinin  
**Code:** DAK-Calret 1  
 IR627

Reaction Location	Nucleus and cytoplasm
Quality Control	Colon/Appendix
High Expression	Ganglion cells of the peripheral nerves show a moderate to strong staining reaction.
Low Expression	Axons of the peripheral nerves show a weak to moderate staining reaction.
Non-expression	Epithelial cells.

Note: Peripheral macrophages in colon should also show a nuclear and cytoplasmic staining reaction.



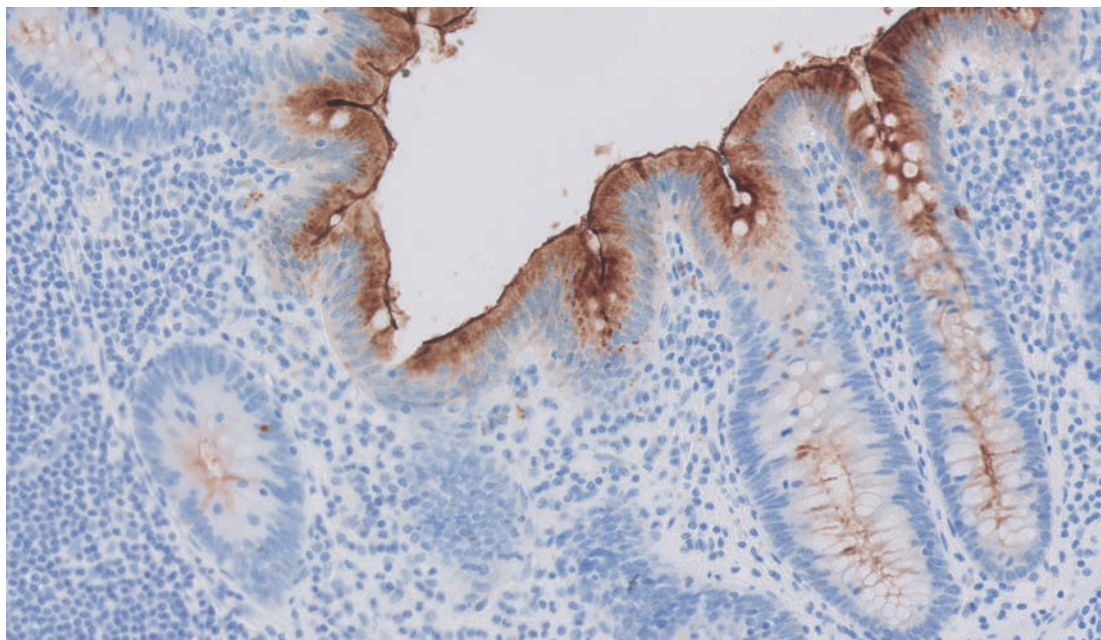
Colon (20x)



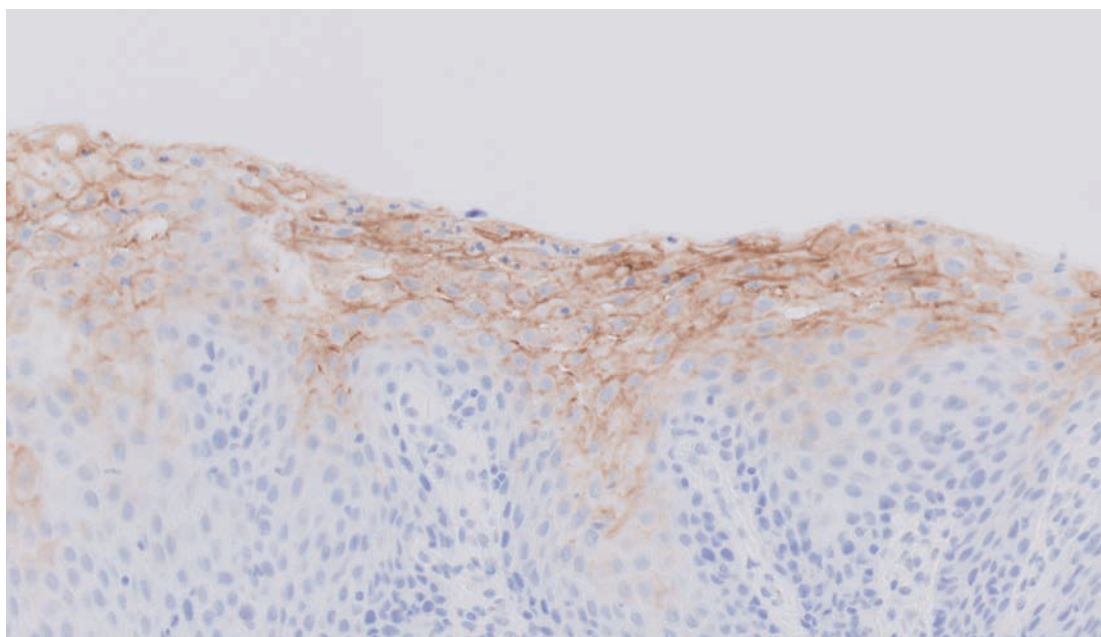
Appendix (20x)

**Antibody:** Monoclonal Mouse Anti-Human  
**Clone:** Carcinoembryonic Antigen  
**Code:** II-7  
 GA622 | IR622

Reaction Location	Membrane and cytoplasm	
Quality Control	Colon/Appendix	Tonsil
High Expression	Epithelial cells of the colon mucosa show a moderate to strong staining reaction at the luminal surface with enhancement of the glycocalyx.	NA
Low Expression	NA	Squamous epithelial cells show focally a weak to moderate cytoplasmic staining reaction.
Non-expression	NA	NA



Appendix (20x)



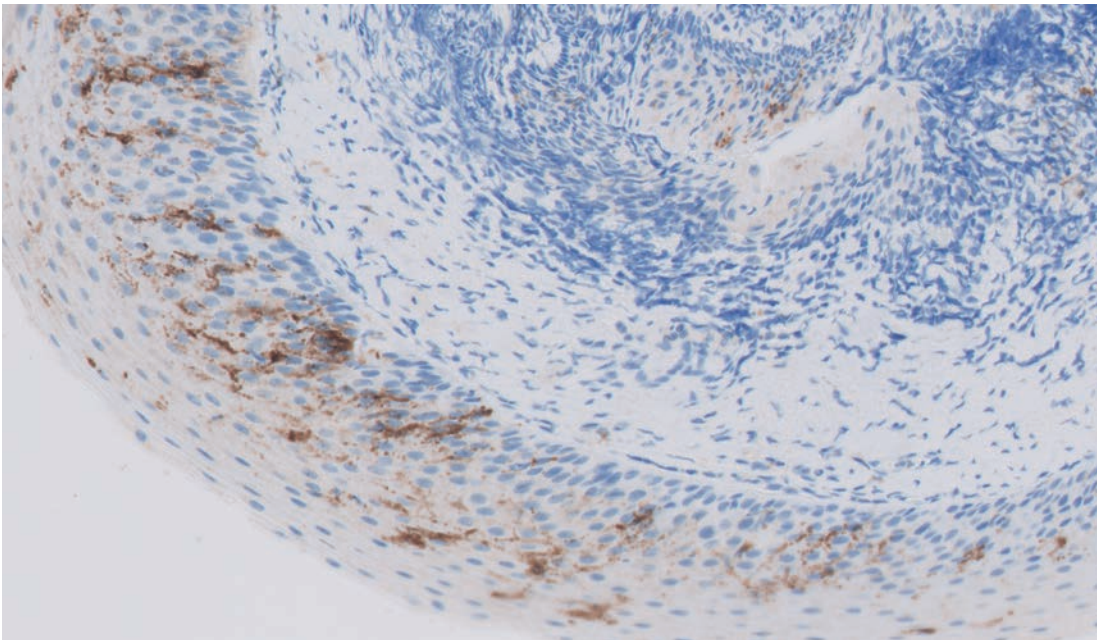
Tonsil (20x)



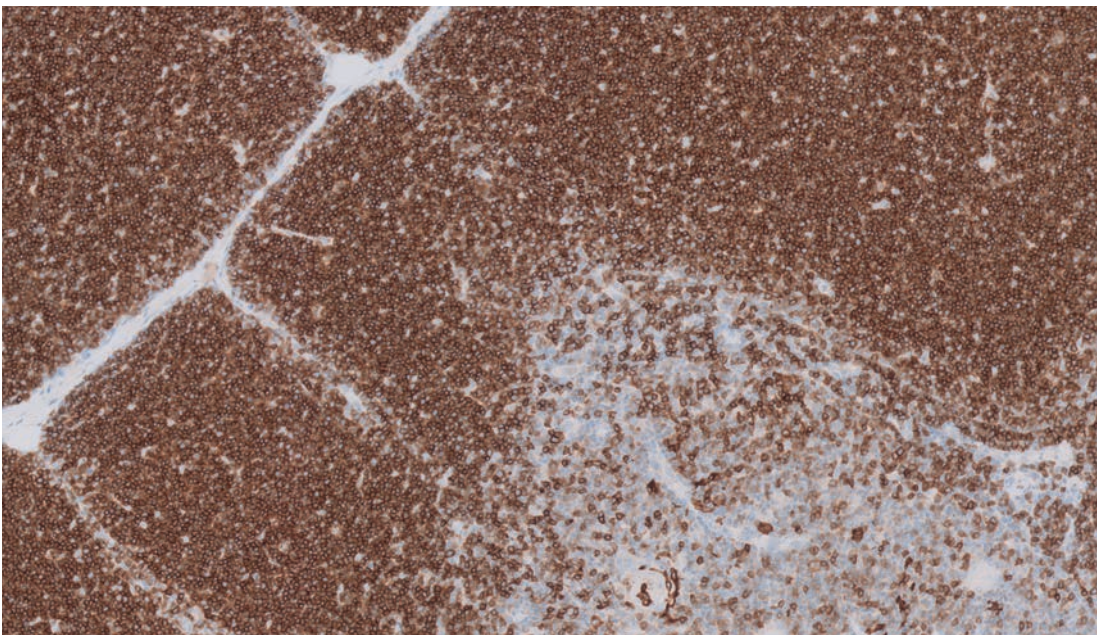
**Antibody:** Monoclonal Mouse Anti-Human CD1a  
**Clone:** 010  
**Code:** IR069

Reaction Location	Membrane and/or cytoplasm	
Quality Control	Tonsil	Thymus
High Expression	The Langerhans' cells in the squamous epithelium show a moderate to strong granulated staining reaction.	The cortical thymocytes show a moderate to strong predominantly membranous staining reaction.
Low Expression	NA	NA
Non-expression	Epithelial cells.	NA

Note: Staining in germinal center should be disregarded. Staining of smooth muscle cells may be observed.



Tonsil (20x)

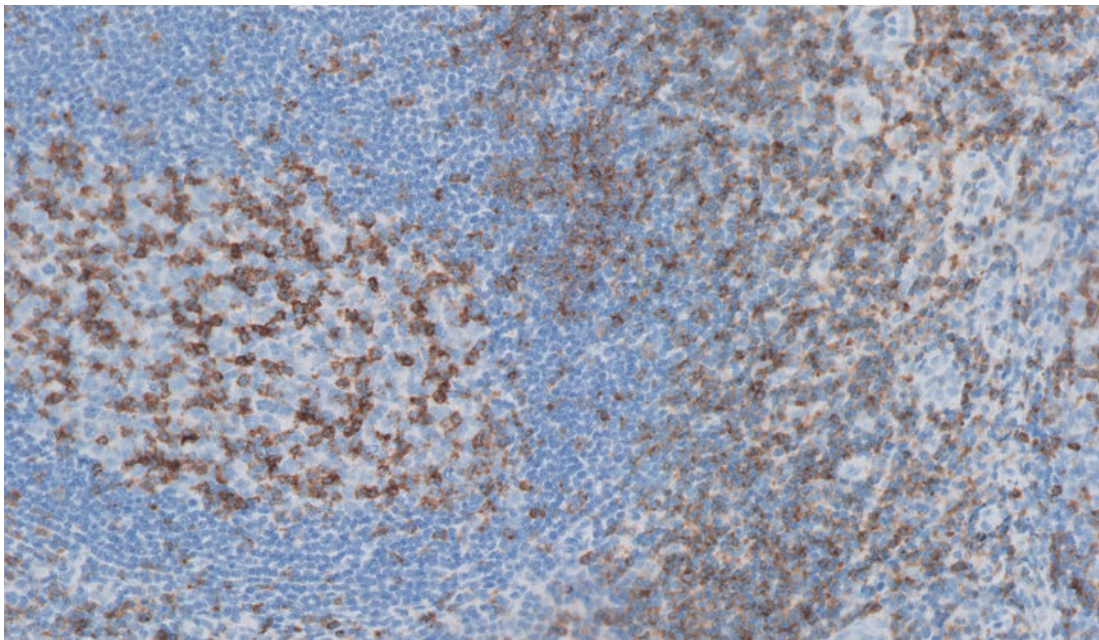


Thymus (10x)

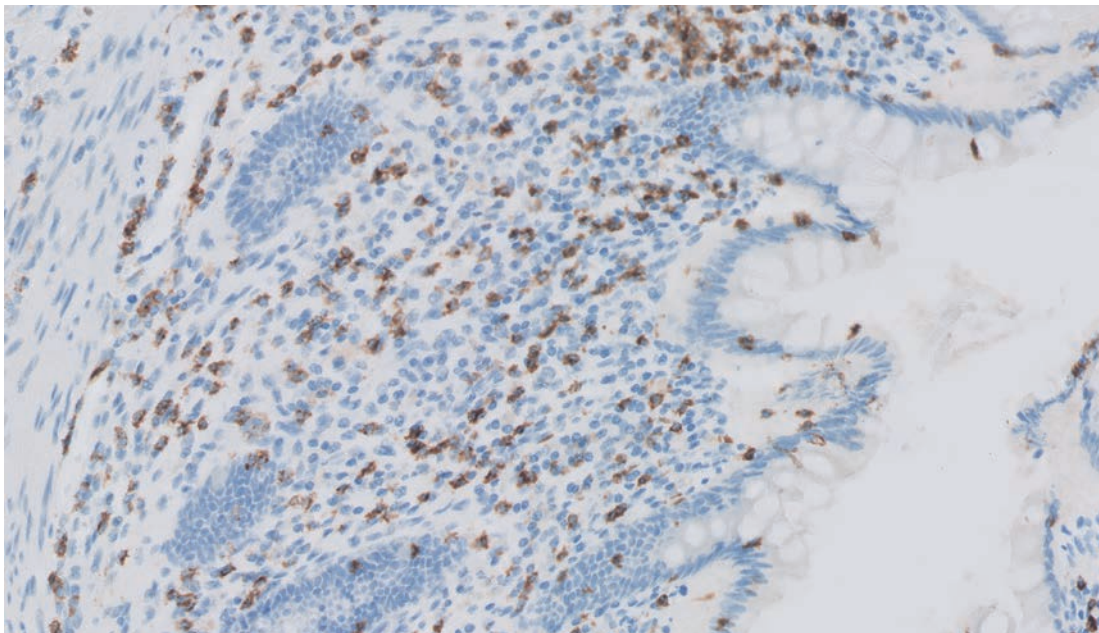
**Antibody:** Monoclonal Mouse Anti-Human CD2  
**Clone:** AB75  
**Code:** GA651 | IR651

Reaction Location		Membrane and cytoplasm	
Quality Control	Tonsil		Colon/Appendix
High Expression	Isolated T cells in the germinal centers show a strong staining reaction whereas T cells in the T zone show a moderate to strong staining reaction.		Intra-epithelial T cells show a weak to strong staining reaction.
Low Expression	NA		Intra-epithelial T cells show at least a weak to moderate staining reaction.
Non-expression	Epithelial cells.		NA

Note: Tonsil: Virtually all T cells and NK cells should show a predominantly membranous and cytoplasmic staining reaction.



Tonsil (20x)



Appendix (20x)

Antibody:

Polyclonal Rabbit Anti-Human

CD3

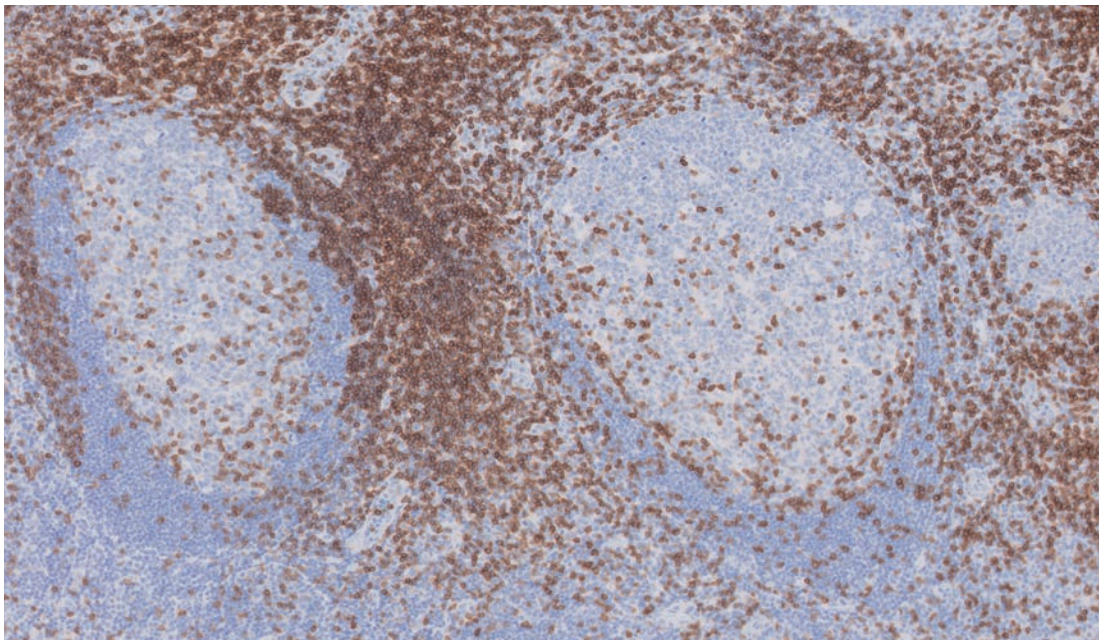
Clone:

Polyclonal

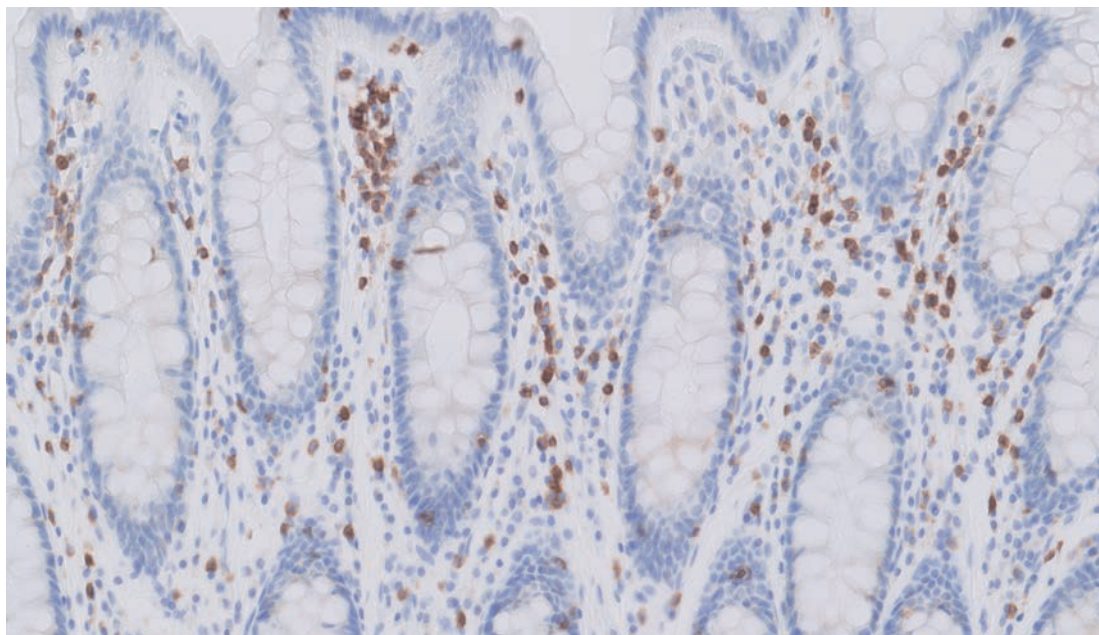
Code:

GA503 | IR503

Reaction Location		Membrane and/or cytoplasm	
Quality Control	Tonsil	Colon/Appendix	
High Expression	T cells in the interfollicular areas and in the germinal centers show a moderate to strong staining reaction.	Intra-epithelial T cells show a weak to strong staining reaction.	
Low Expression	NA	Intra-epithelial T cells show at least a weak to moderate staining reaction.	
Non-expression	B cells.	NA	



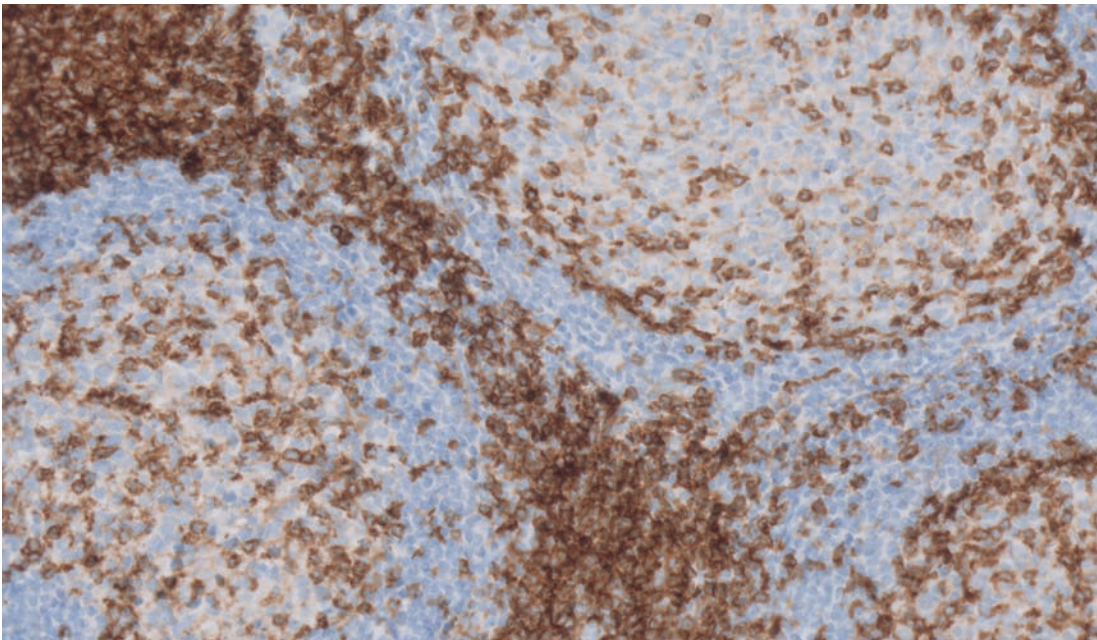
Tonsil (10x)



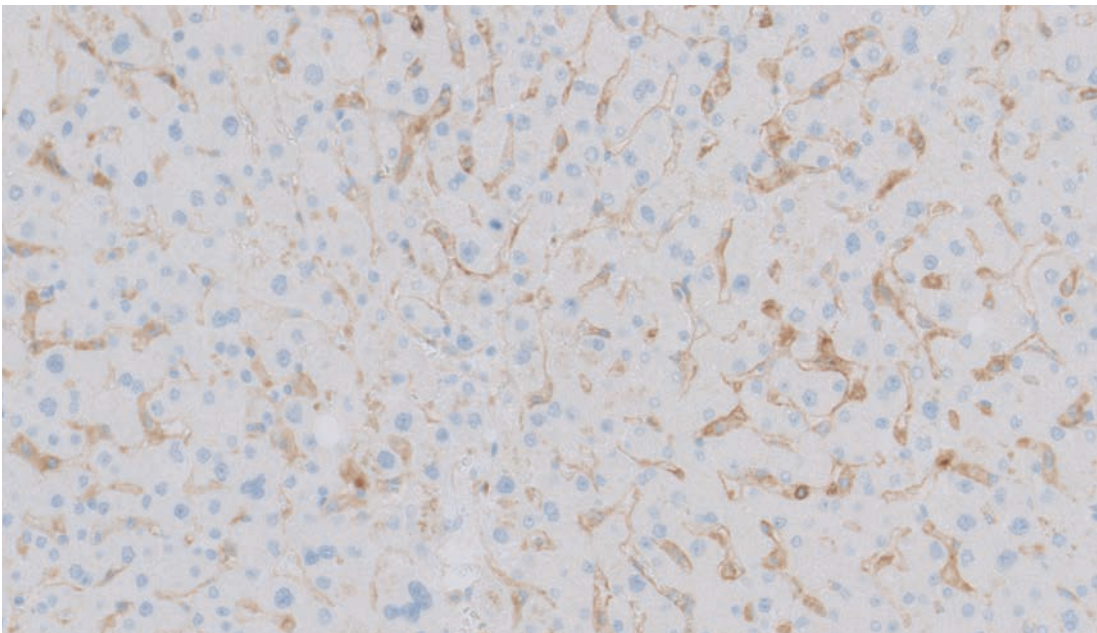
Colon (20x)

**Antibody:** Monoclonal Mouse Anti-Human CD4  
**Clone:** 4B12  
**Code:** IR649

Reaction Location	Membrane	
Quality Control	Tonsil	Liver
High Expression	Crowded and isolated T-helper cells show a moderate to strong staining reaction.	NA
Low Expression	Germinal center macrophages show a weak to moderate staining reaction.	Kupffer and endothelial cells of the sinusoids show a weak to moderate staining reaction.
Non-expression	NA	Hepatocytes



Tonsil (20x)

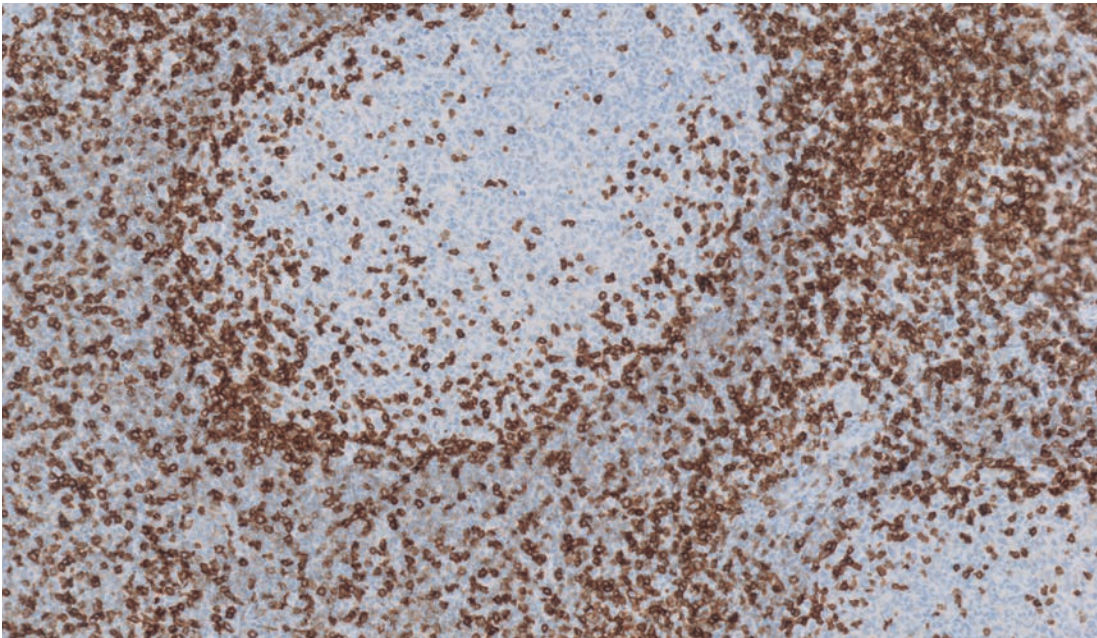


Liver (20x)

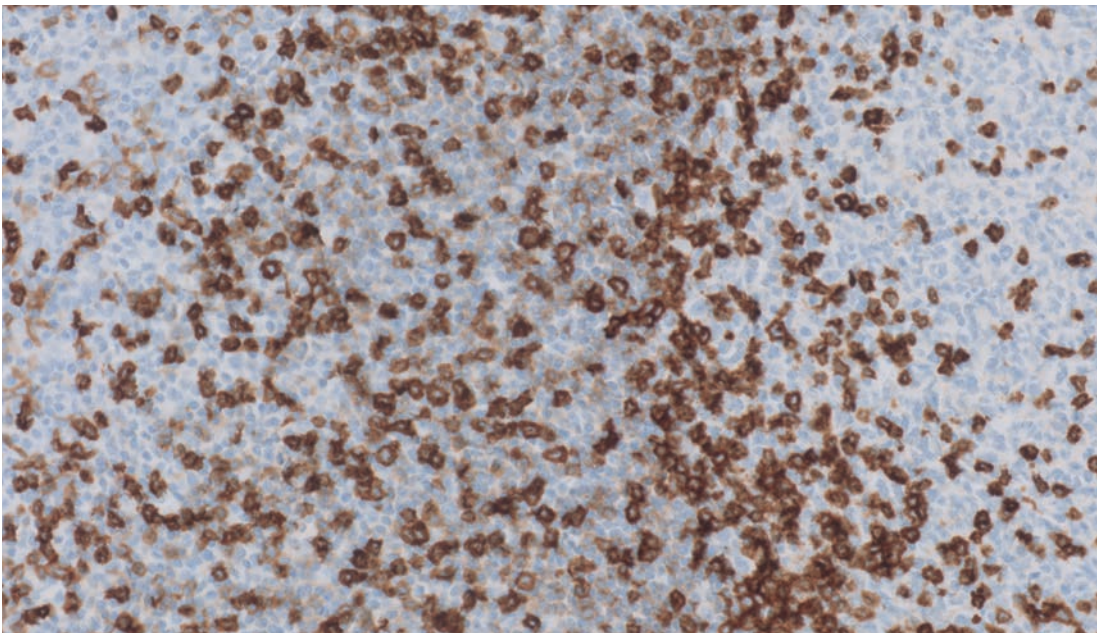
**Antibody:** Monoclonal Mouse Anti-Human  
**Clone:** CD5  
**Code:** 4C7  
 IR082

Reaction Location	Membrane and/or cytoplasm
Quality Control	Tonsil
High Expression	Virtually all T cells show a moderate to strong staining reaction. Both crowded T cells in the T zone and scattered T cells in the germinal center are demonstrated and show a distinct continuous membranous staining reaction.
Low Expression	In the mantle zone, scattered B cells show a weak membranous staining reaction.
Non-expression	NA

Note: Occasionally, it can be difficult to distinguish the two different lymphocytic subtypes.



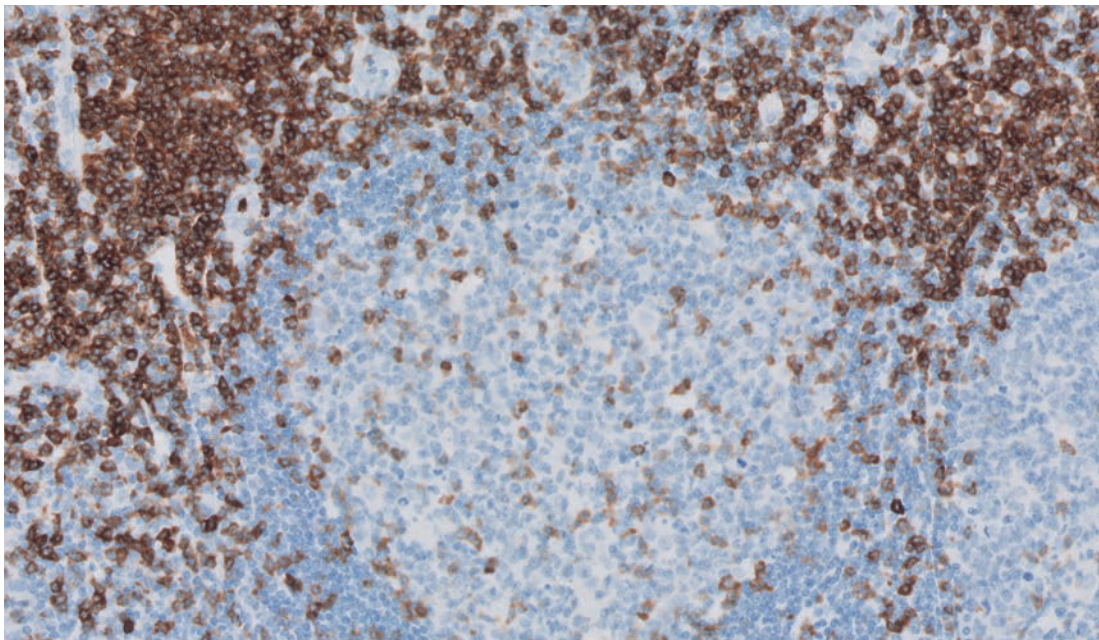
Tonsil (10x)



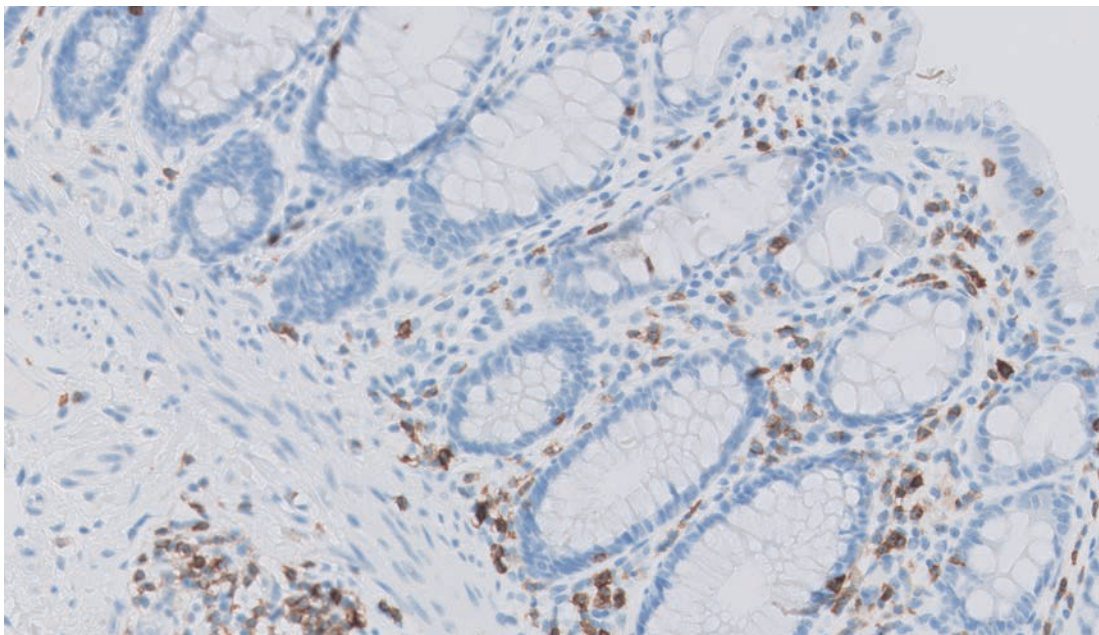
Tonsil (20x)

**Antibody:** Monoclonal Mouse Anti-Human CD7  
**Clone:** CBC.37  
**Code:** GA643 | IR643

Reaction Location	Membrane	
Quality Control	Tonsil	Colon/Appendix
High Expression	Crowded T cells in the T zone show a strong staining reaction.	Intra-epithelial T cells show a weak to strong distinct staining reaction.
Low Expression	Isolated T cells show a weak to strong staining reaction.	Intra-epithelial T cells show at least a weak to moderate distinct staining reaction.
Non-expression	NA	Epithelial cells.



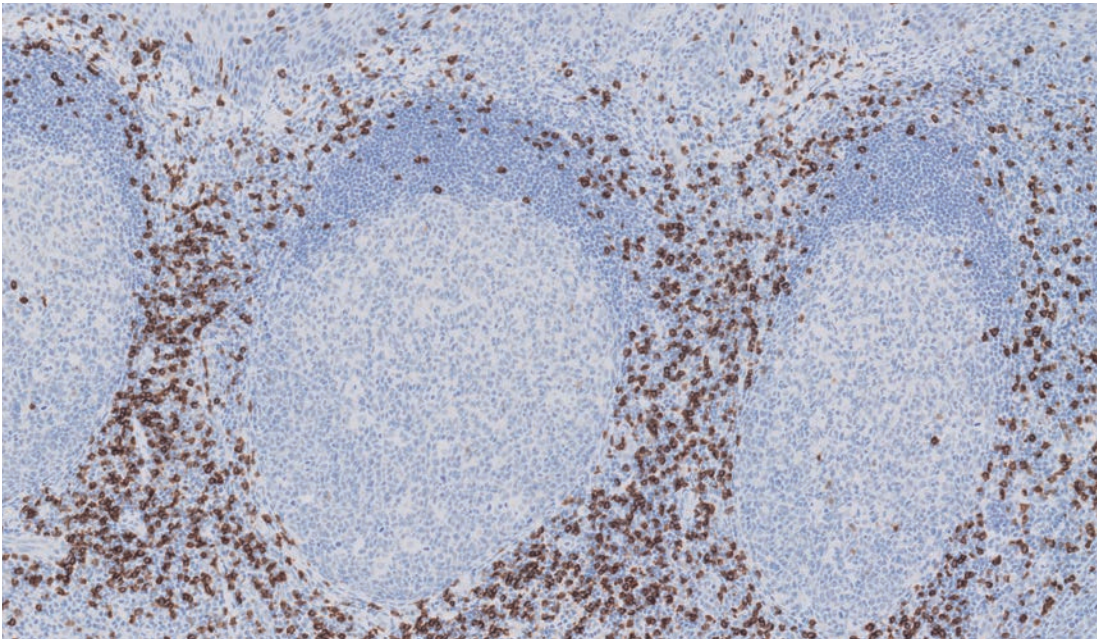
Tonsil (20x)



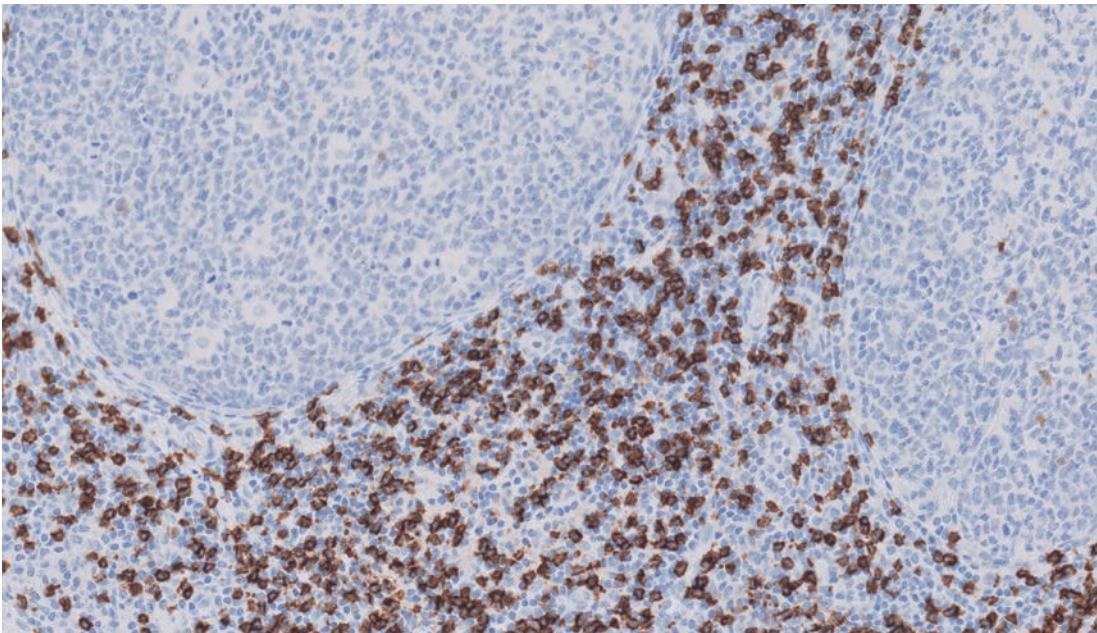
Colon (20x)

Antibody: Monoclonal Mouse Anti-Human  
CD8  
Clone: C8/144B  
Code: GA623 | IR623

Reaction Location	Membrane and cytoplasm
Quality Control	Tonsil
High Expression	Interfollicular T cells show a moderate to strong staining reaction.
Low Expression	NA
Non-expression	NA



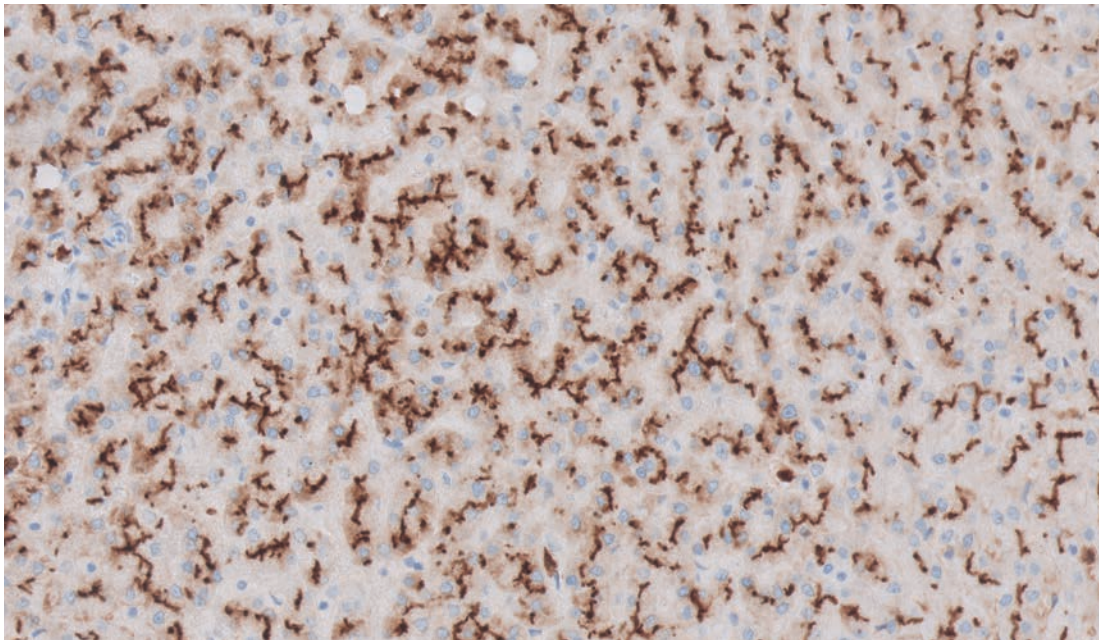
Tonsil (10x)



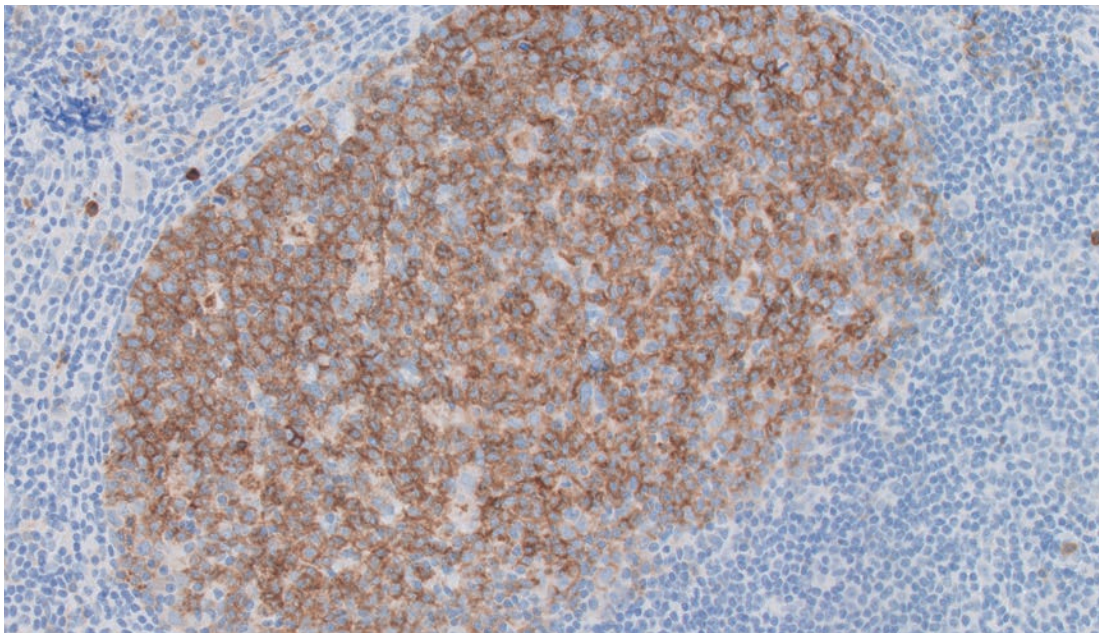
Tonsil (20x)

**Antibody:** Monoclonal Mouse Anti-Human CD10  
**Clone:** 56C6  
**Code:** GA648 | IR648

Reaction Location	Membrane	
Quality Control	Liver	Tonsil
High Expression	Bile canaliculi show a moderate to strong staining reaction.	NA
Low Expression	NA	Germinal center B cells show a weak to moderate staining reaction.
Non-expression	NA	Peripheral lymphocytes.



Liver (20x)

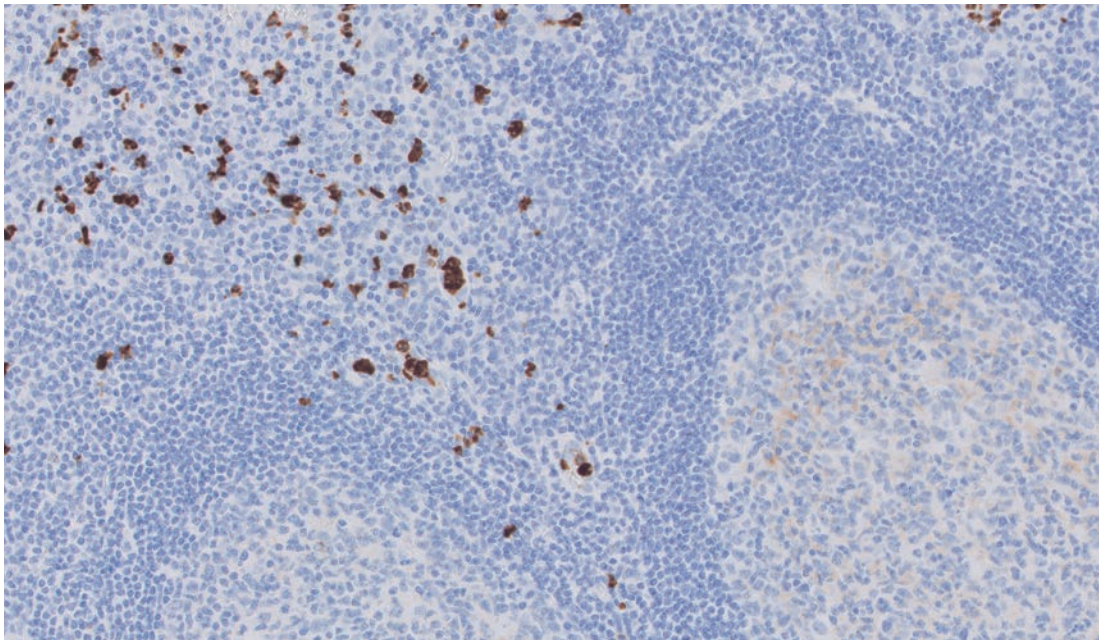


Tonsil (20x)

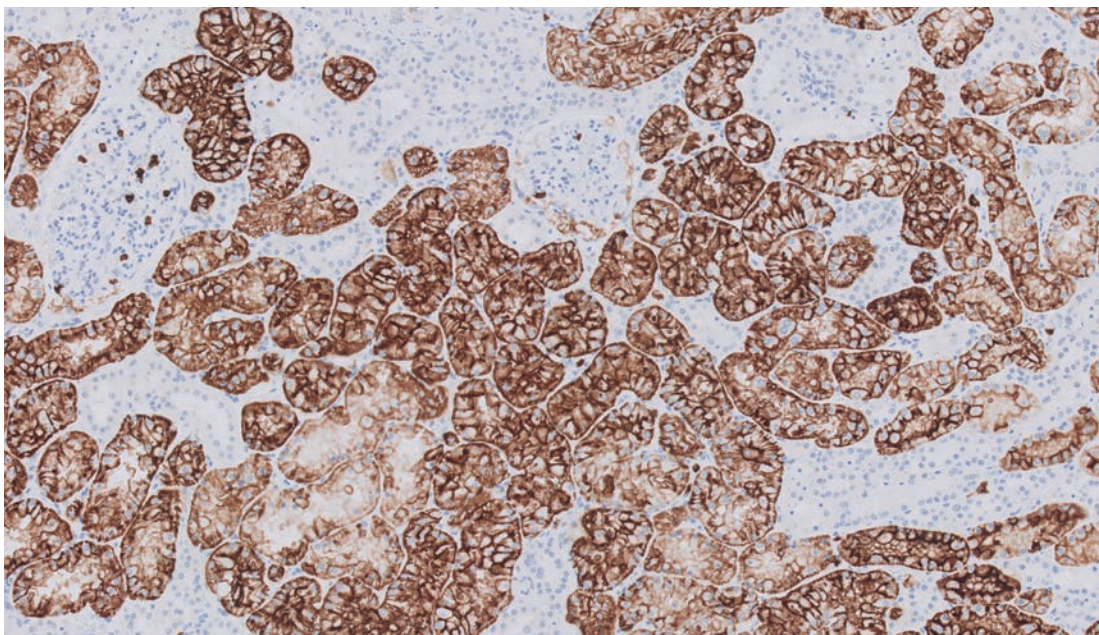


**Antibody:** Monoclonal Mouse Anti-Human  
**Clone:** CD15  
**Code:** Carb-3  
 GA062 | IR062

Reaction Location	Membrane and/or cytoplasm	
Quality Control	Tonsil	Kidney
High Expression	Neutrophils and eosinophiles show a moderate to strong staining reaction.	Proximal and distal tubules show a weak to strong staining reaction.
Low Expression	NA	Proximal and distal tubules show a weak to strong staining reaction.
Non-expression	All other cell types including B and T cells.	NA



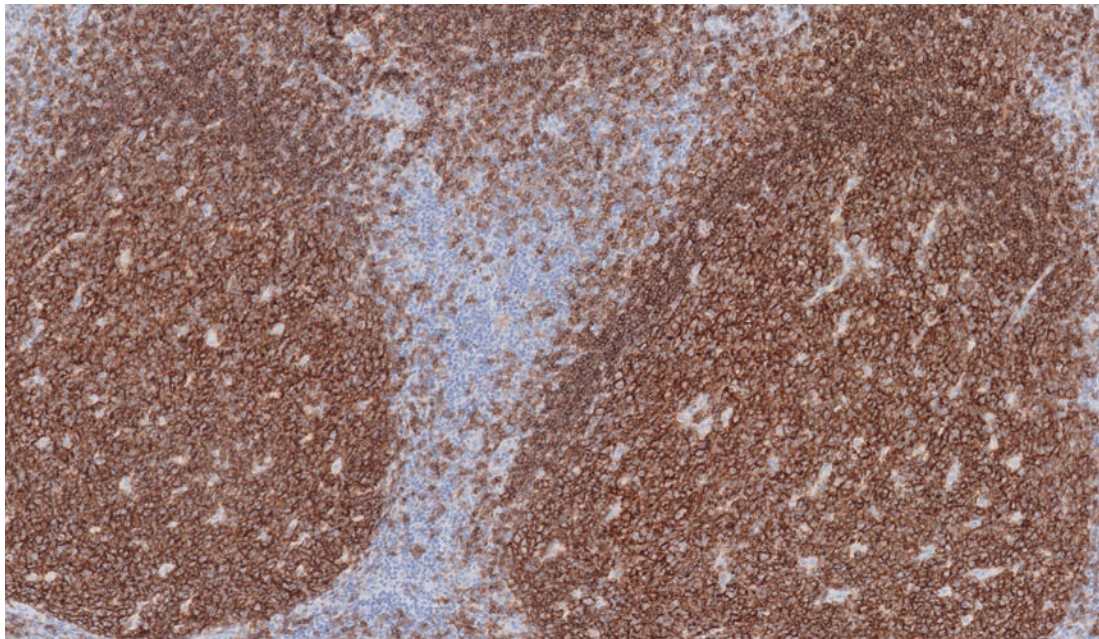
Tonsil (20x)



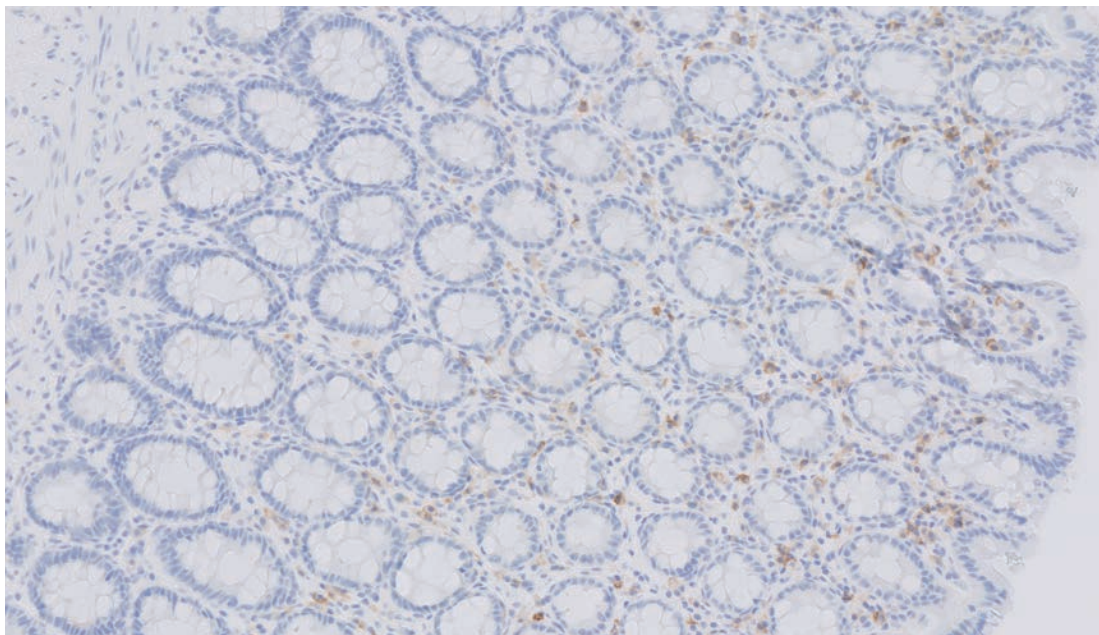
Kidney (10x)

**Antibody:** Monoclonal Mouse Anti-Human CD19  
**Clone:** LE-CD19  
**Code:** GA656 | IR656

Reaction Location		
Membrane		
Quality Control	Tonsil	Colon/Appendix
High Expression	B cells in the germinal centers and mantle zone show a moderate to strong membrane staining reaction.	NA
Low Expression	NA	Plasma cells in the lamina propria show a weak to moderate staining reaction.
Non-expression	Epithelial cells.	NA



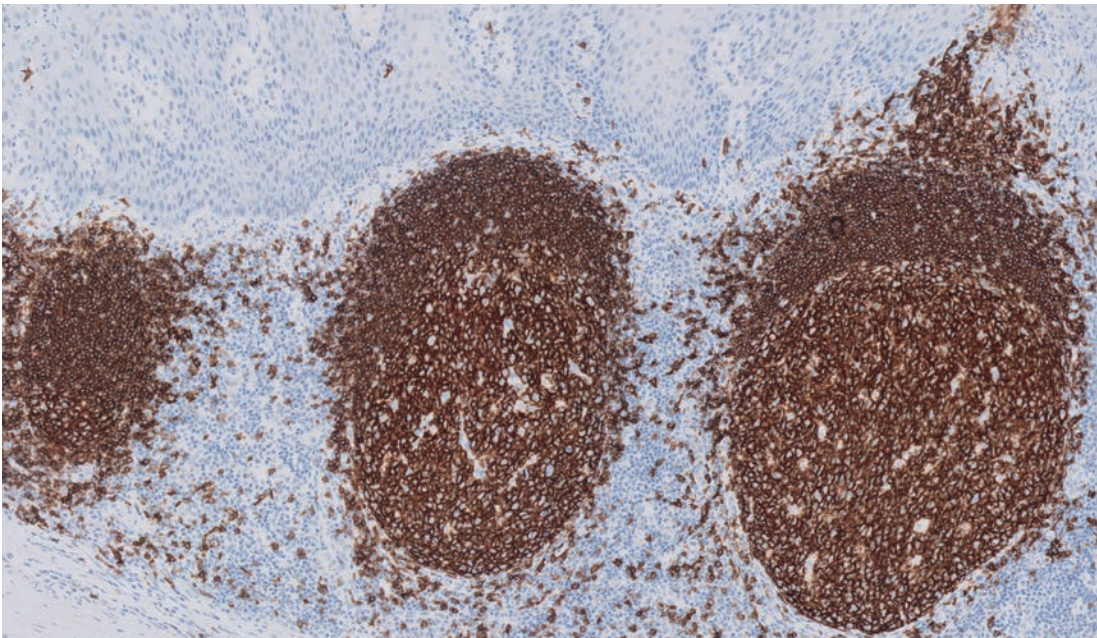
Tonsil (10x)



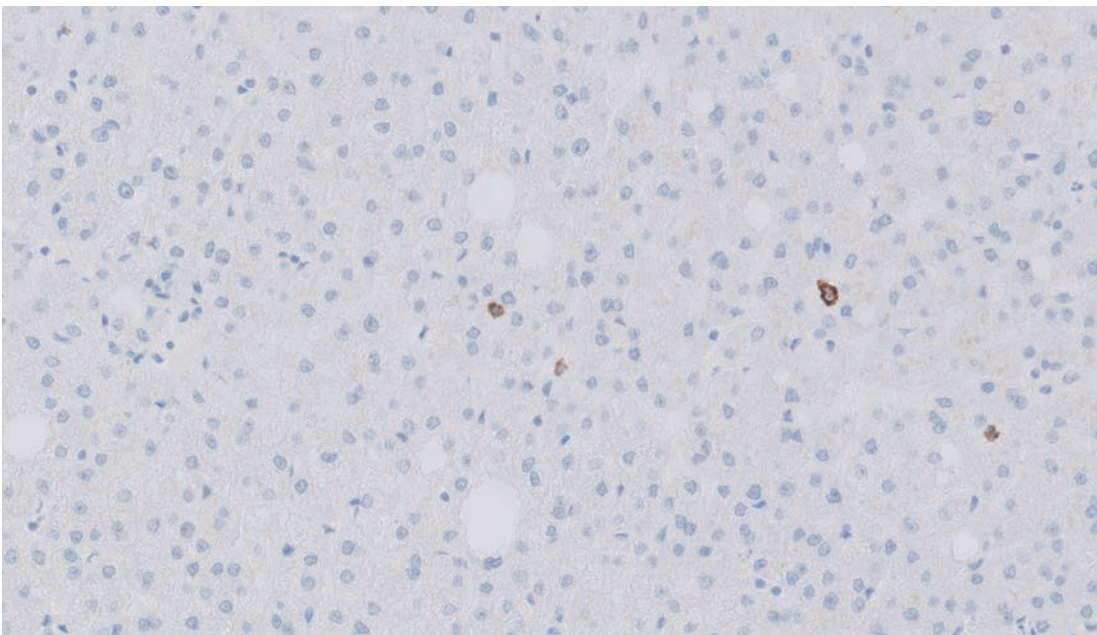
Colon (10x)

**Antibody:** Monoclonal Mouse Anti-Human CD20cy  
**Clone:** L26  
**Code:** GA604 | IR604

Reaction Location	Membrane	
Quality Control	Tonsil	Liver
High Expression	Mantle zone and germinal center B cells show a moderate to strong staining reaction.	NA
Low Expression	NA	Isolated B cells show a weak to moderate staining reaction.
Non-expression	Squamous epithelial cells.	NA



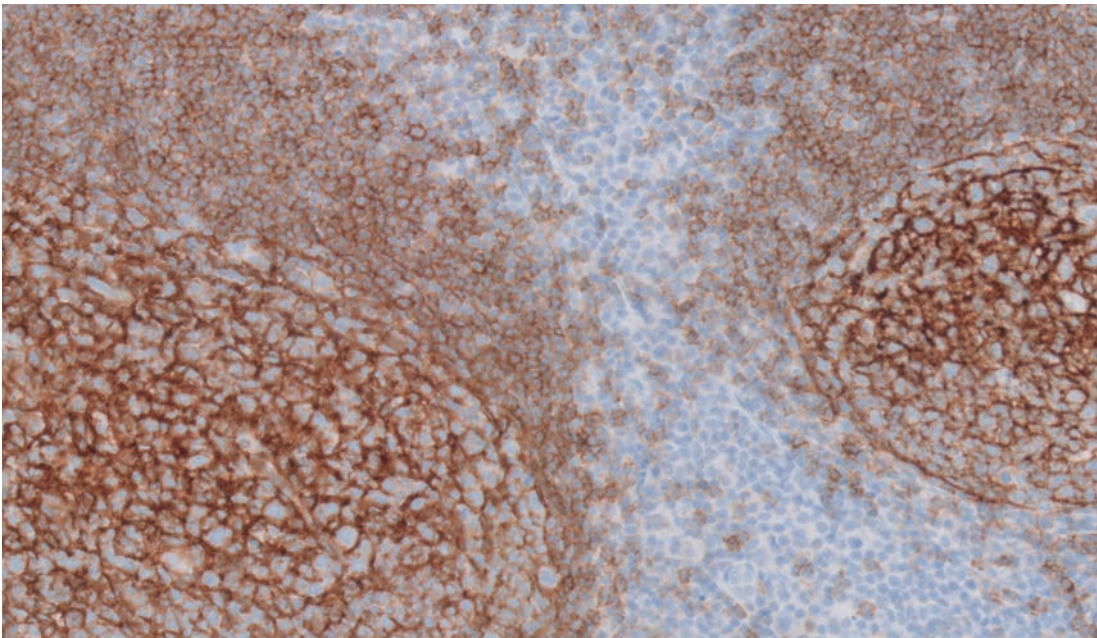
Tonsil (10x)



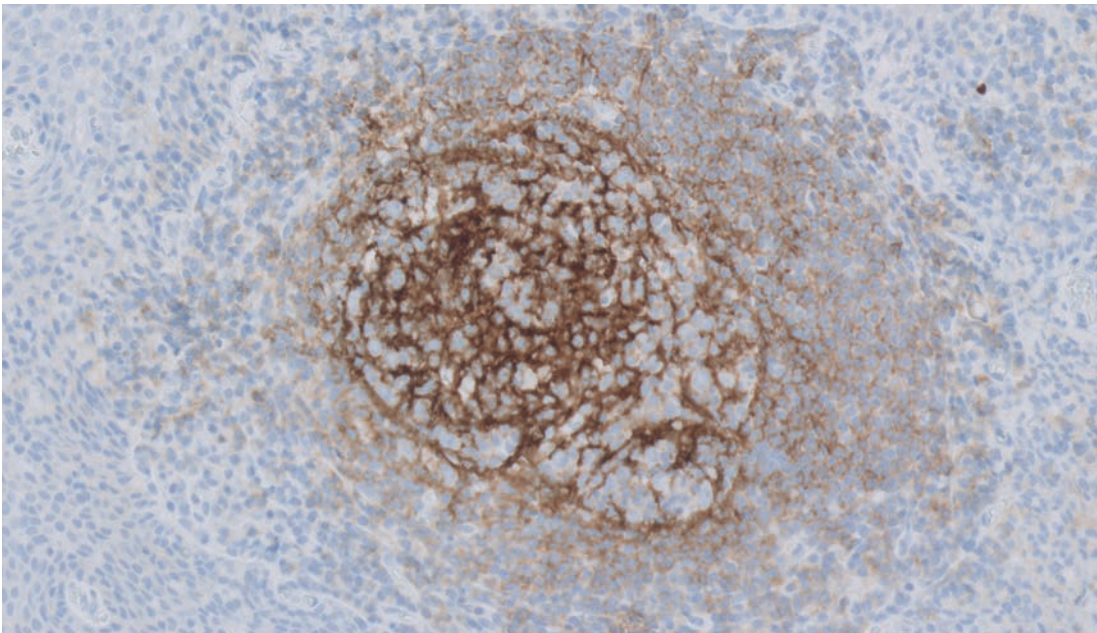
Liver (20x)

Antibody: Monoclonal Mouse Anti-Human  
CD21  
Clone: 1F8  
Code: IR608

Reaction Location	Membrane
Quality Control	Tonsil
High Expression	Follicular dendritic cells in the germinal centers of tonsil show a moderate to strong staining reaction.
Low Expression	A subset of activated B cells in the mantle zone show a weak to moderate staining reaction.
Non-expression	NA



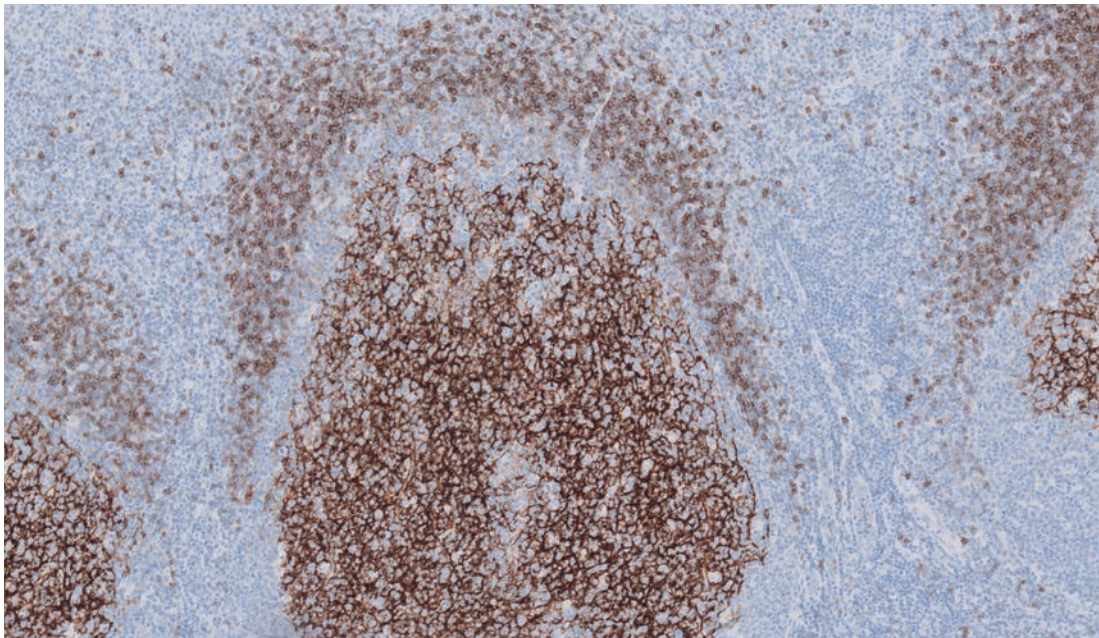
Tonsil (20x)



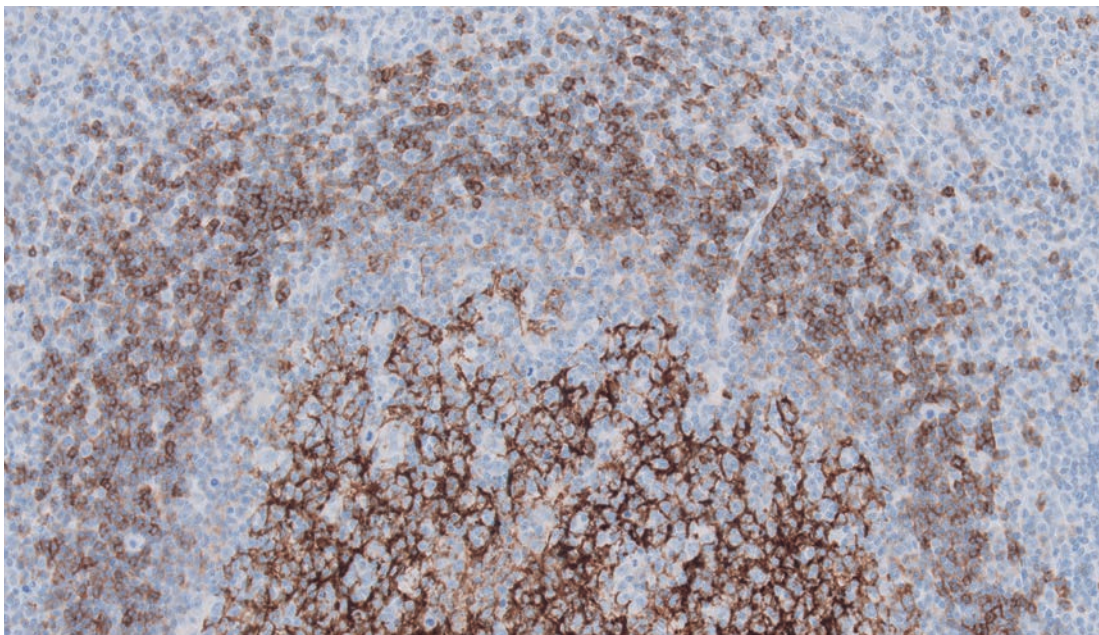
Tonsil (20x)

**Antibody:** Monoclonal Mouse Anti-Human  
**Clone:** CD23  
**Code:** DAK-CD23  
GA781 | IR781

Reaction Location	Membrane
Quality Control	Tonsil
High Expression	Follicular dendritic cells in the germinal centers show a moderate to strong staining reaction.
Low Expression	B cells in the mantle zone show a weak to moderate staining reaction.
Non-expression	Squamous epithelial cells and T cells in the interfollicular T zones.



Tonsil (10x)

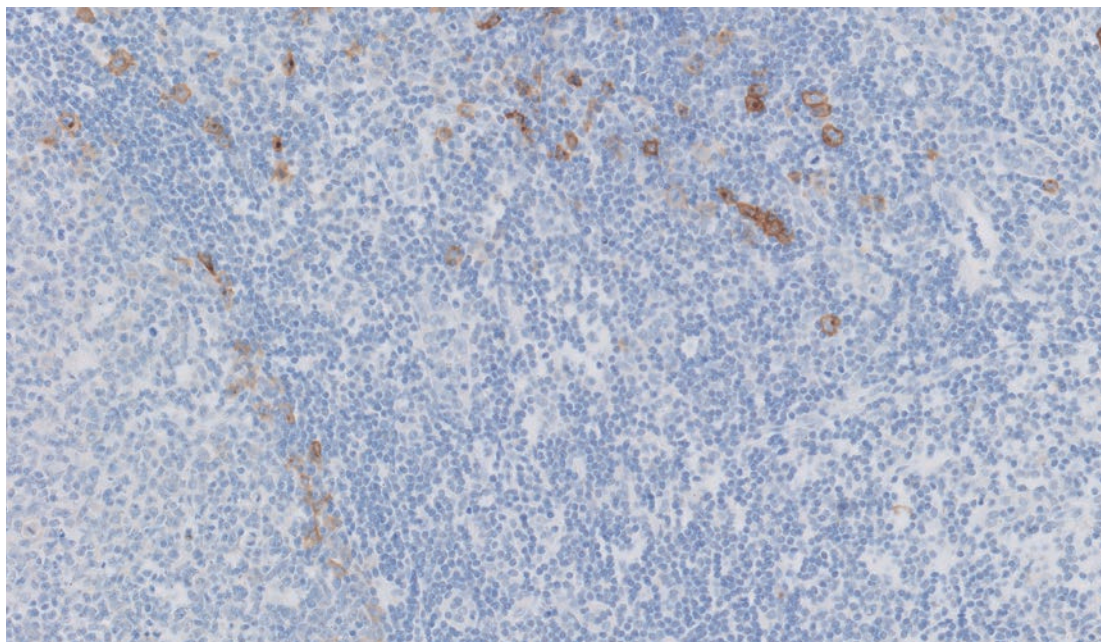


Tonsil (20x)

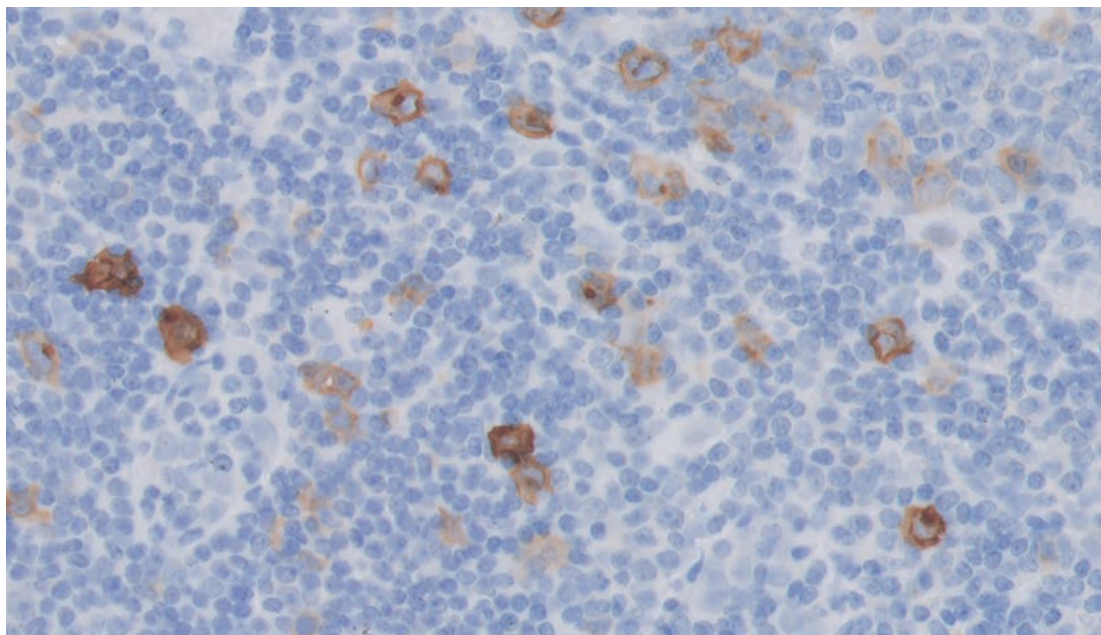
**Antibody:** Monoclonal Mouse Anti-Human CD30  
**Clone:** Ber-H2  
**Code:** GA602 | IR602

Reaction Location	Membrane and cytoplasm
Quality Control	Tonsil
High Expression	Activated inter and perifollicular lymphocytes show a weak to strong membrane and/or a dot-like cytoplasmic staining reaction.
Low Expression	Activated inter and perifollicular lymphocytes show a weak to strong membrane and/or a dot-like cytoplasmic staining reaction.
Non-expression	NA

Note: Plasma cells may show a focal cytoplasmic staining reaction.



Tonsil (20x)

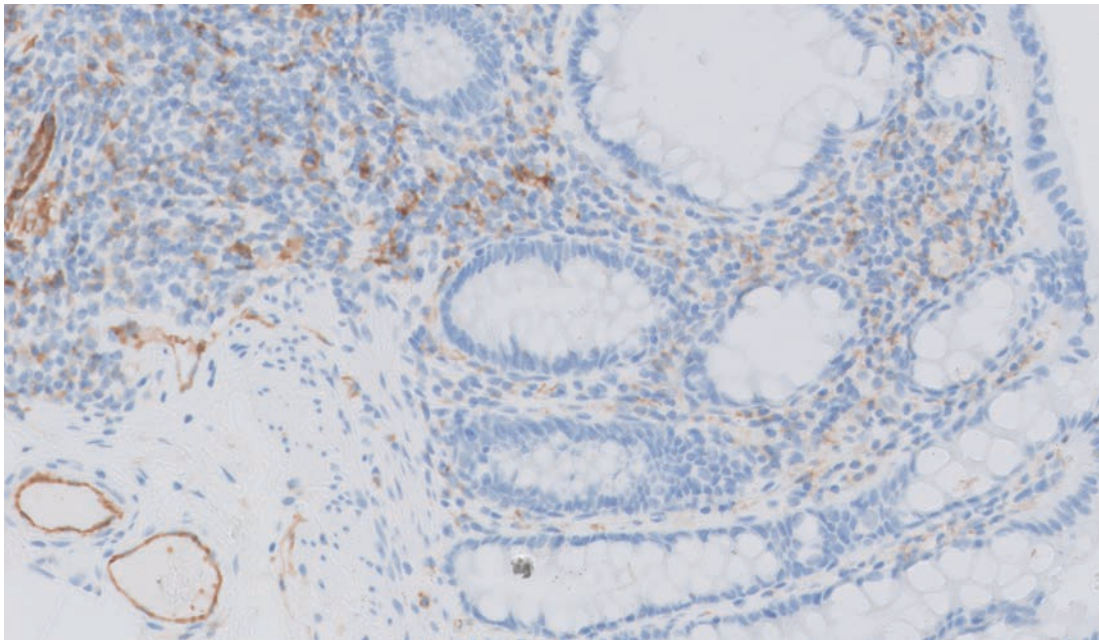


Tonsil (40x)

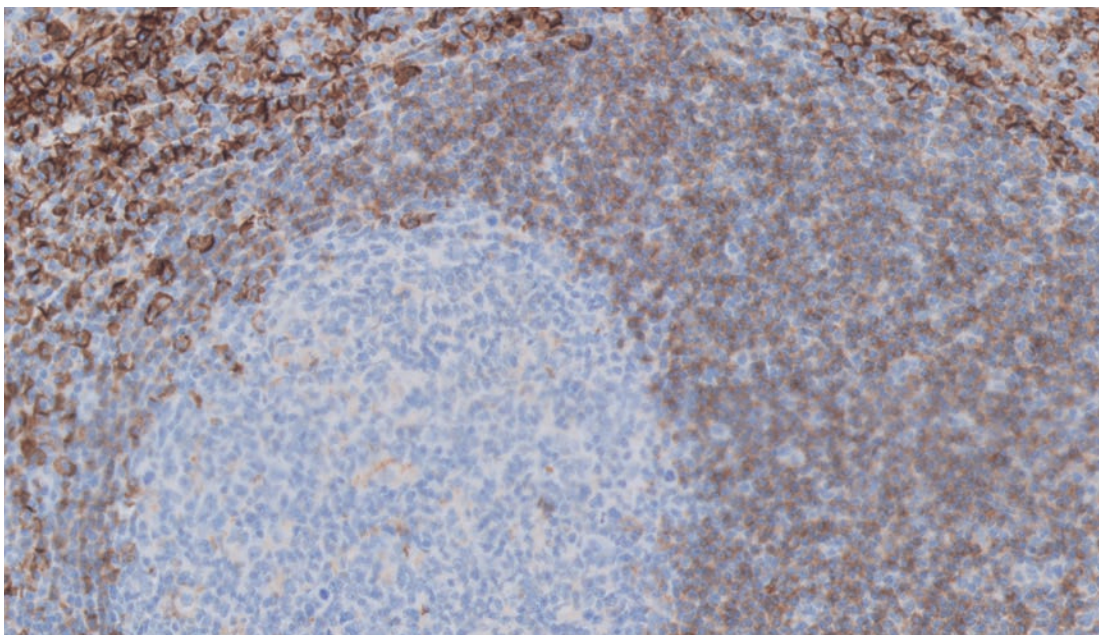
**Antibody:** Monoclonal Mouse Anti-Human  
**Clone:** CD31, Endothelial Cell  
**Code:** JC70A  
 GA610 | IR610

Reaction Location	Membrane and cytoplasm	
Quality Control	Colon/Appendix	Tonsil
High Expression	Endothelial cells of the large vessels show a moderate to strong staining reaction.	Plasma cells show a moderate to strong staining reaction.
Low Expression	Activated B and T cells in lamina propria show a weak to moderate staining reaction.	B cells in the mantle zone show a weak to moderate staining reaction.
Non-expression	Columnar epithelial cells.	NA

Note: Predominantly membrane staining, with weaker cytoplasmic staining



Colon (20x)

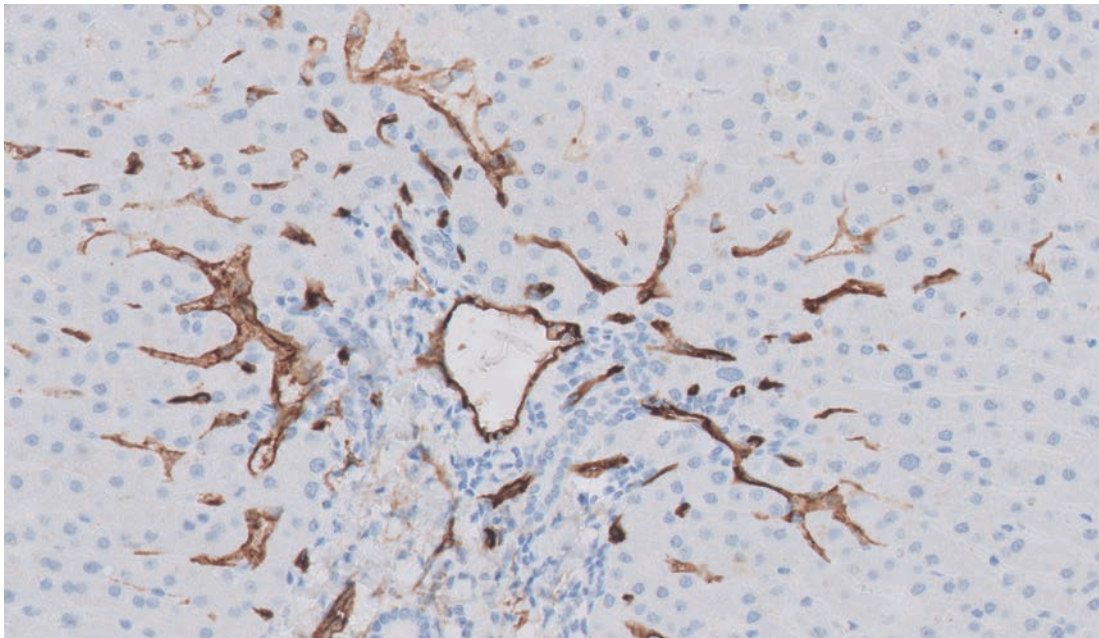


Tonsil (20x)

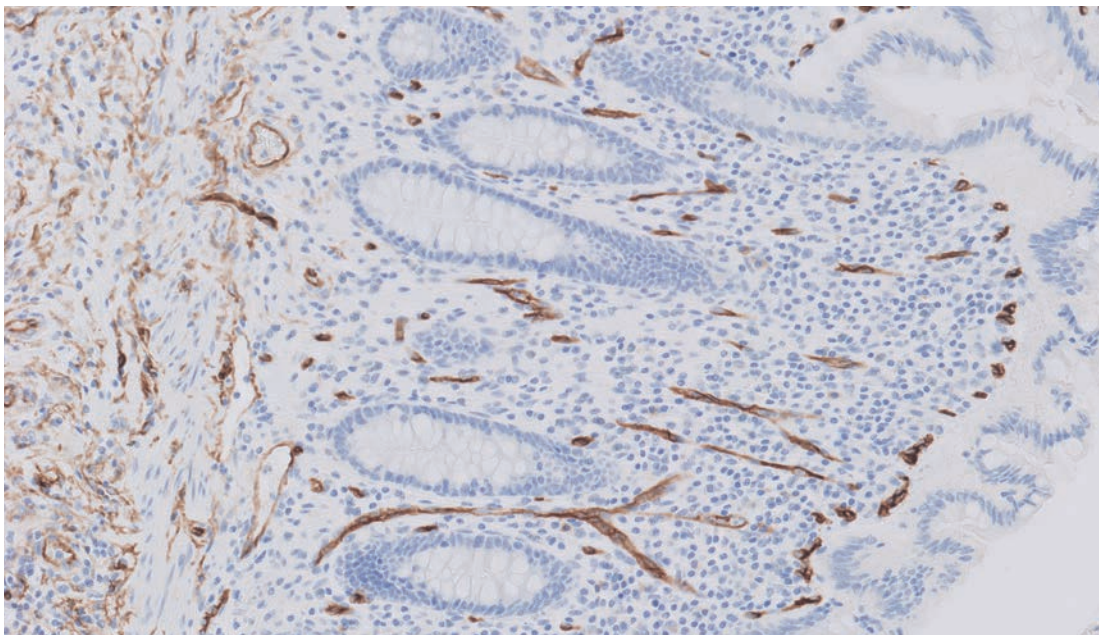
**Antibody:** Monoclonal Mouse Anti-Human CD34, Class II  
**Clone:** QBEnd 10  
**Code:** GA632 | IR632

Reaction Location	Membrane	
Quality Control	Liver	Colon/Appendix
High Expression	Endothelial cells of portal vessels and of the periportal sinusoids show a moderate to strong staining reaction.	Endothelial cells of all vessels show a distinct predominantly membranous staining reaction.
Low Expression	NA	NA
Non-expression	Hepatocytes	NA

Note: Especially, the endothelial cells of the small submucosal vessels should be demonstrated.



Liver (20x)

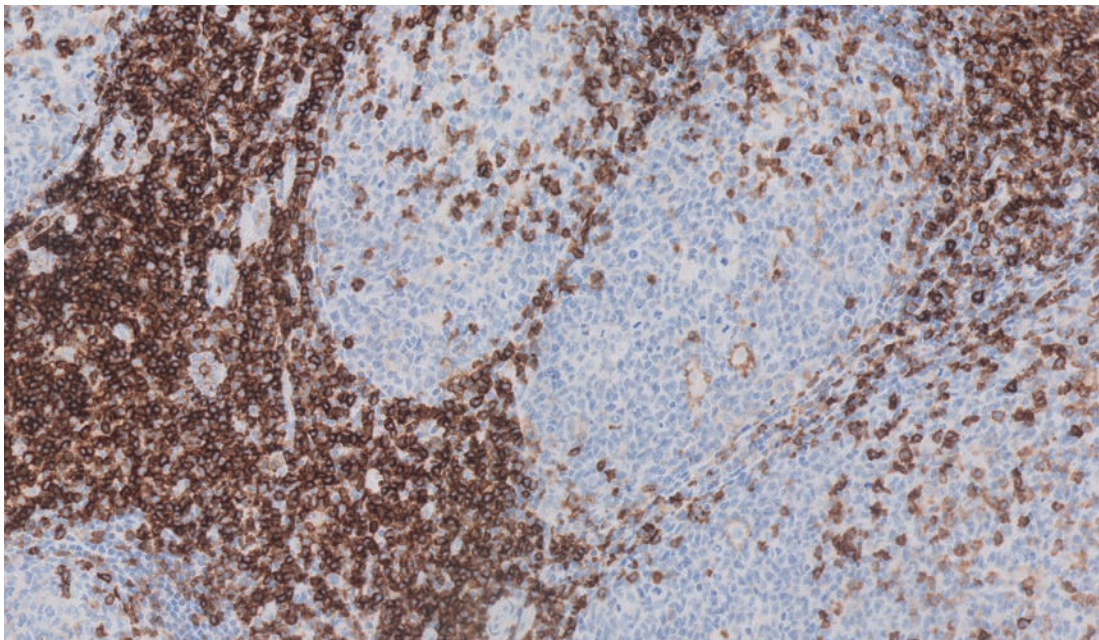


Appendix (20x)

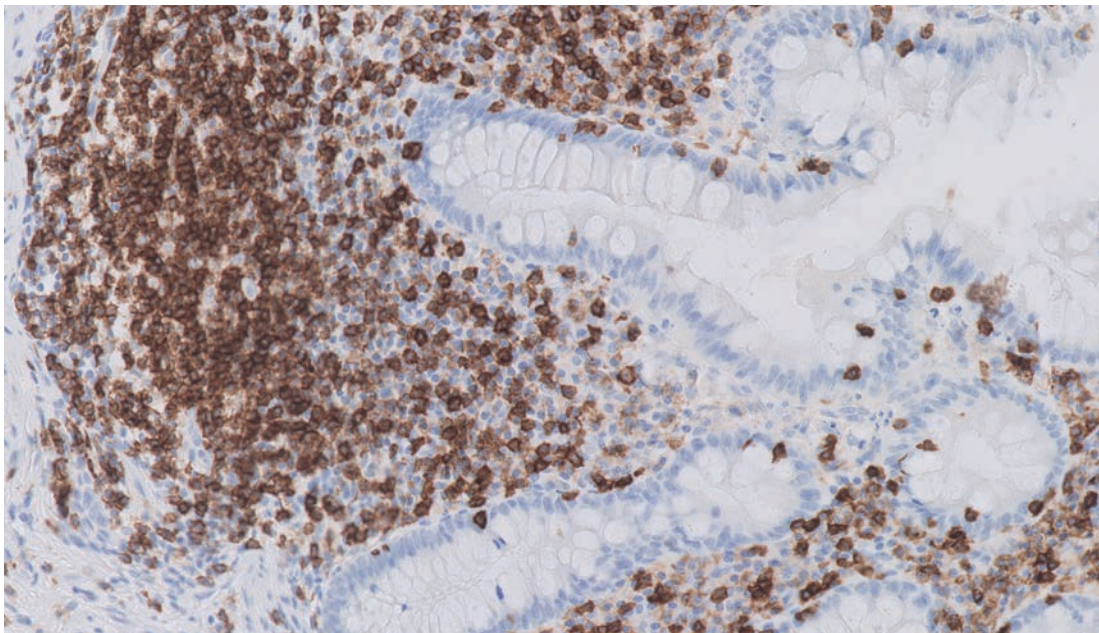


**Antibody:** Monoclonal Mouse Anti-Human CD43  
**Clone:** DF-T1  
**Code:** GA636 | IR636

Reaction Location	Membrane	
Quality Control	Tonsil	Colon/Appendix
High Expression	Virtually all T cells show a moderate to strong staining reaction.	T cells and plasma cells in lamina propria show a moderate to strong staining reaction.
Low Expression	Macrophages, e.g. within germinal centers, show a weak to moderate staining reaction.	Macrophages show a weak to moderate staining reaction.
Non-expression	NA	Epithelial cells.



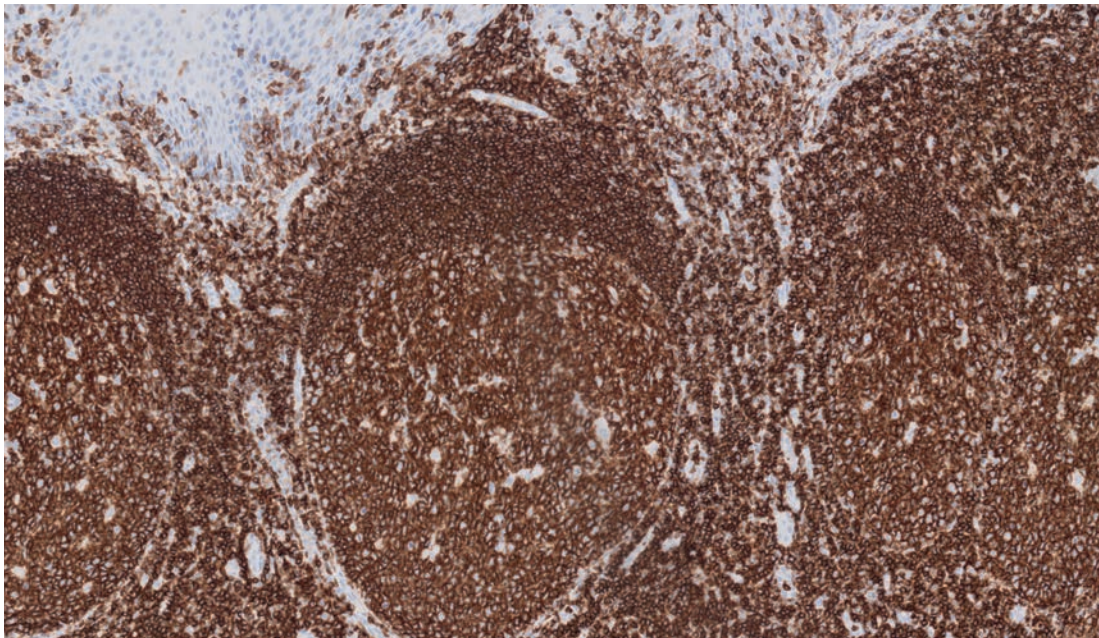
Tonsil (20x)



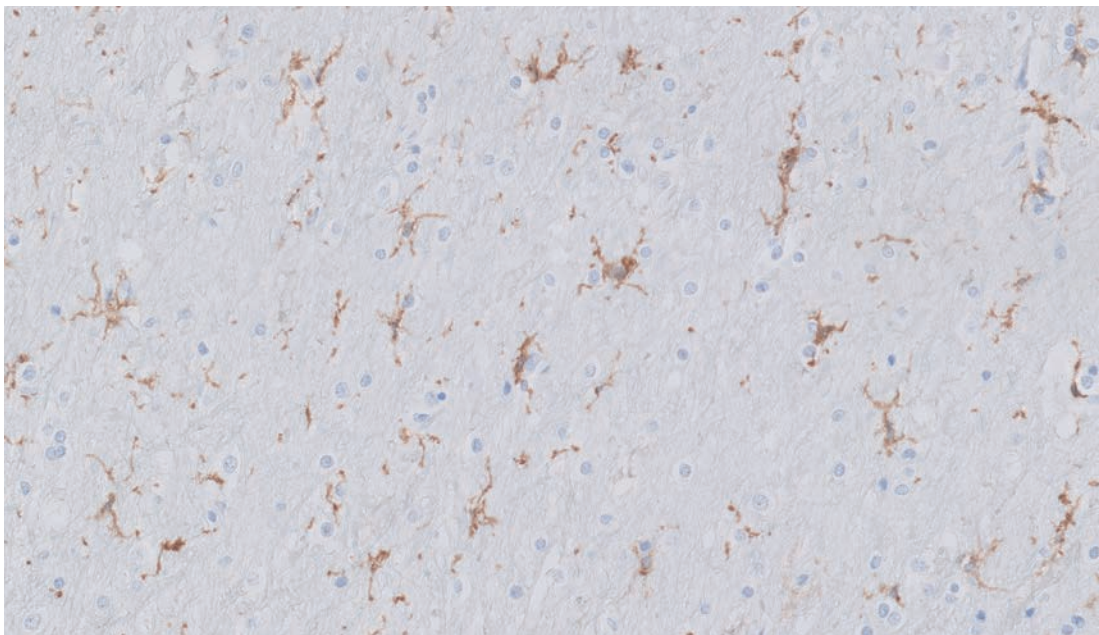
Appendix (20x)

**Antibody:** Monoclonal Mouse Anti-Human  
**Clone:** CD45, Leucocyte Common Antigen  
**Code:** 2B11 + PD7/26  
 GA751 | IR751

Reaction Location	Membrane	
Quality Control	Tonsil	Brain
High Expression	B and T cells show a moderate to strong staining reaction.	NA
Low Expression	NA	Microglial cells show a weak to moderate staining reaction.
Non-expression	NA	NA



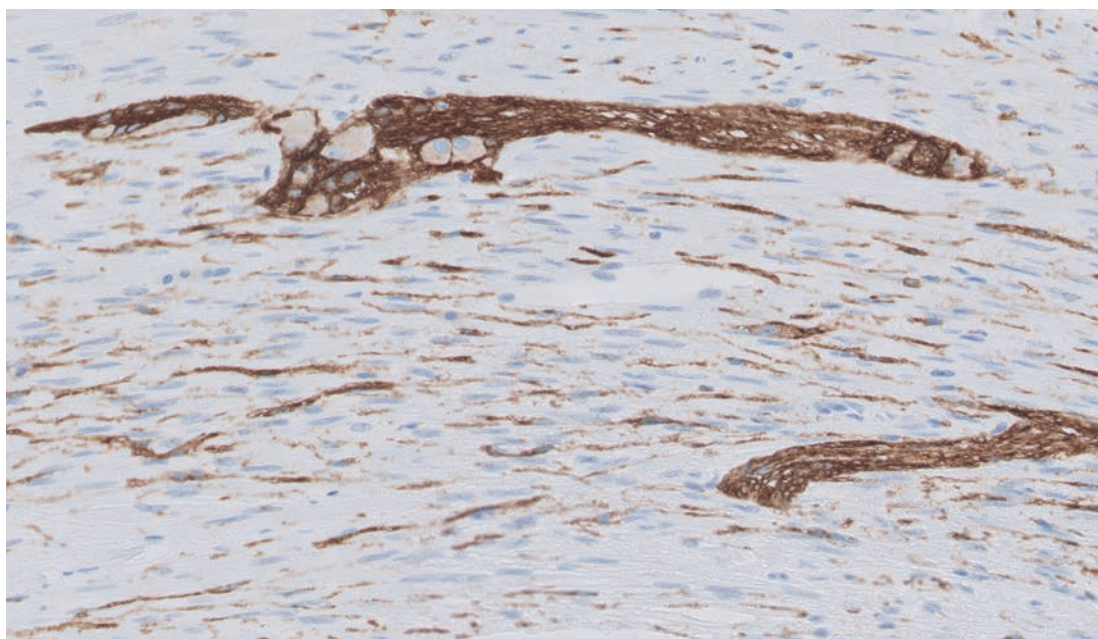
Tonsil (10x)



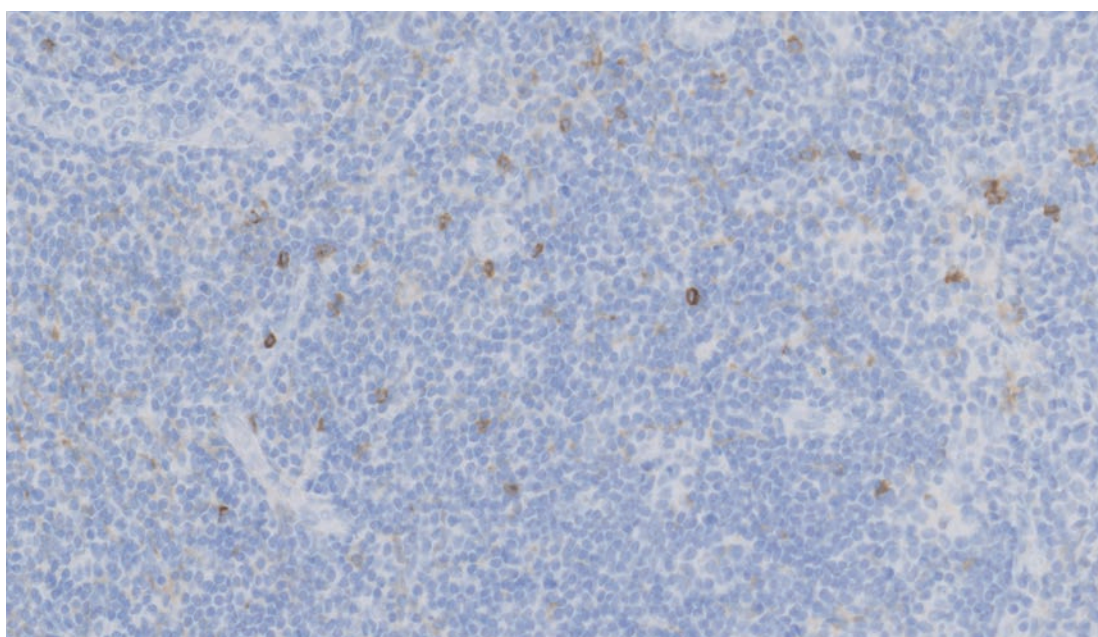
Brain (20x)

**Antibody:** Monoclonal Mouse Anti-Human  
**Clone:** CD56  
**Code:** 123C3  
**Code:** IR628

Reaction Location	Membrane	
Quality Control	Colon/Appendix	Tonsil
High Expression	Ganglion cells and axons of the Auerbach's and Meissner's plexus show a moderate to strong staining reaction.	NA
Low Expression	NA	Isolated T cells (NK cells) in the interfollicular areas show a weak to moderate staining reaction.
Non-expression	NA	NA



Colon (20x)

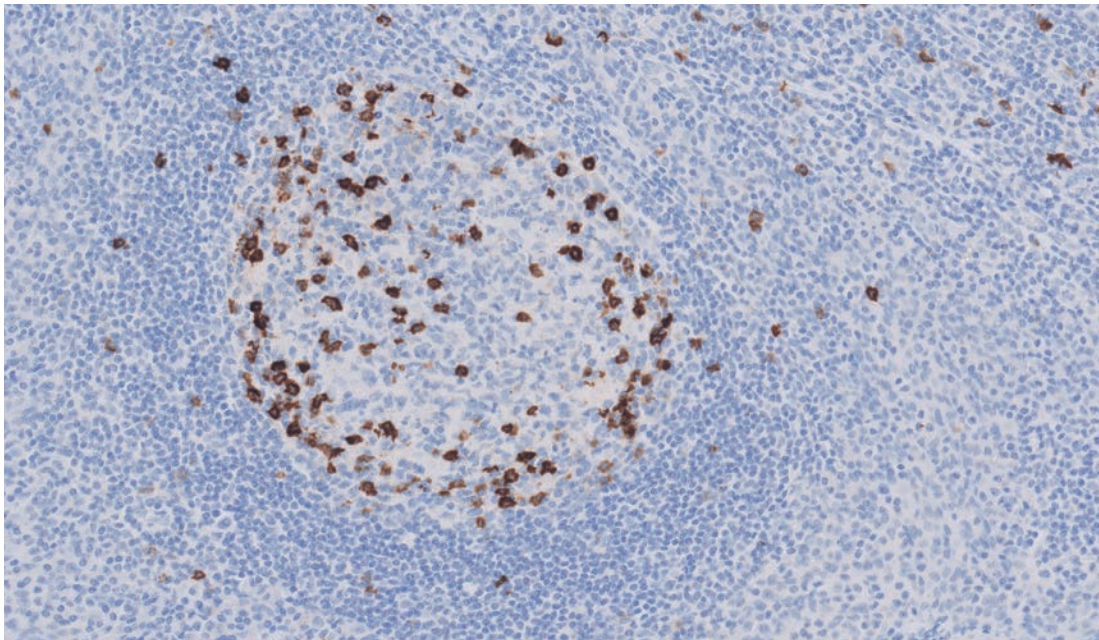


Tonsil (20x)

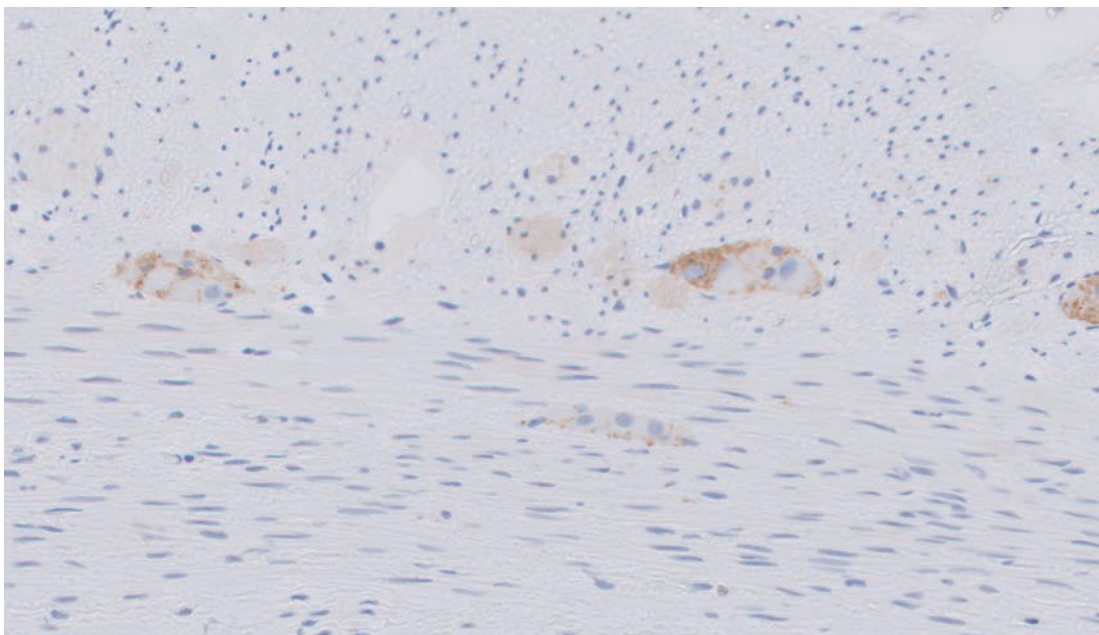
**Antibody:** Monoclonal Mouse Anti-Human  
**Clone:** CD57  
**Code:** TB01  
 GA647 | IR647

Reaction Location		Membrane and/or cytoplasm	
Quality Control	Tonsil		Colon/Appendix
High Expression	NK/T cells in the T zone and at the edge of the germinal centers show a moderate to strong cytoplasmic and/or membrane staining reaction.		NA
Low Expression	NA	Schwann cells and scattered neurons, in e.g. the Auerbach's and Meissner's plexus, show a weak to moderate cytoplasmic and/or membrane staining reaction.	
Non-expression	NA	NA	

Note: The NK cells typically show a weaker staining than T cells.



Tonsil (20x)

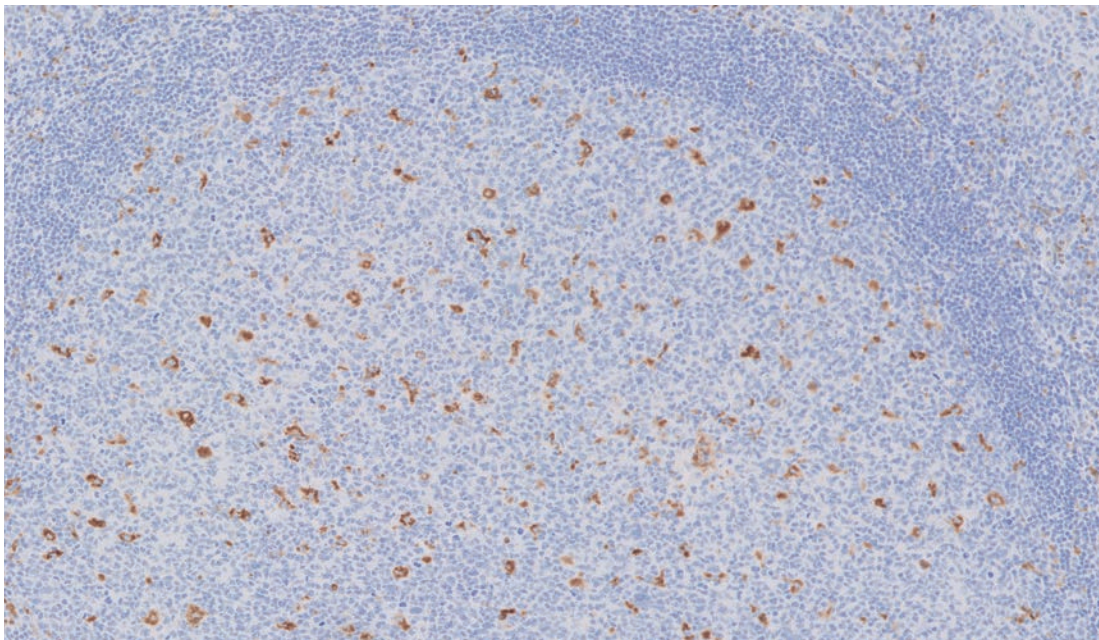


Appendix (20x)

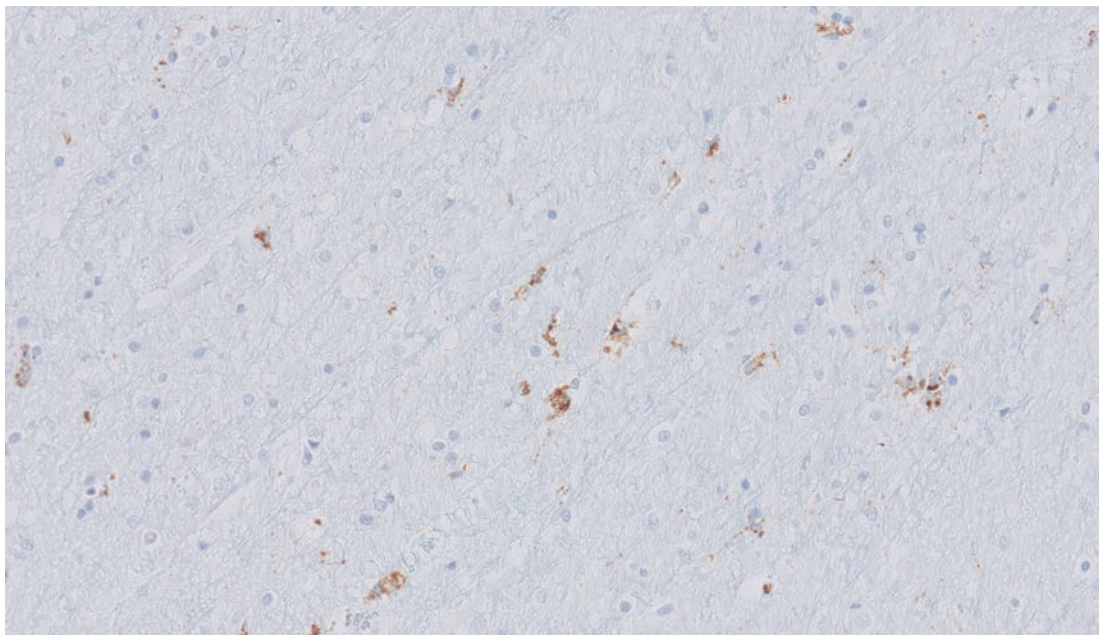
**Antibody:** Monoclonal Mouse Anti-Human CD68  
**Clone:** KP1  
**Code:** GA609 | IR609

Reaction Location	Cytoplasm	
Quality Control	Tonsil	Brain
High Expression	Macrophages in the germinal centers show a moderate to strong staining reaction.	NA
Low Expression	NA	Microglial cells show a weak to moderate staining reaction.
Non-expression	Germinal center B cells.	NA

Note: In the interfollicular areas of tonsil, the granulocytes and macrophages should show a granular cytoplasmic staining reaction.



Tonsil (20x)

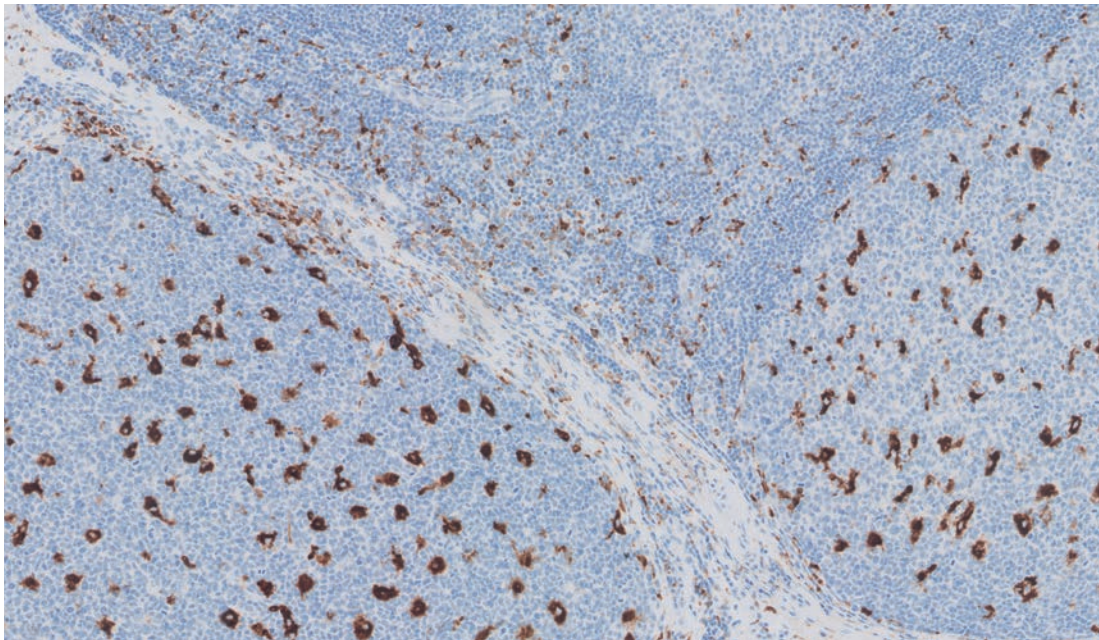


Brain (20x)

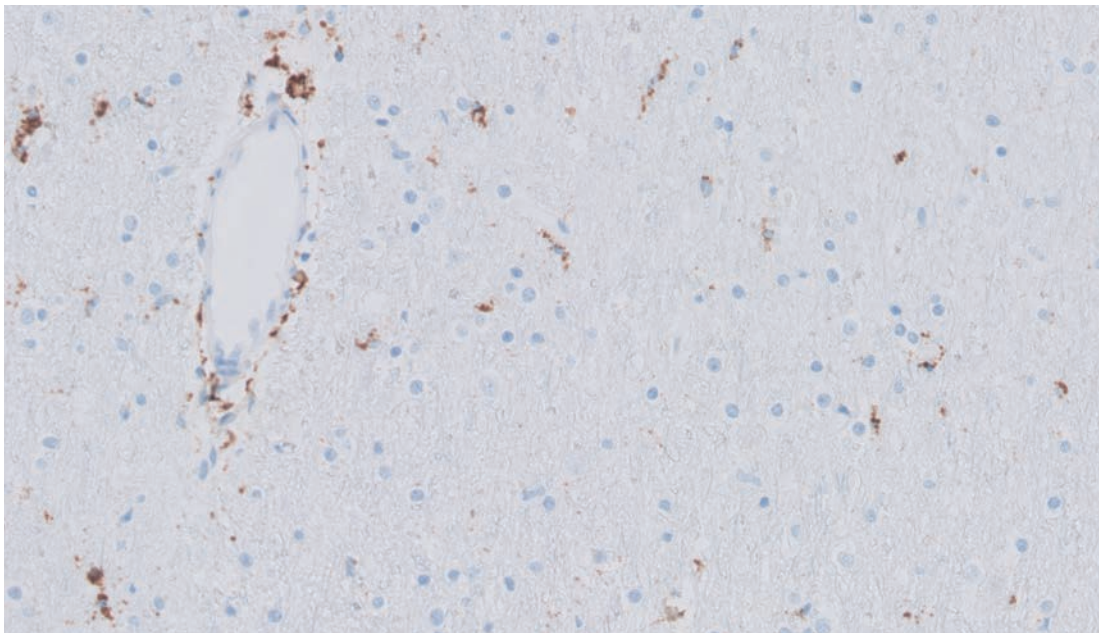
**Antibody:** Monoclonal Mouse Anti-Human  
**Clone:** CD68  
**Code:** PG-M1  
 GA613 | IR613

Reaction Location	Cytoplasm	
Quality Control	Tonsil	Brain
High Expression	Macrophages in the germinal centers show a moderate to strong staining reaction.	NA
Low Expression	NA	Microglial cells show a weak to moderate staining reaction.
Non-expression	Germinal center B cells.	NA

Note: In the interfollicular areas of tonsil, the granulocytes and macrophages should show a granular cytoplasmic staining reaction.



Tonsil (10x)

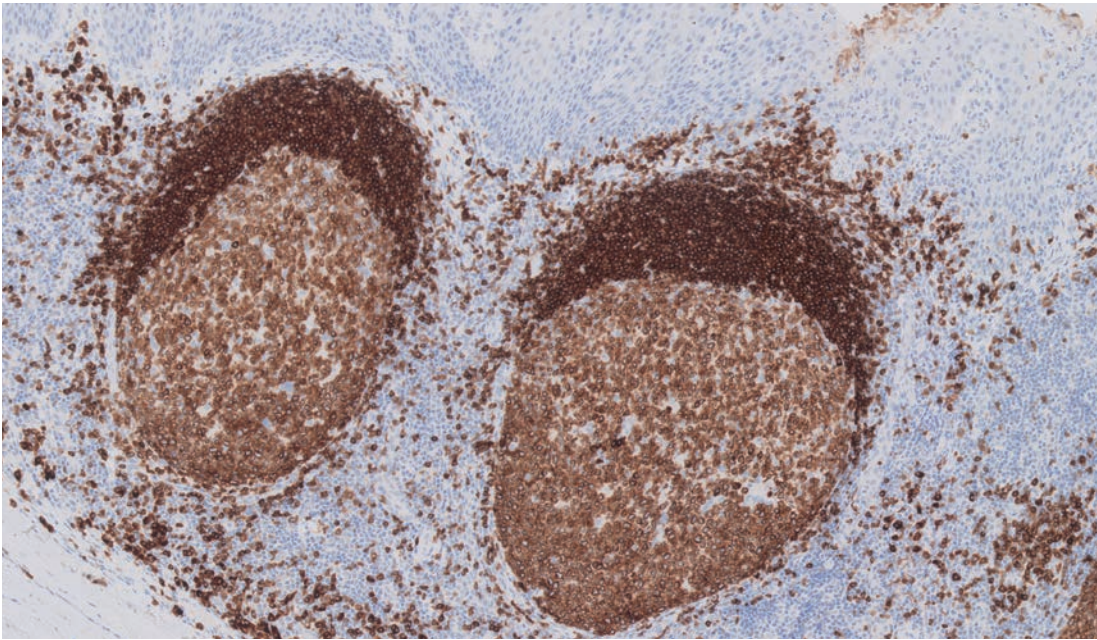


Brain (20x)

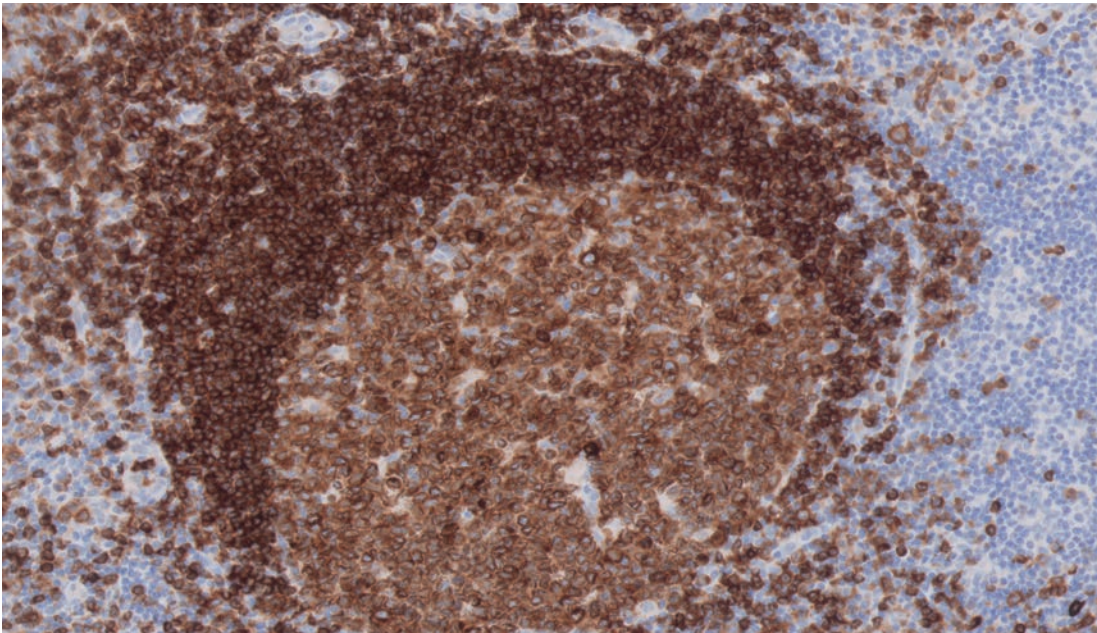
**Antibody:** Monoclonal Mouse Anti-Human CD79a  
**Clone:** JCB117  
**Code:** GA621 | IR621

Reaction Location	Membrane and cytoplasm
Quality Control	Tonsil
High Expression	Plasma cells show strong cytoplasmic staining reaction. B cells in the mantle zone show a moderate to strong predominantly membranous staining reaction.
Low Expression	B cells in the germinal centers show a weak to moderate staining reaction.
Non-expression	Squamous epithelial cells and T cells.

Note: Plasma cells should show a strong cytoplasmic staining reaction.



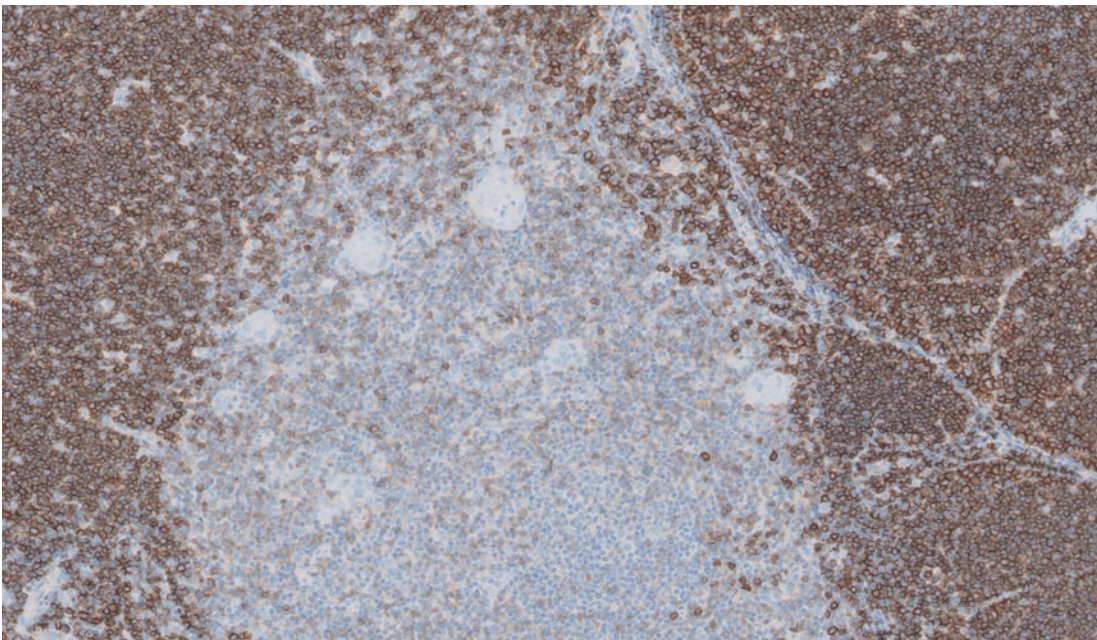
Tonsil (10x)



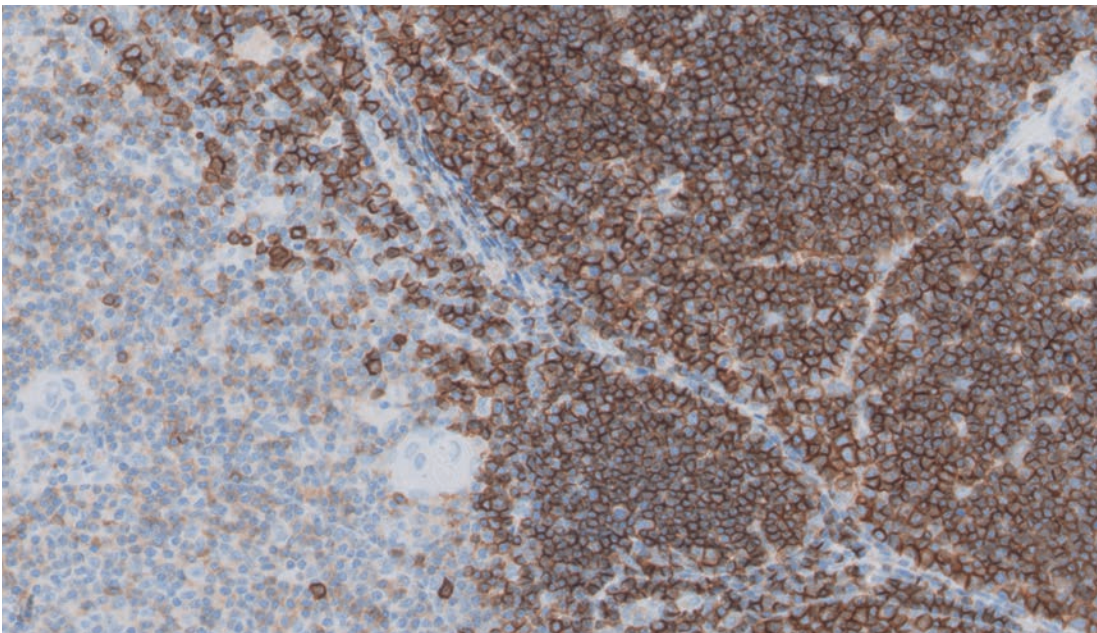
Tonsil (20x)

**Antibody:** Monoclonal Mouse Anti-Human  
 CD99, MIC2 Gene Products, Ewing's Sarcoma Marker  
**Clone:** 12E7  
**Code:** IR057

Reaction Location	Membrane and cytoplasm
Quality Control	Thymus
High Expression	Cortical thymocytes show moderate to strong membranous staining reaction.
Low Expression	Dispersed medullary thymocytes show weak to moderate membranous staining reaction.
Non-expression	NA



Thymus (10x)

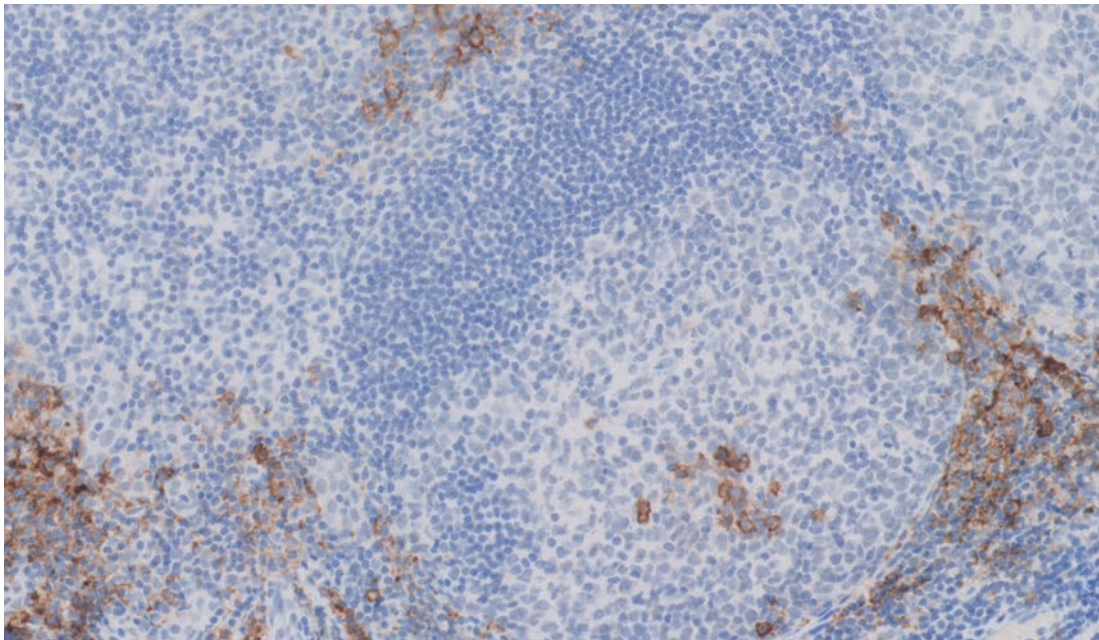


Thymus (20x)

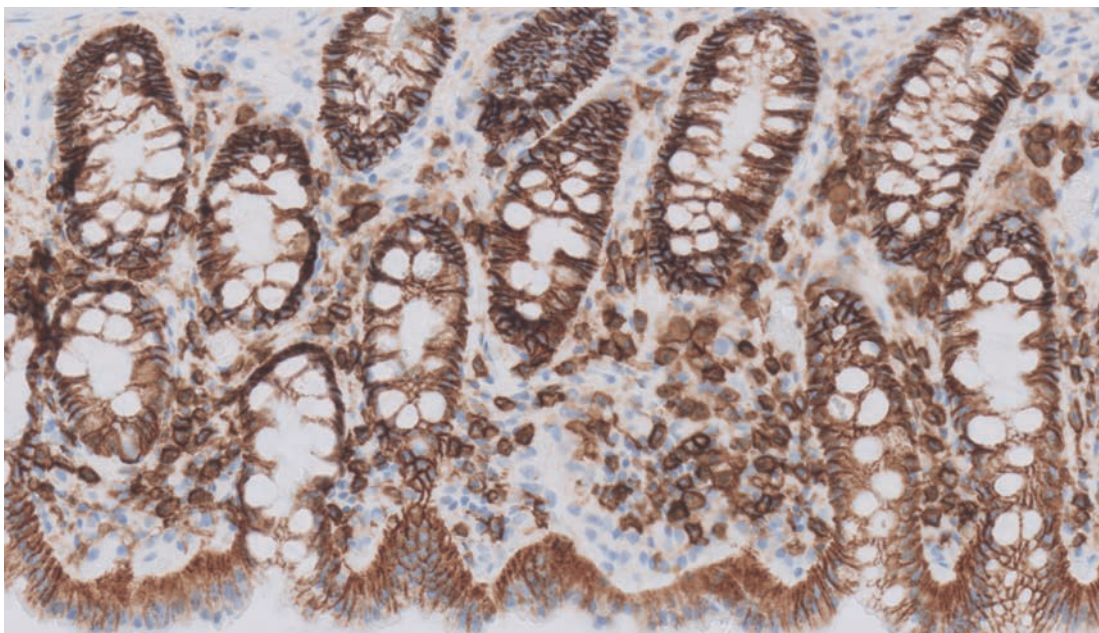


**Antibody:** Monoclonal Mouse Anti-Human CD138  
**Clone:** MI15  
**Code:** GA642 | IR642

Reaction Location		Membrane
Quality Control	Tonsil	Colon/Appendix
High Expression	Plasma cells show a moderate to strong staining reaction.	The majority of the plasma cells in lamina propria show a moderate to strong staining reaction. The luminal and basal epithelial cells are demonstrated.
Low Expression	Epithelial cells should show a weak to moderate staining reaction.	NA
Non-expression	The majority of the germinal center cells and peripheral lymphocytes.	NA



Tonsil (20x)

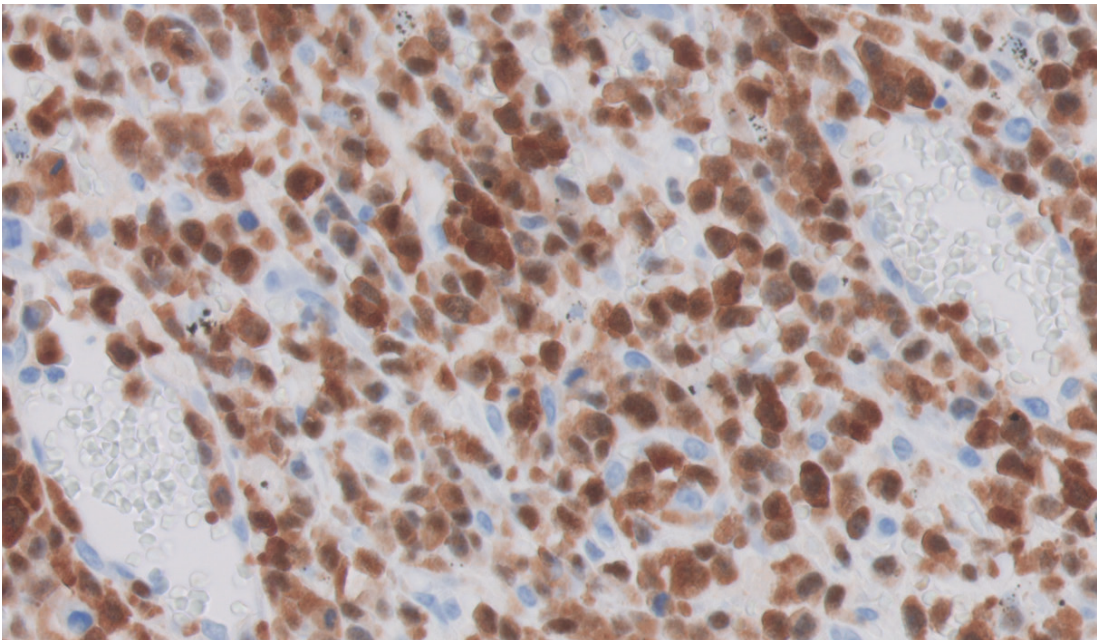


Colon (20x)

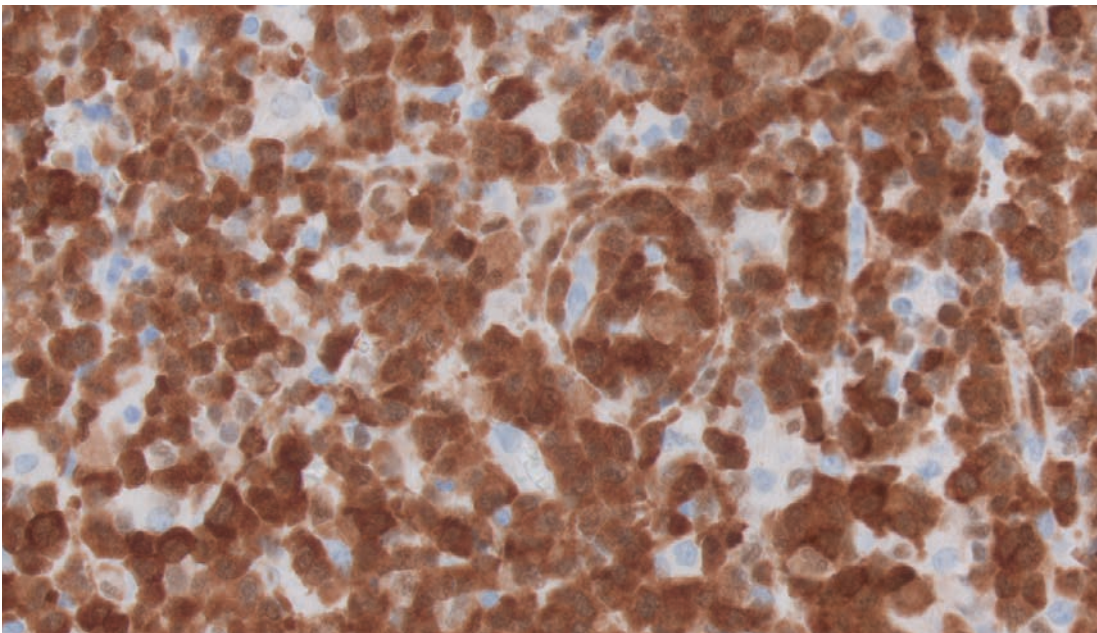
**Antibody:** Monoclonal Mouse Anti-Human  
CD246, ALK Protein  
**Clone:** ALK1  
**Code:** GA641 | IR641

Reaction Location	Nucleus and/or cytoplasm
Quality Control	Anaplastic large cell lymphoma with t(2;5) translocation
High Expression	Neoplastic cells show a moderate to strong staining reaction.
Low Expression	NA
Non-expression	NA

Note: A strong staining in nuclei and a weaker cytoplasmic staining is often seen.



Anaplastic large cell lymphoma (40x)



Anaplastic large cell lymphoma (40x)

Antibody:

Monoclonal Mouse Anti-Human

CDX-2

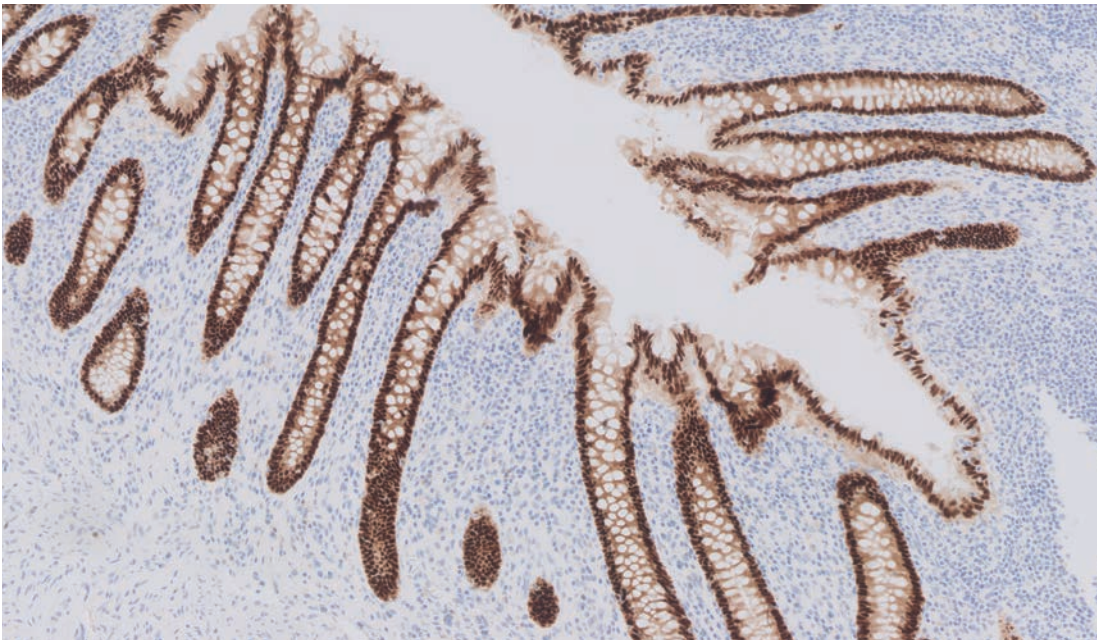
Clone:

DAK-CDX-2

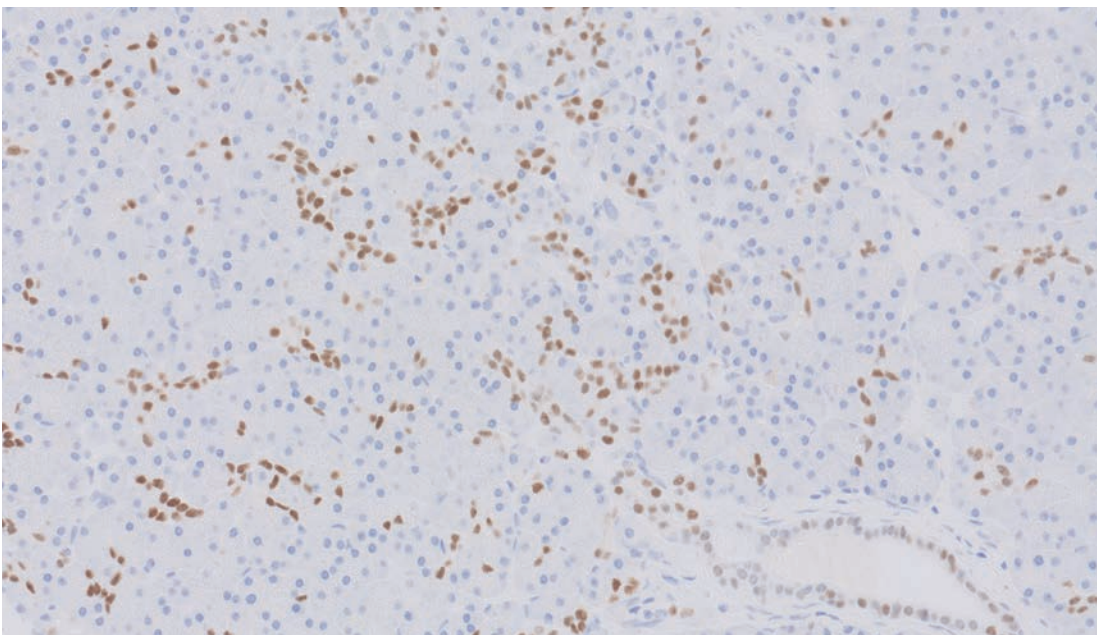
Code:

GA080 | IR080

Reaction Location	Nucleus	
Quality Control	Appendix	Pancreas
High Expression	Columnar epithelial cells show a moderate to strong staining reaction.	NA
Low Expression	NA	Ductal and scattered intercalated epithelial cells show a weak to moderate staining reaction.
Non-expression	NA	NA



Appendix (10x)

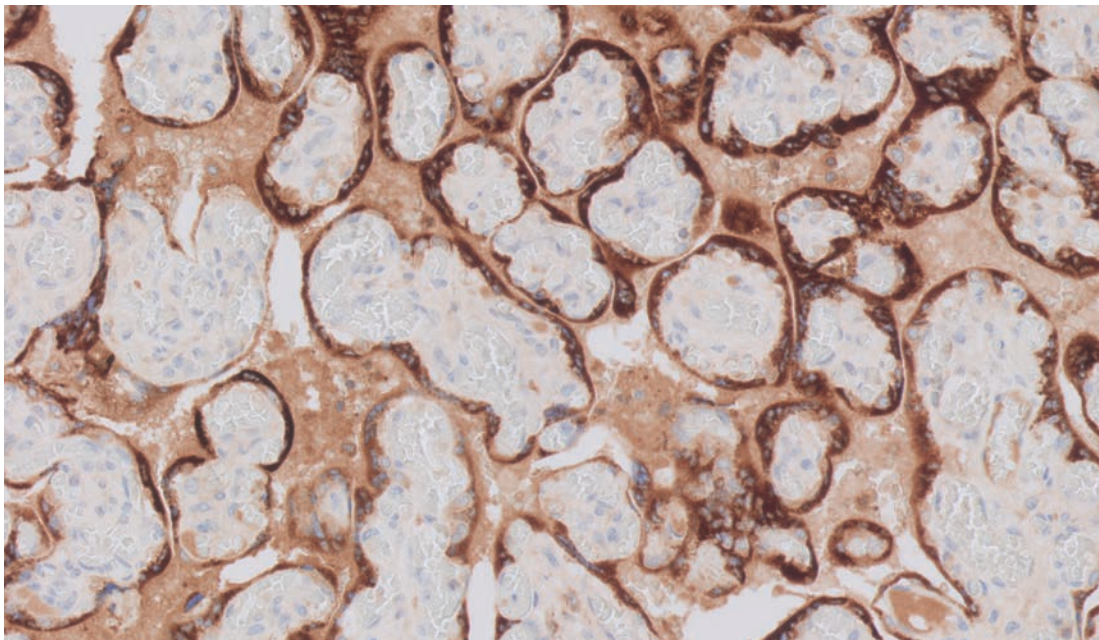


Pancreas (20x)

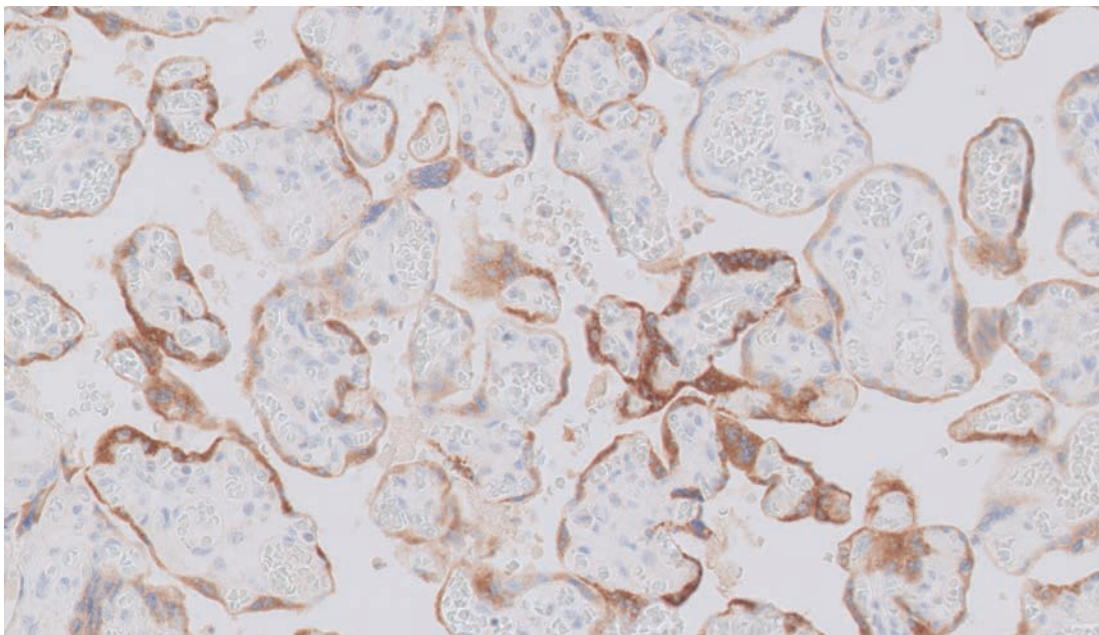
**Antibody:** Polyclonal Rabbit Anti-Human  
**Clone:** Chorionic Gonadotropin  
**Code:** Polyclonal  
 GA508 | IR508

Reaction Location	Cytoplasm
Quality Control	Placenta
High Expression	Trophoblasts and syncytiotrophoblasts show a moderate to strong staining reaction.
Low Expression	Macrophages and serum show a weak staining reaction.
Non-expression	Stroma cells.

Note: The staining pattern in placenta may vary depending on pregnancy stage.



Placenta (20x)

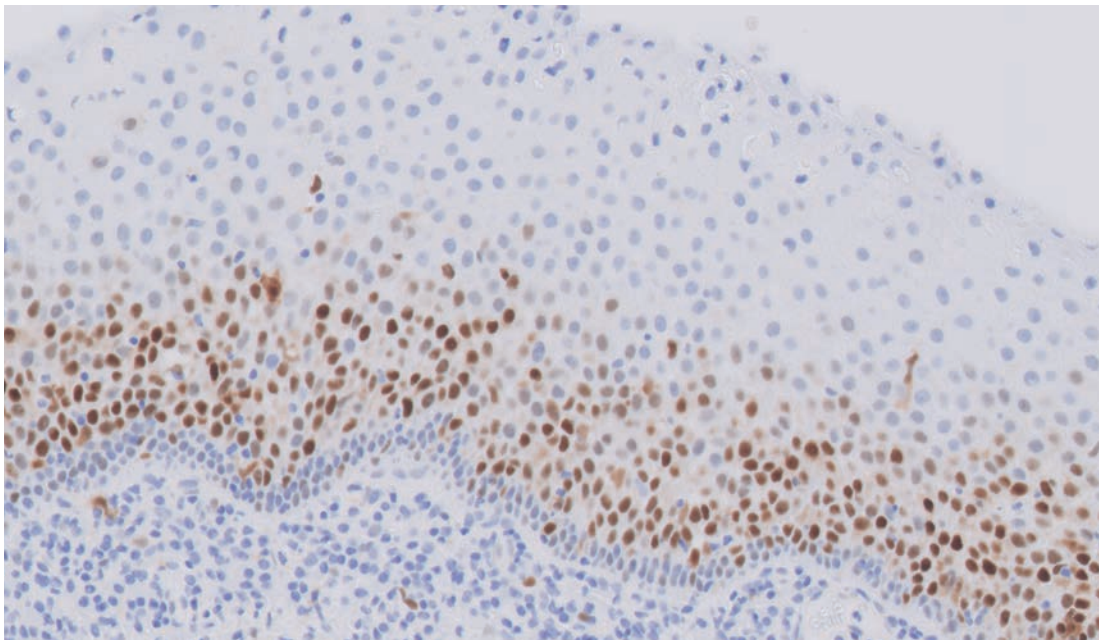


Placenta (20x)

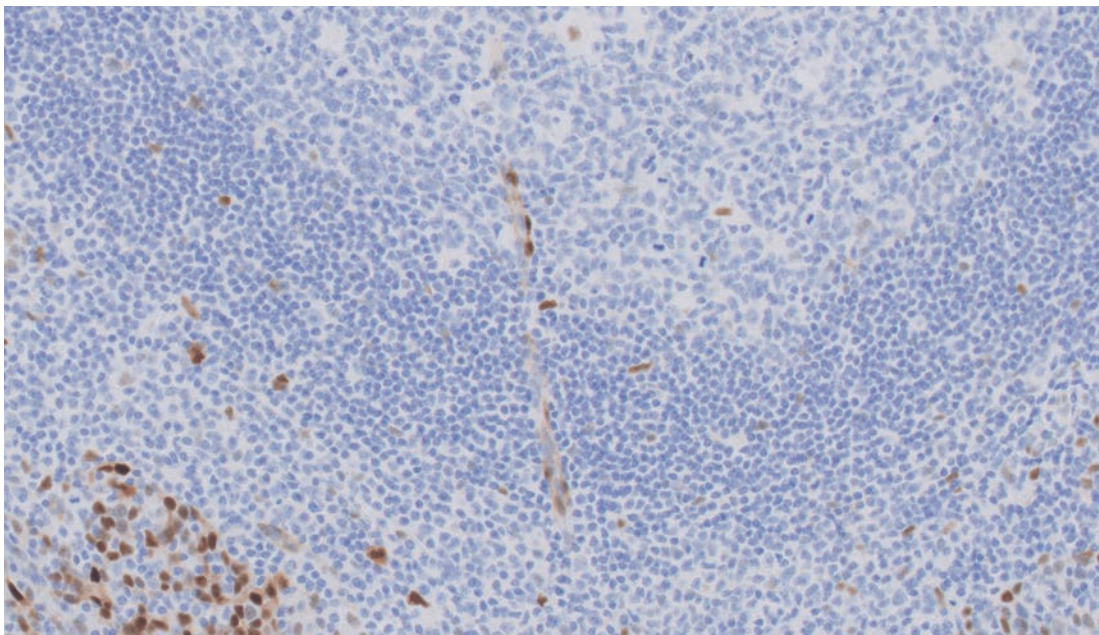
**Antibody:** Monoclonal Rabbit Anti-Human  
**Clone:** Cyclin D1  
**Code:** EP12  
 GA083 | IR083

Reaction Location	Nucleus
Quality Control	<b>Tonsil</b>
High Expression	Suprabasal squamous epithelial cells show a weak to strong staining reaction.
Low Expression	Scattered endothelial cells show a weak to moderate staining reaction.
Non-expression	Vast majority of lymphoid cells.

Note: A weak cytoplasmic staining reaction together with the specific nuclear reaction is acceptable.



Tonsil (20x)

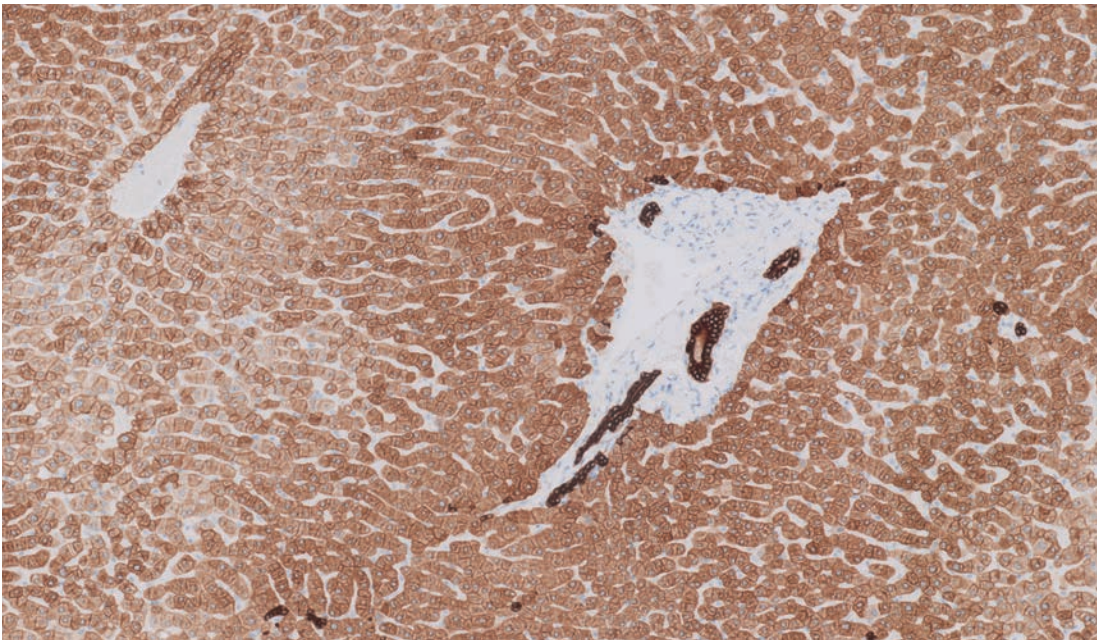


Tonsil (20x)

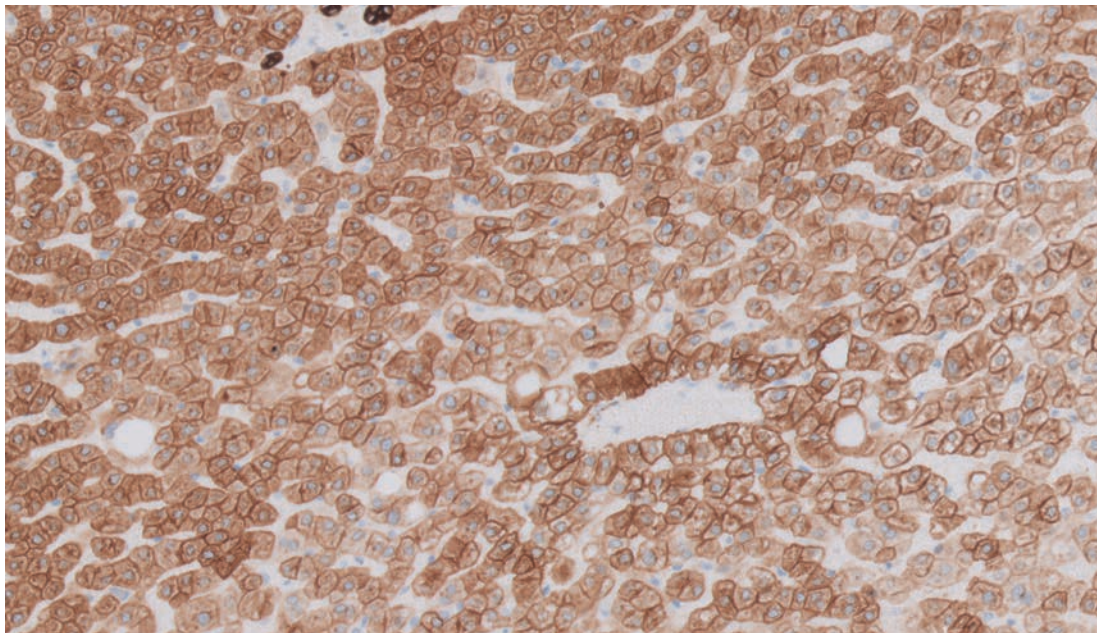
**Antibody:** Monoclonal Mouse Anti-Human  
**Clone:** Cytokeratin  
**Code:** AE1/AE3  
 GA053 | IR053

Reaction Location	Cytoplasm
Quality Control	Liver
High Expression	Bile ducts cells show a moderate to strong staining reaction.
Low Expression	Hepatocytes show a weak to moderate, predominantly membranous, staining reaction.
Non-expression	Stroma cells.

Note: The interdigitating reticulum cells in lymphoid tissue can be positive.



Liver (10x)

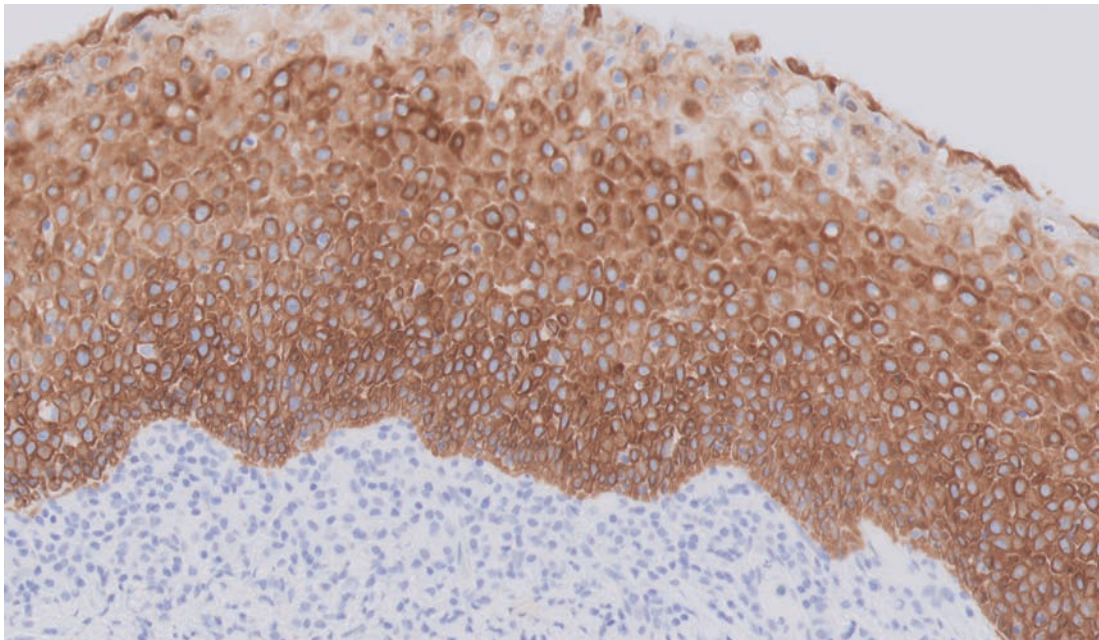


Liver (20x)

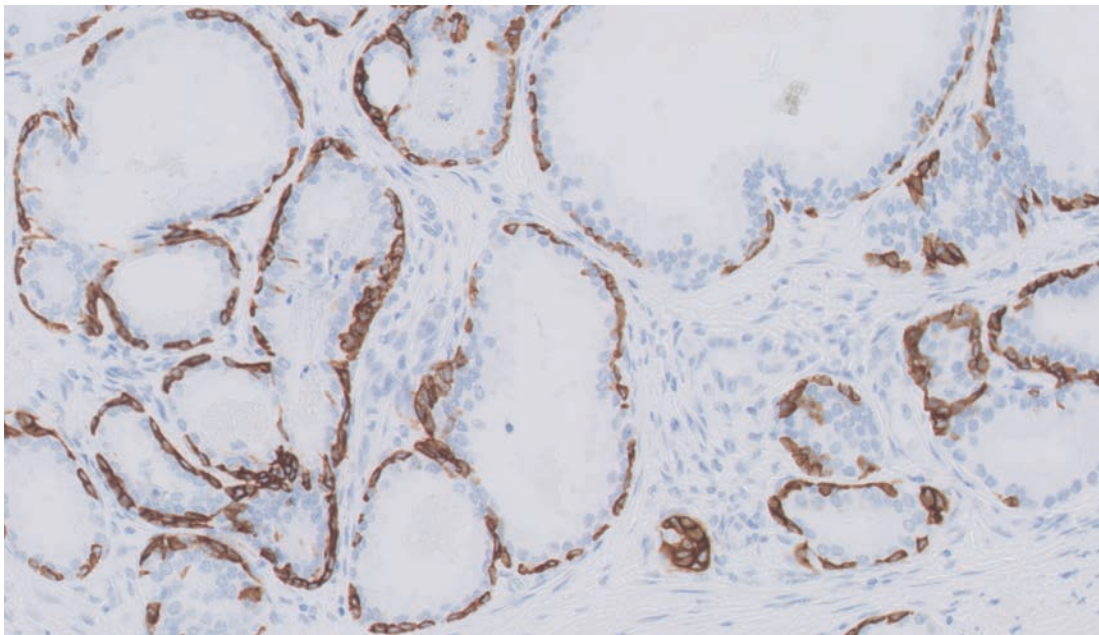
**Antibody:** Monoclonal Mouse Anti-Human  
**Clone:** Cytokeratin 5/6  
**Code:** D5/16 B4  
 GA780 | IR780

Reaction Location	Cytoplasm	
Quality Control	Tonsil	Prostate
High Expression	Squamous epithelial cells show a moderate to strong staining reaction.	Basal cells show a moderate to strong cytoplasmic staining reaction with no or only focal reaction in the secretory cells.
Low Expression	NA	NA
Non-expression	NA	NA

Note: The staining reaction is seen in all cell layers in the epithelial surface.



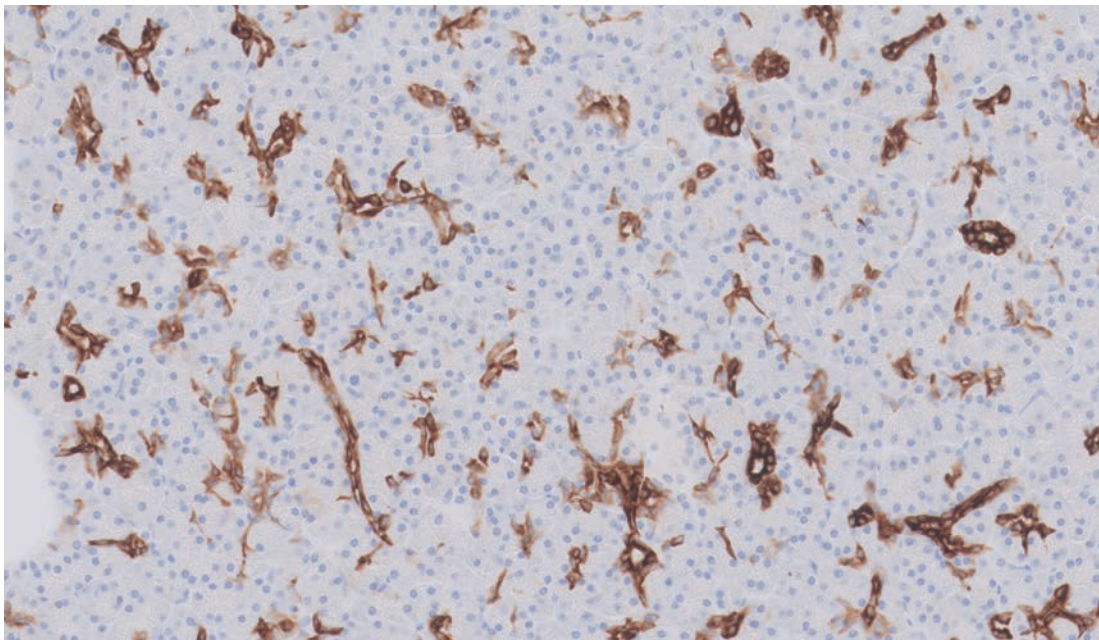
Tonsil (20x)



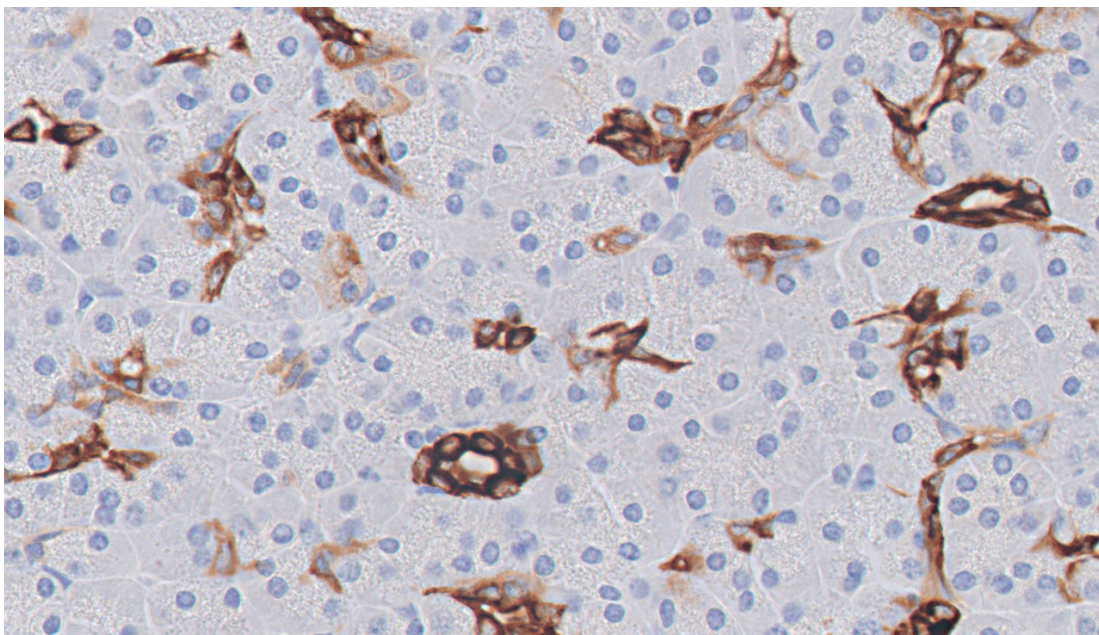
Prostate (20x)

Antibody: Monoclonal Mouse Anti-Human  
Cytokeratin 7  
Clone: OV-TL12/30  
Code: GA619 | IR619

Reaction Location	Cytoplasm
Quality Control	Pancreas
High Expression	Epithelial cells of the large acinar ducts show a moderate to strong staining reaction.
Low Expression	Epithelial cells of intercalating pancreatic ducts show a weak to moderate staining reaction.
Non-expression	Pancreatic acinar cells.



Pancreas (20x)



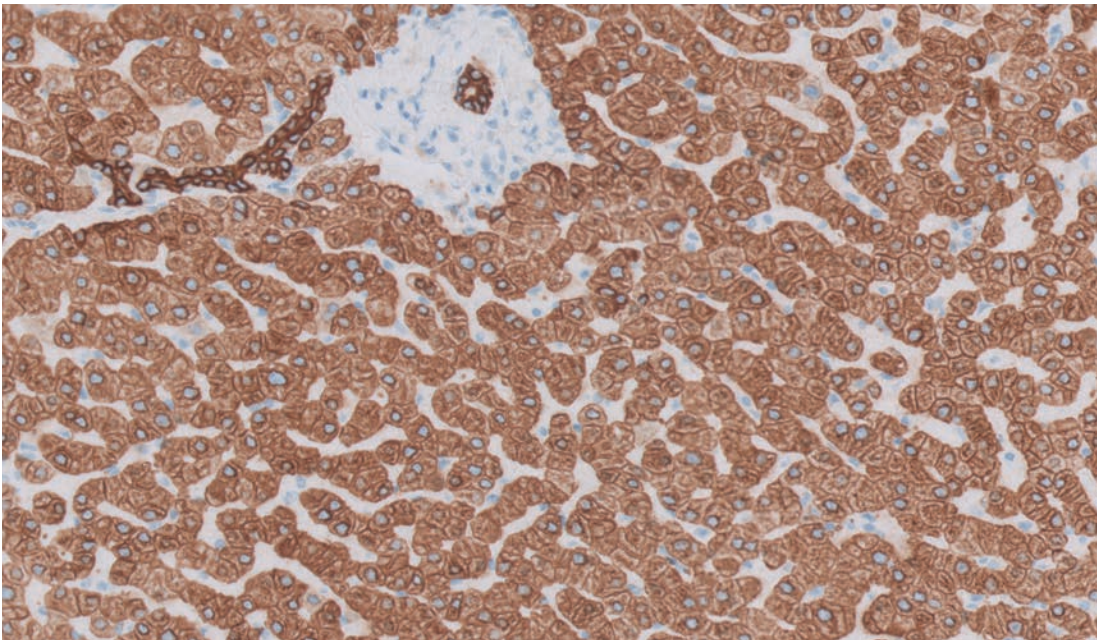
Pancreas (40x)



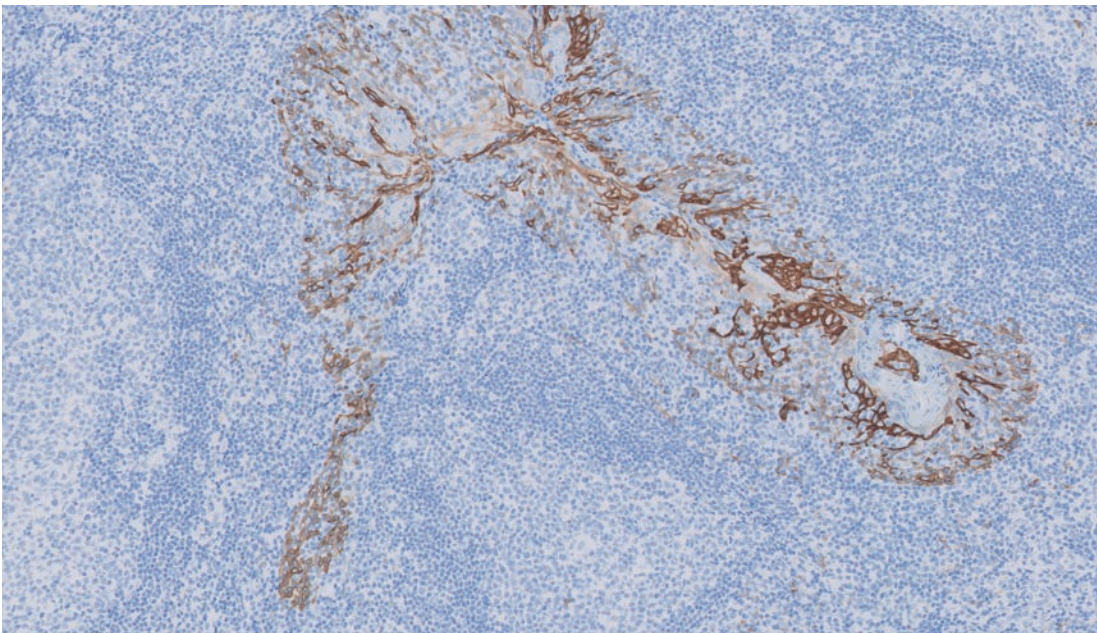
**Antibody:** Monoclonal Rabbit Anti-Human  
**Clone:** Cytokeratin 8/18  
**Code:** EP17/EP30  
 IR094

Reaction Location	Membrane and/or cytoplasm	
Quality Control	Liver	Tonsil
High Expression	Epithelial cells of bile ducts show a moderate to strong staining reaction.	Reactive squamous epithelial cells show a moderate to strong staining reaction.
Low Expression	Hepatocytes show a weak to moderate staining reaction.	NA
Non-expression	NA	NA

Note: Staining of interdigitating reticulum cells may be observed within lymphoid tissues.



Liver (20x)

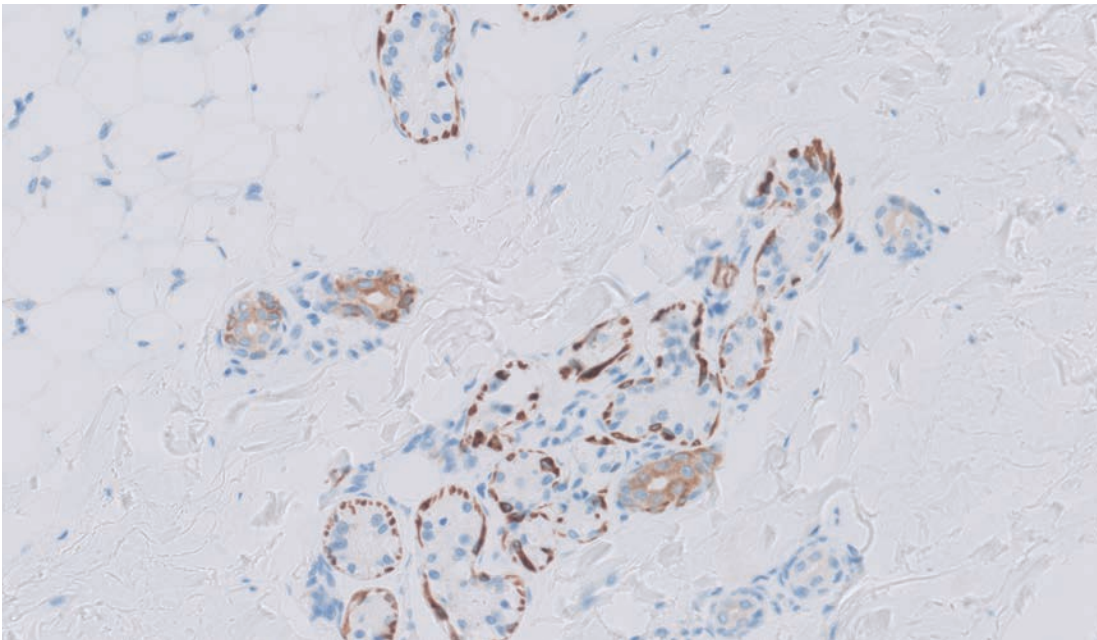


Tonsil (10x)

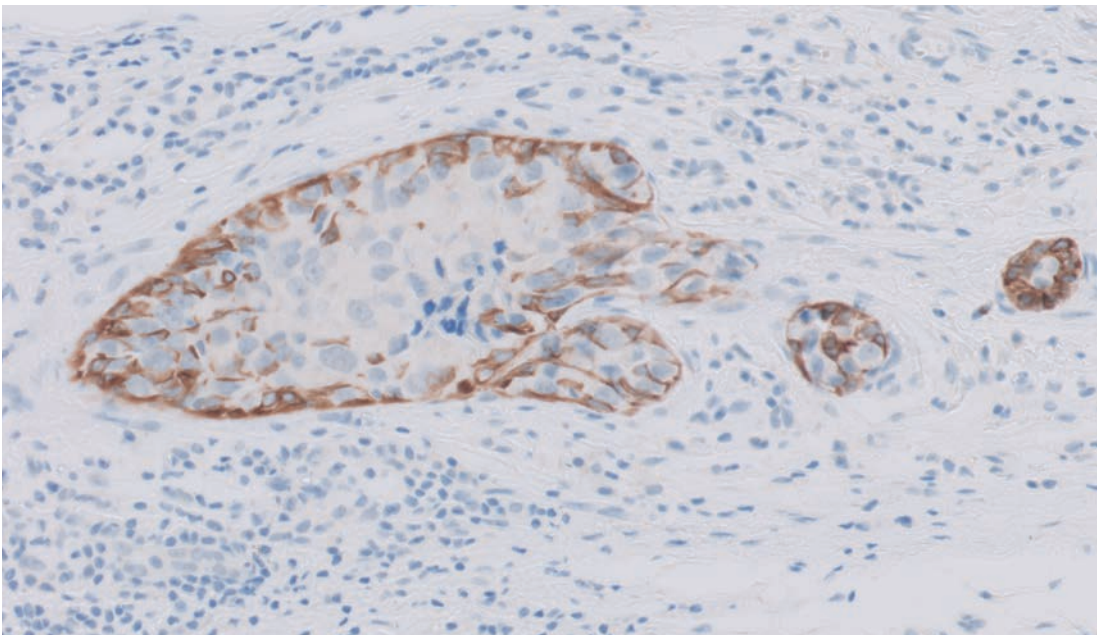
**Antibody:** Monoclonal Mouse Anti-Human  
**Clone:** Cytokeratin 17  
**Code:** E3  
 IR620

Reaction Location	Cytoplasm and/or membrane	
Quality Control	Skin	Breast hyperplasia
High Expression	Myoepithelial cells of the sweat glands show a moderate to strong staining reaction.	Myoepithelial cells of the epithelial glands show a strong and distinct staining reaction with no staining in the epithelial cells.
Low Expression	NA	NA
Non-expression	Normal gland epithelial cells and squamous epithelial cells.	NA

Note: Some gland epithelial cells may display staining of cytoplasm.



Skin (20x)

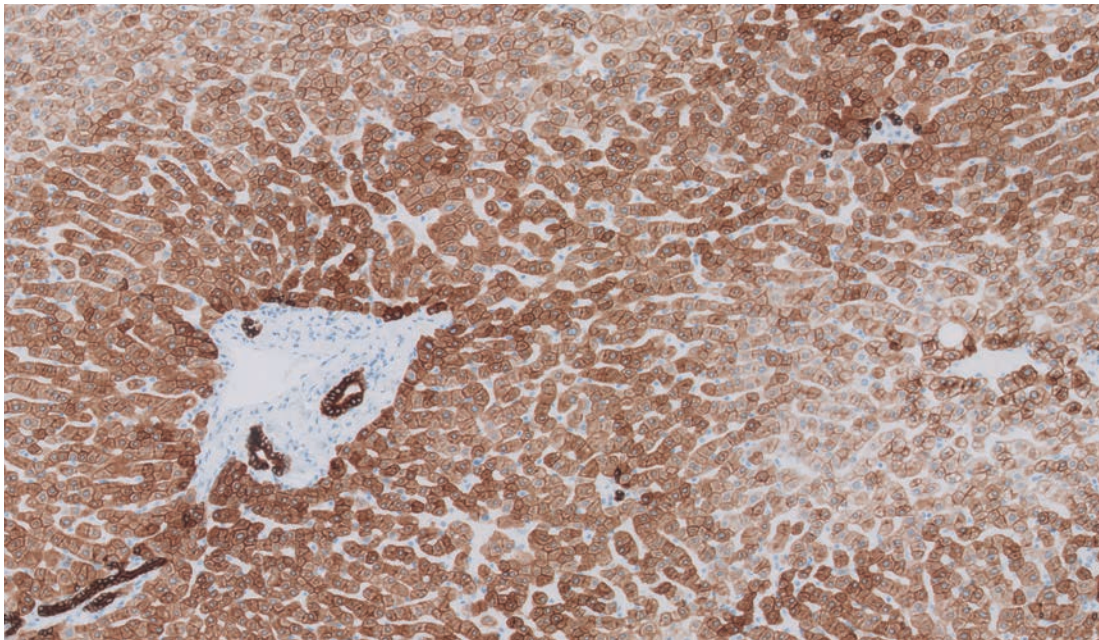


Breast hyperplasia (20x)

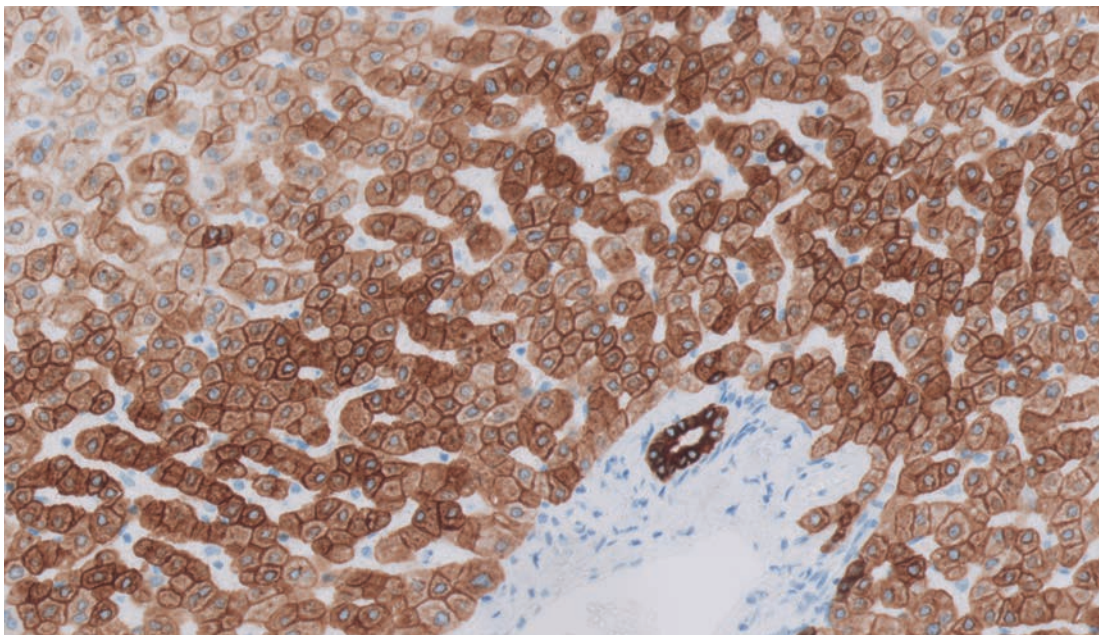
**Antibody:** Monoclonal Mouse Anti-Human  
**Clone:** Cytokeratin 18  
**Code:** DC10  
 GA618 | IR618

Reaction Location	Membrane and cytoplasm
Quality Control	Liver
High Expression	Epithelial cells of the bile ducts show a moderate to strong staining reaction.
Low Expression	Membranes of hepatocytes show a weak to moderate staining reaction.
Non-expression	Kupffer cells.

Note: The staining reaction can be heterogeneous with the strongest staining reaction in the periportal zones.



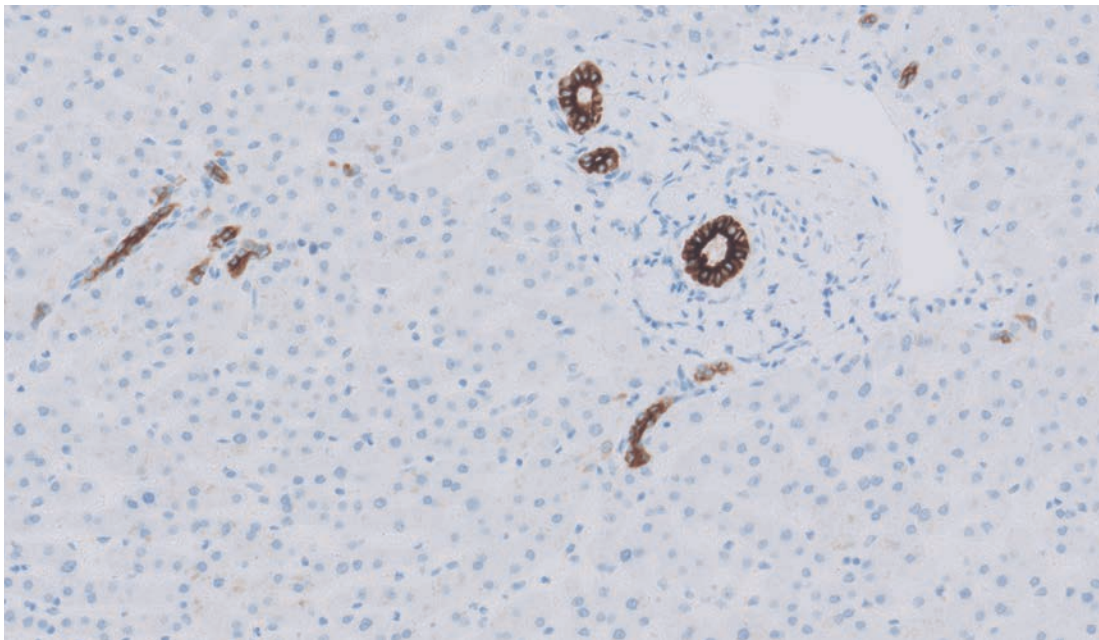
Liver (10x)



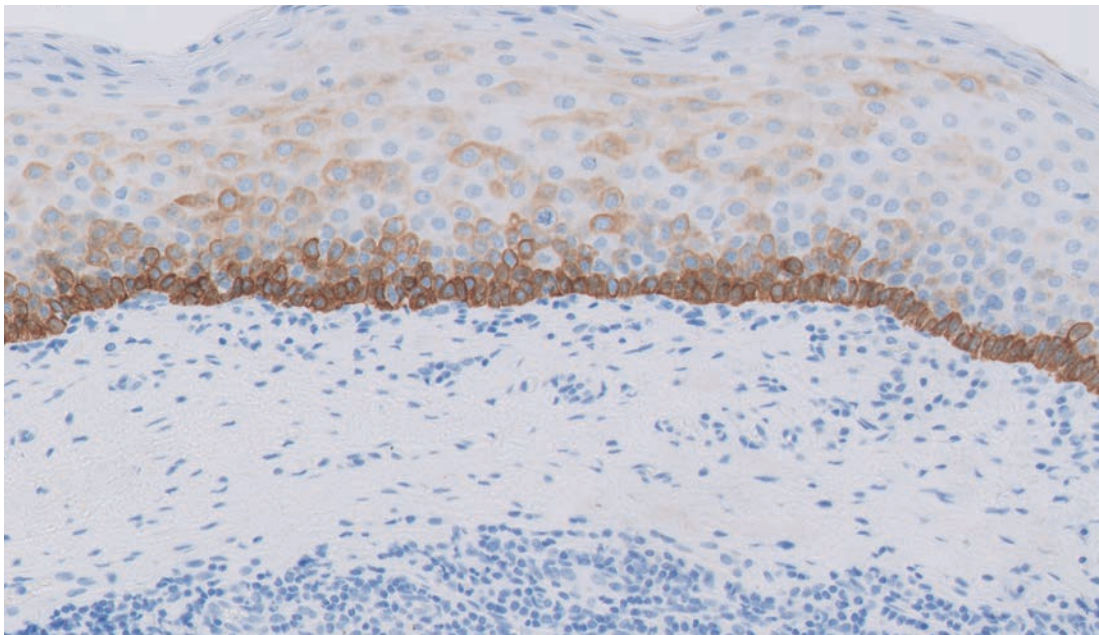
Liver (20x)

**Antibody:** Monoclonal Mouse Anti-Human  
**Clone:** Cytokeratin 19  
**Code:** RCK108  
 GA615 | IR615

Reaction Location	Cytoplasm	
Quality Control	Liver	Tonsil
High Expression	Epithelial cells of bile ducts show a moderate to strong staining reaction.	NA
Low Expression	NA	Squamous epithelial cells focally show a weak to moderate staining reaction that is strongest in the basal layer.
Non-expression	Hepatocytes	NA



Liver (10x)

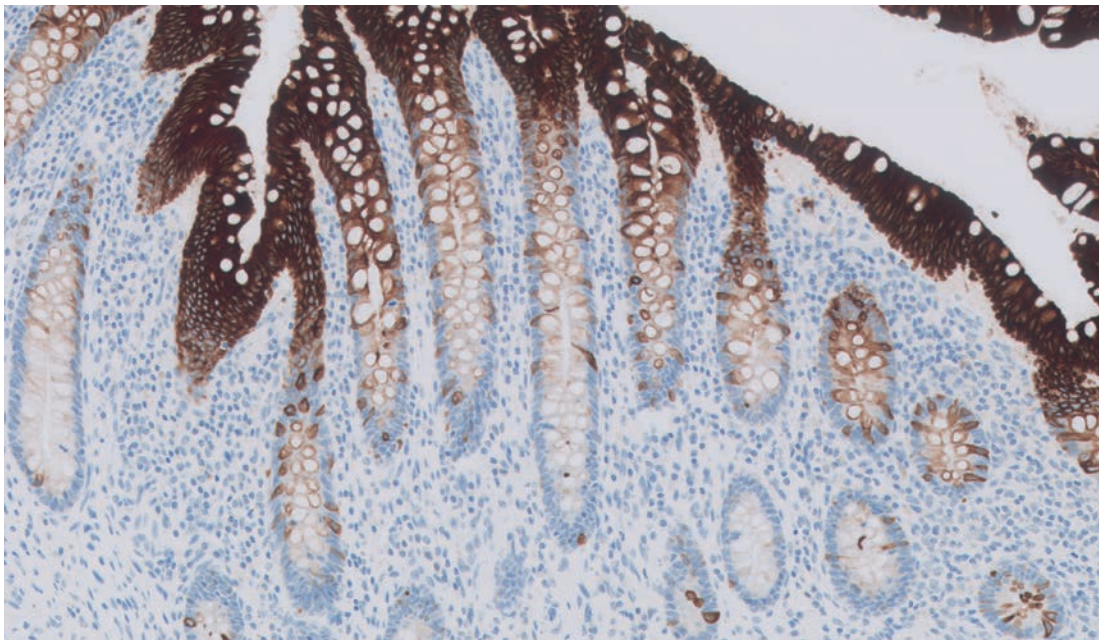


Tonsil (20x)

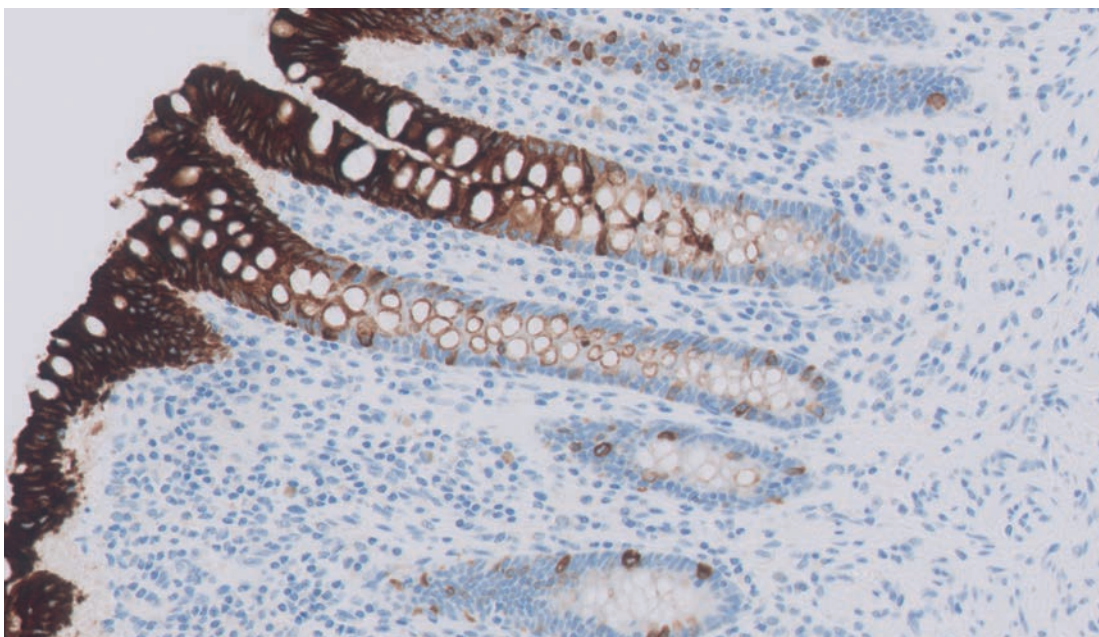
**Antibody:** Monoclonal Mouse Anti-Human  
**Clone:** Cytokeratin 20  
**Code:** Ks20.8  
 GA777 | IR777

Reaction Location	Cytoplasm
Quality Control	Colon/Appendix
High Expression	In columnar epithelium, the luminal cells show a moderate to strong staining reaction.
Low Expression	Basal to intermediate cells show a weak to moderate staining reaction.
Non-expression	NA

Note: Endocrine cells in basal crypts should show a moderate to strong staining reaction.



Appendix (10x)

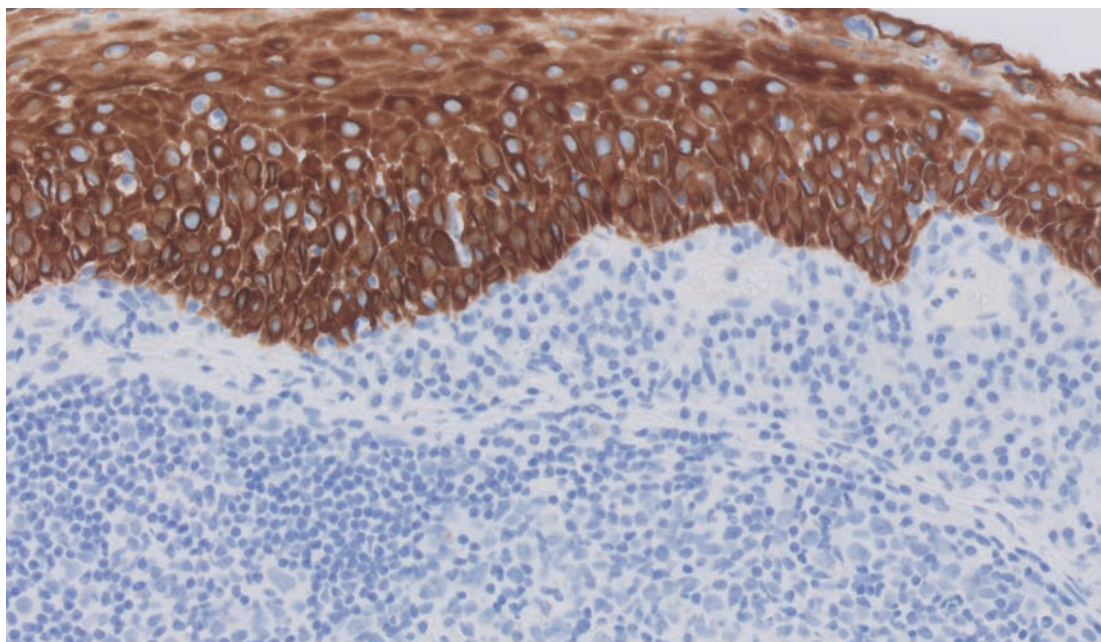


Appendix (20x)

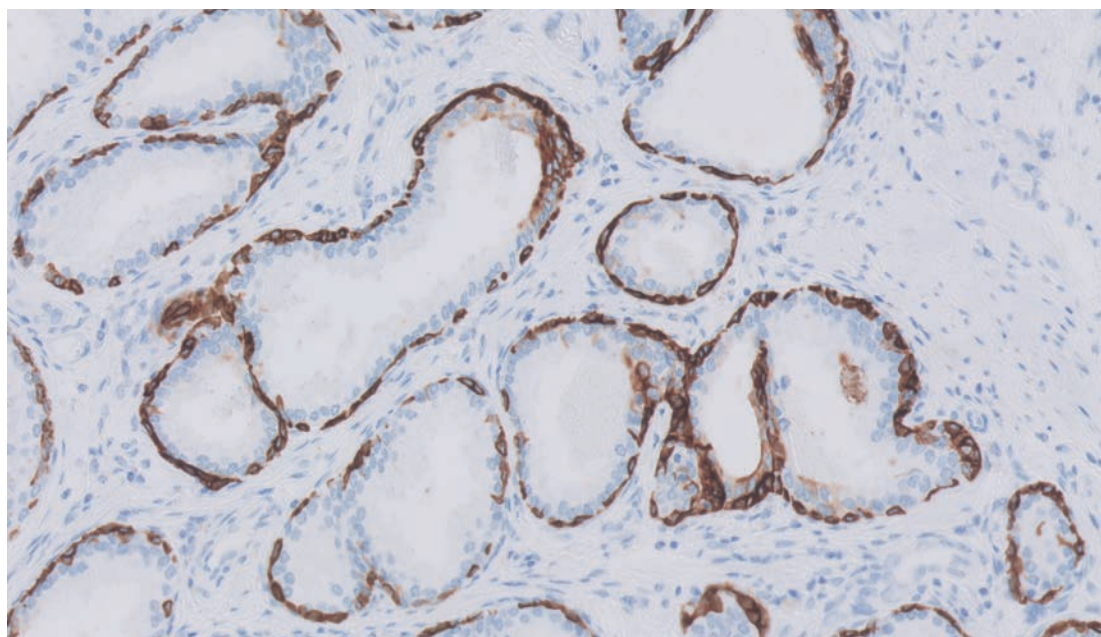
**Antibody:** Monoclonal Mouse Anti-Human  
**Clone:** Cytokeratin, High Molecular Weight  
**Code:** 34βE12  
 GA051 | IR051

Reaction Location	Cytoplasm	
Quality Control	Tonsil	Prostate
High Expression	Squamous epithelial cells show a moderate to strong staining reaction.	Basal cells show a strong cytoplasmic staining reaction with no or only focal reaction in the secretory cells.
Low Expression	NA	NA
Non-expression	NA	NA

Note: The staining reaction is seen in all cell layers in the epithelial surface.



Tonsil (20x)

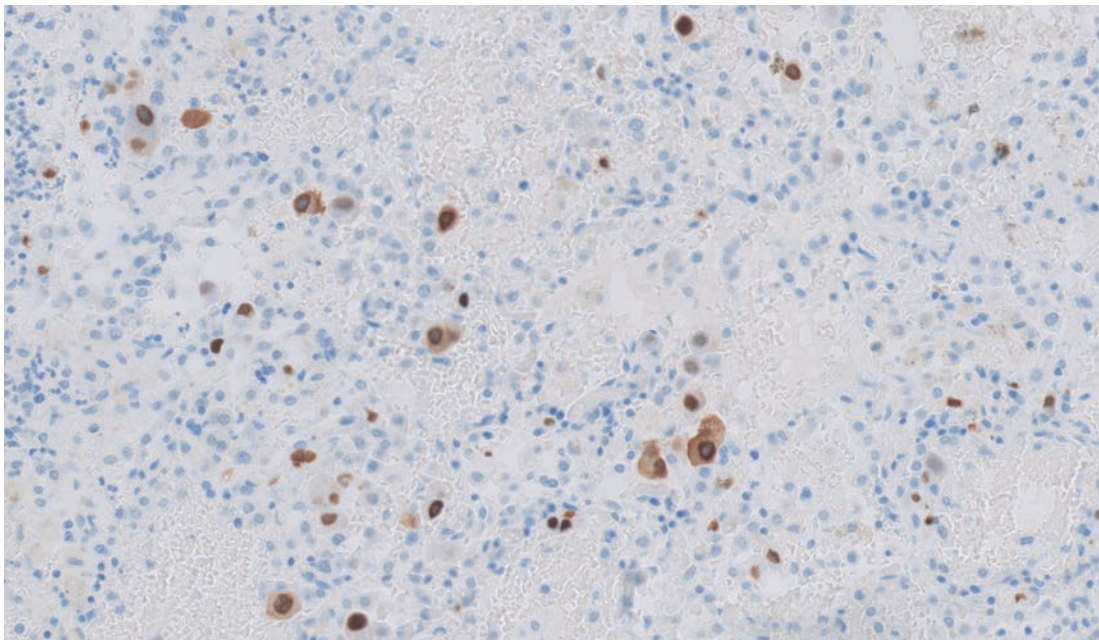


Prostate (20x)

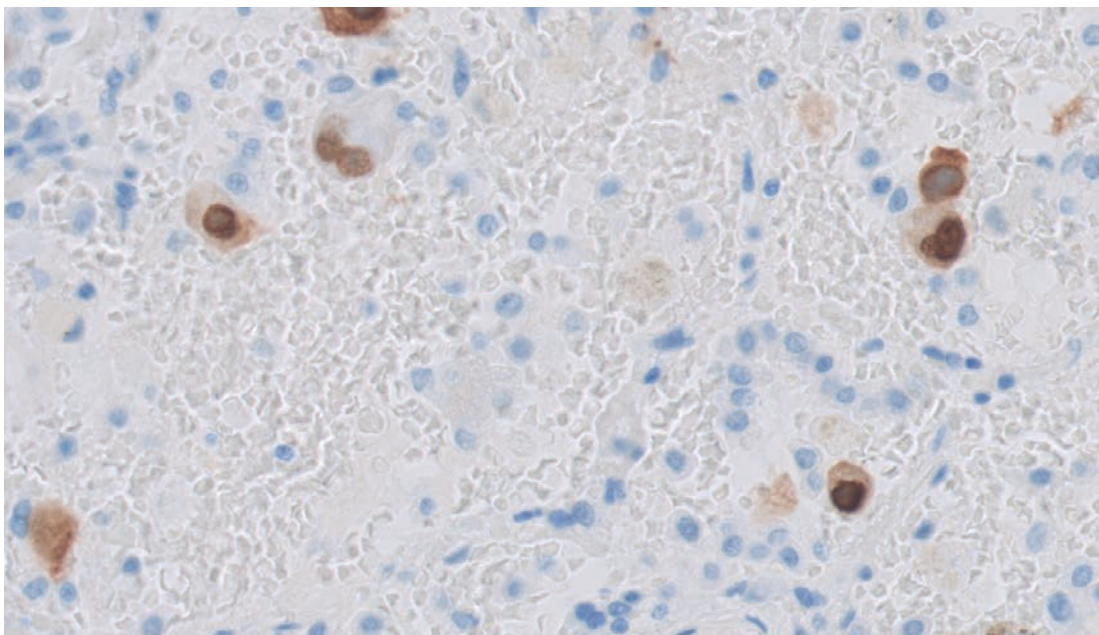
**Antibody:** Monoclonal Mouse Anti-  
**Cytomegalovirus**  
**Clone:** CCH2 + DDG9  
**Code:** GA752 | IR752 *Not available in the US*

Reaction Location	Nucleus and cytoplasm
Quality Control	<b>Cytomegalovirus-infected tissue</b>
High Expression	Cells infected with cytomegalovirus show a moderate to strong staining reaction.
Low Expression	NA
Non-expression	NA

Note: No background staining should be seen.



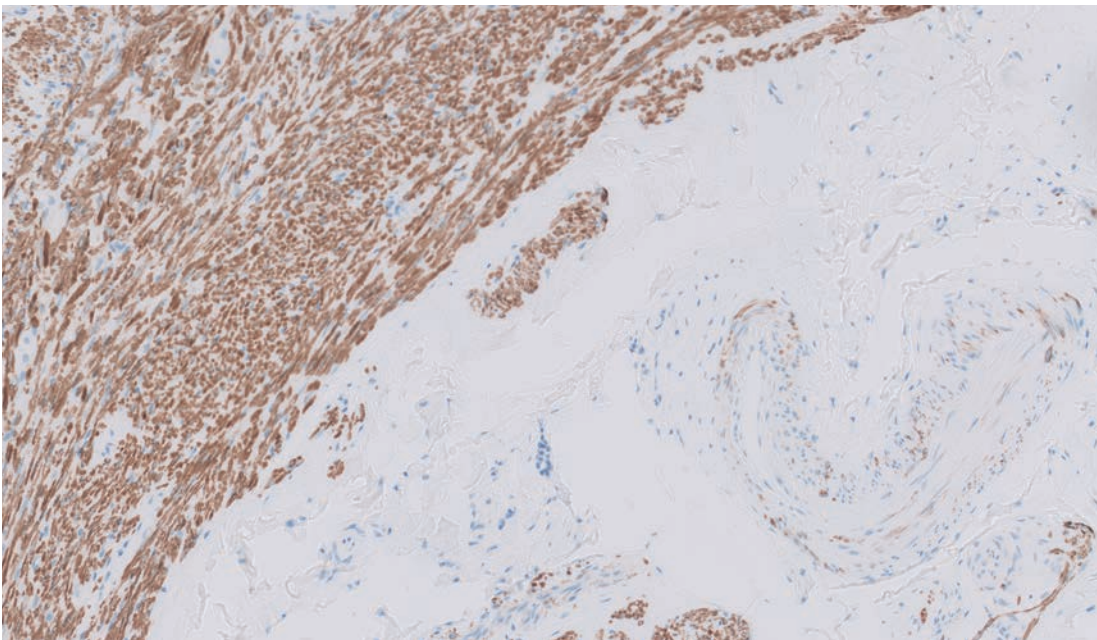
Cytomegalovirus-infected tissue (20x)



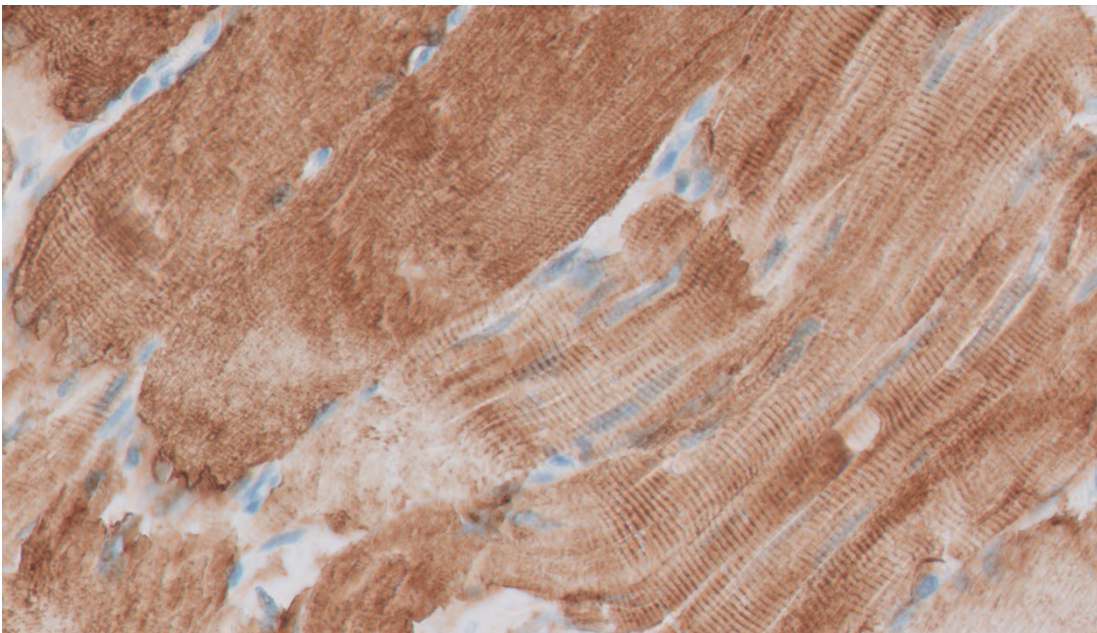
Cytomegalovirus-infected tissue (40x)

**Antibody:** Monoclonal Mouse Anti-Human  
**Clone:** Desmin  
**Code:** D33  
**Code:** IR606

Reaction Location	Cytoplasm	
Quality Control	Colon/Appendix	Striated muscle
High Expression	Smooth muscle cells in the tunica muscularis show a moderate to strong staining reaction.	Muscle cells in the Z-bands show strong staining reaction.
Low Expression	Smooth muscle cells in the small vessels in the lamina propria show a weak to moderate staining reaction.	NA
Non-expression	Columnar epithelial cells.	NA



Appendix (10x)

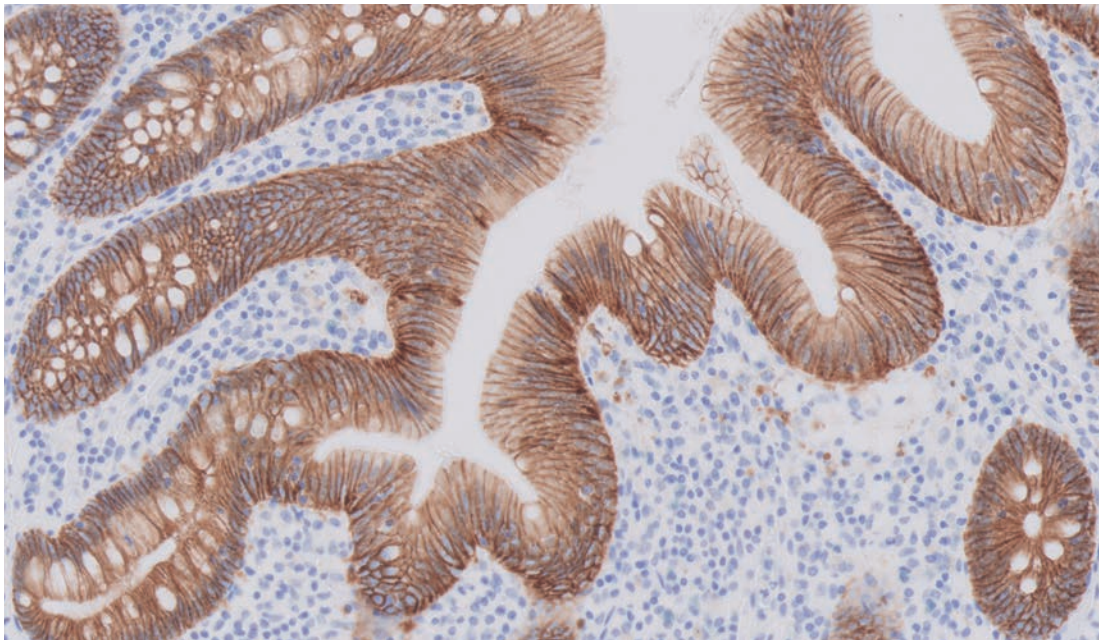


Striated muscle (40x)

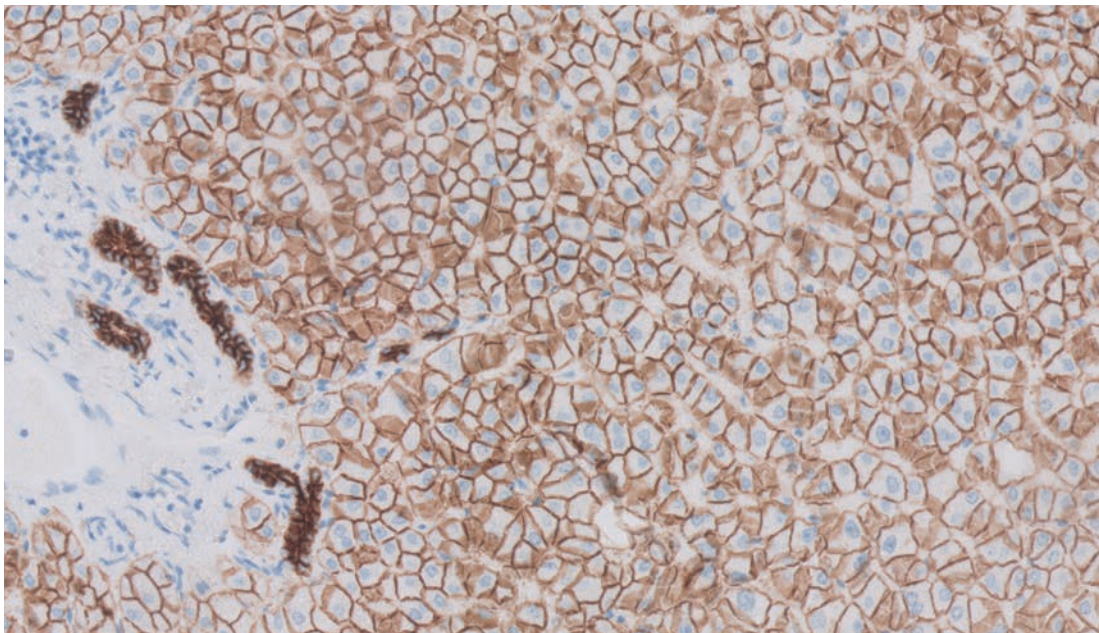


**Antibody:** Monoclonal Mouse Anti-Human  
**Clone:** E-Cadherin  
**Code:** NCH-38  
 GA059 | IR059

Reaction Location	Membrane	
Quality Control	Colon/Appendix	Liver
High Expression	Columnar epithelial cells show a moderate to strong staining reaction.	Bile ductal cells show a moderate to strong reaction.
Low Expression	NA	Hepatocytes show at least weak to moderate staining reaction.
Non-expression	NA	NA



Appendix (20x)



Liver (20x)

Antibody:

Monoclonal Mouse Anti-Human  
Epithelial Antigen

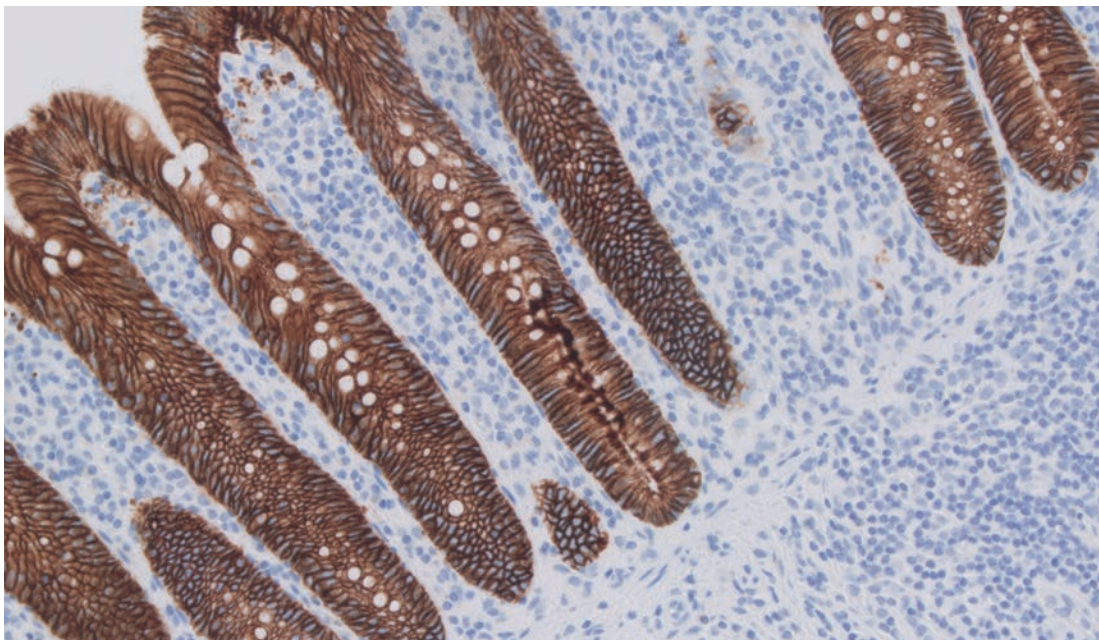
Clone:

Ber-EP4

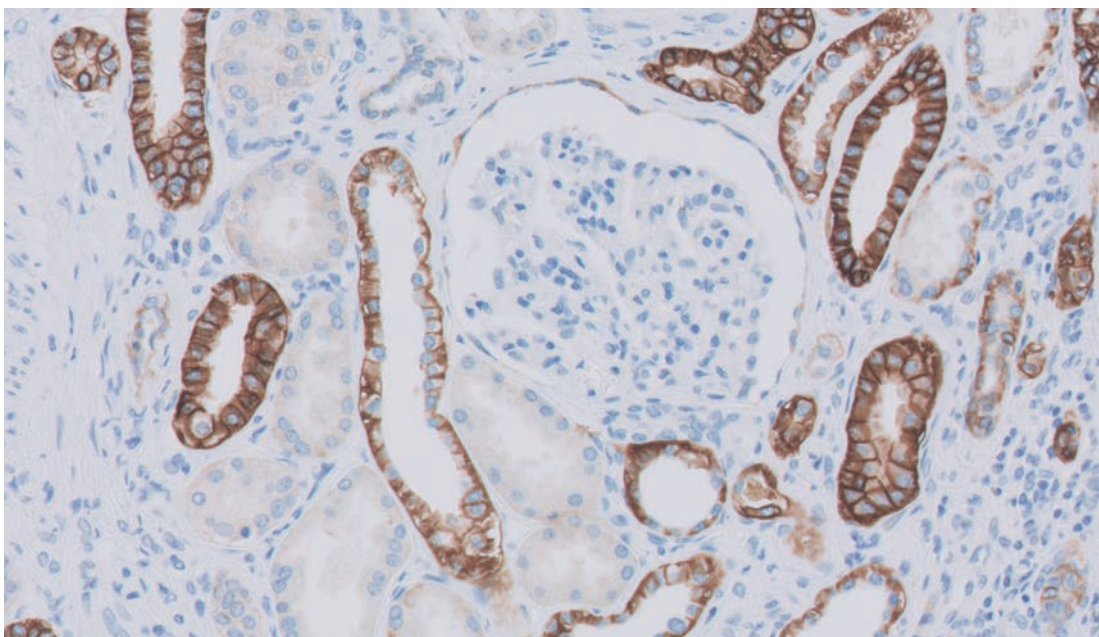
Code:

GA637 | IR637

Reaction Location		Membrane and cytoplasm	
Quality Control	Colon/Appendix	Kidney	
High Expression	Columnar epithelial cells show a moderate to strong staining reaction.	Epithelial cells in the collecting ducts and distal tubules show a moderate to strong staining reaction.	
Low Expression	NA	Epithelial cells lining the bowman capsule show a weak to moderate staining reaction.	
Non-expression	Lymphocytes, apart from cytoplasmic staining reaction in macrophages in lamina propria.	NA	



Appendix (20x)

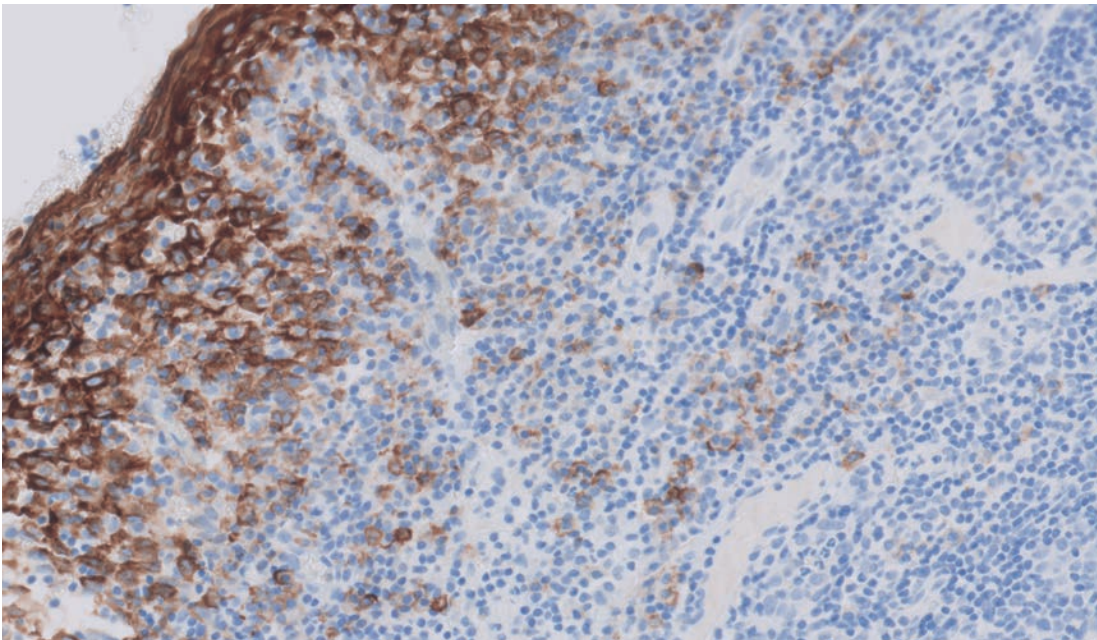


Kidney (20x)

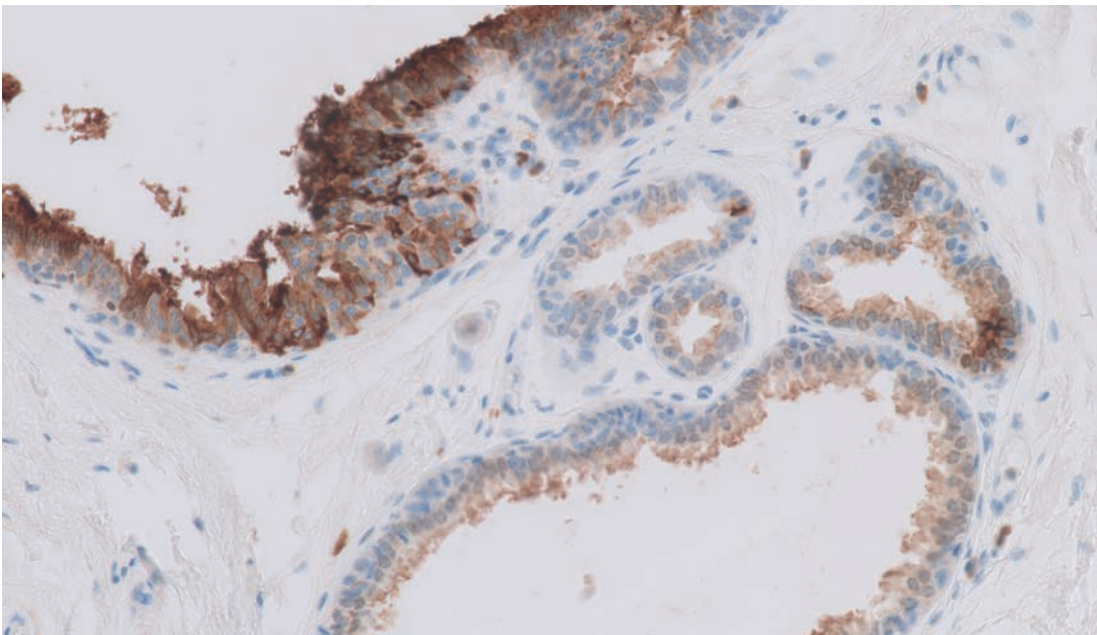
**Antibody:** Monoclonal Mouse Anti-Human  
**Clone:** Epithelial Membrane Antigen  
**Code:** E29  
 GA629 | IR629

Reaction Location	Membrane and cytoplasm	
Quality Control	Tonsil	Breast
High Expression	Squamous epithelial cells show a moderate to strong cytoplasmic staining reaction.	Ductal epithelial cells show a moderate to strong membranous staining reaction.
Low Expression	Plasma cells show a weak to moderate staining reaction.	NA
Non-expression	NA	NA

Note: A granular cytoplasmic staining reaction can also be observed.



Tonsil (20x)

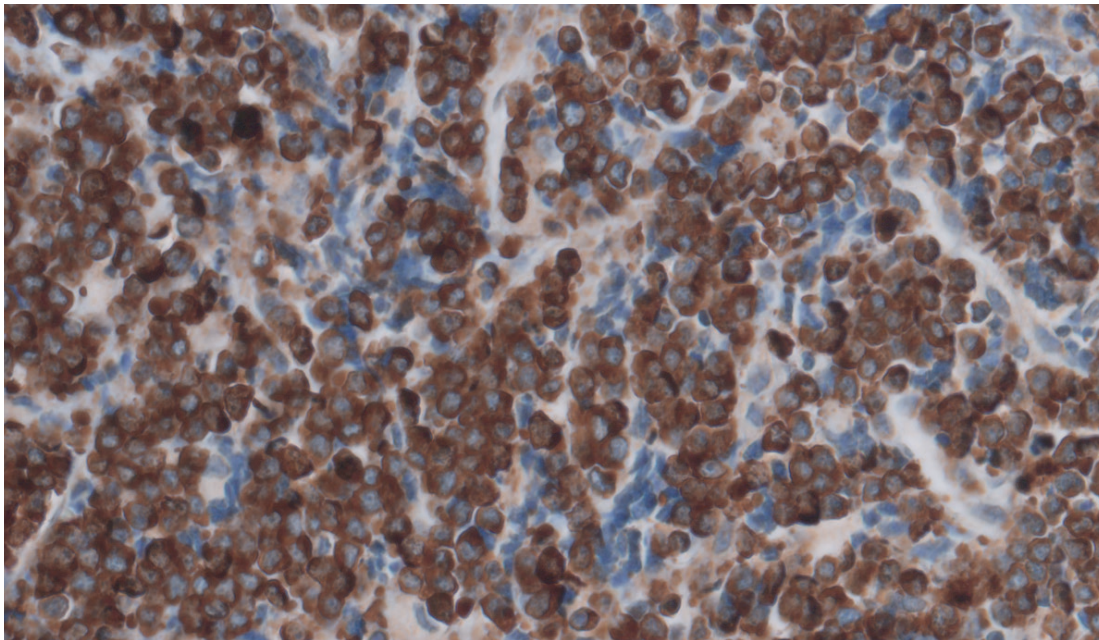


Breast (20x)

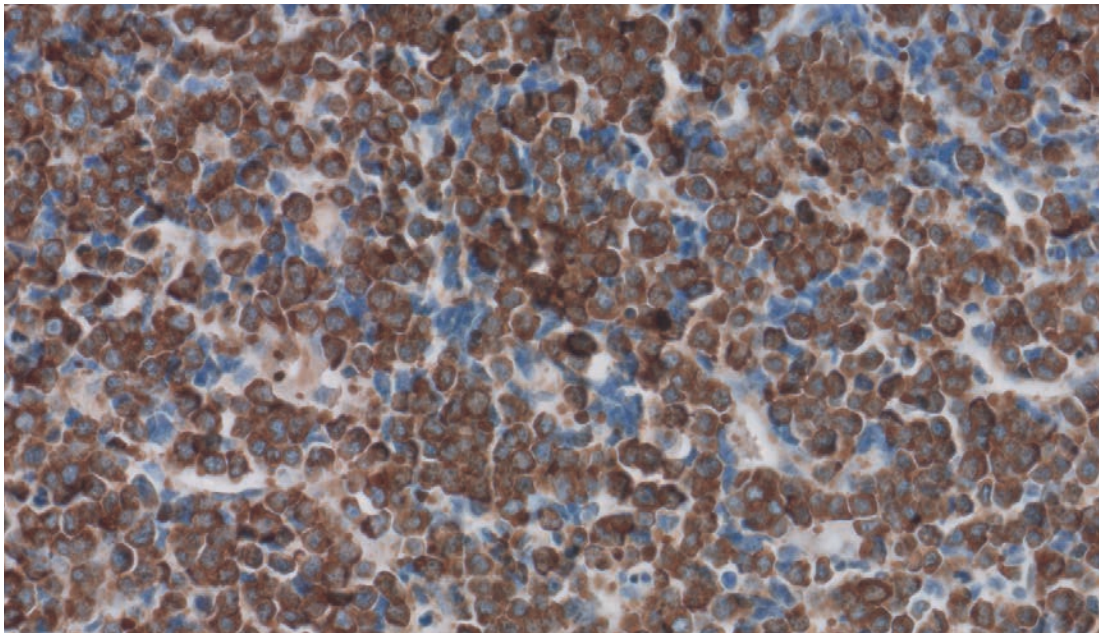
**Antibody:** Monoclonal Mouse Anti-Epstein-Barr Virus, LMP  
**Clone:** CS.1-4  
**Code:** IR753 *Not available in the US*

Reaction Location	Membrane and cytoplasm
Quality Control	<b>Burkitt lymphoma/leukemia (EBV+)</b>
High Expression	Neoplastic cells show a moderate to strong predominantly membranous, but also cytoplasmic staining reaction.
Low Expression	NA
Non-expression	NA

Note: Occasionally, the staining reaction shows a dot-like pattern.



Burkitt lymphoma (40x)

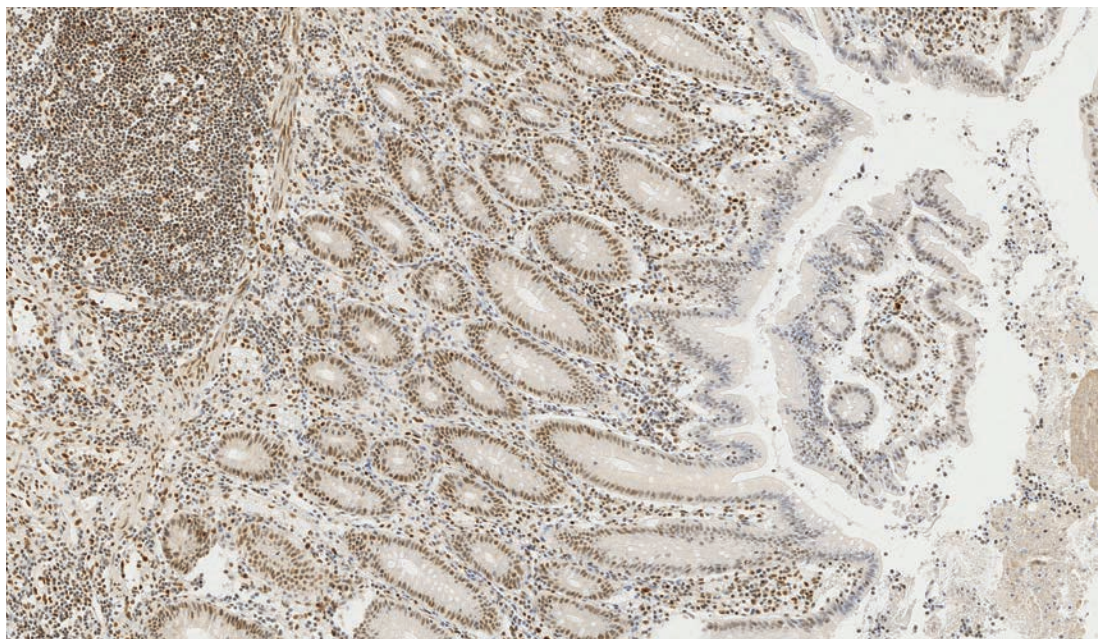


Burkitt lymphoma (40x)

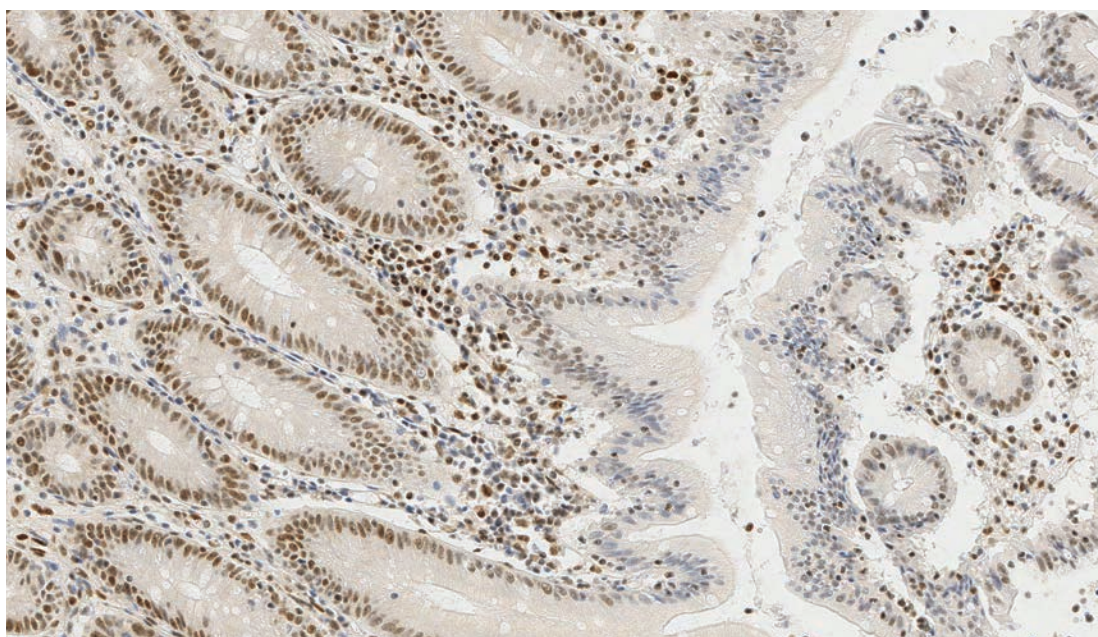
**Antibody:** Monoclonal Mouse Anti-Human ERCC1  
**Clone:** 4F9  
**Code:** IR091

Reaction Location	Nucleus
Quality Control	Colon/Appendix
High Expression	Glandular epithelium, lymphocytes and stromal cells show a moderate to strong staining reaction.
Low Expression	NA
Non-expression	NA

Note: Cytoplasmic staining in the presence of nuclear staining may also be observed.



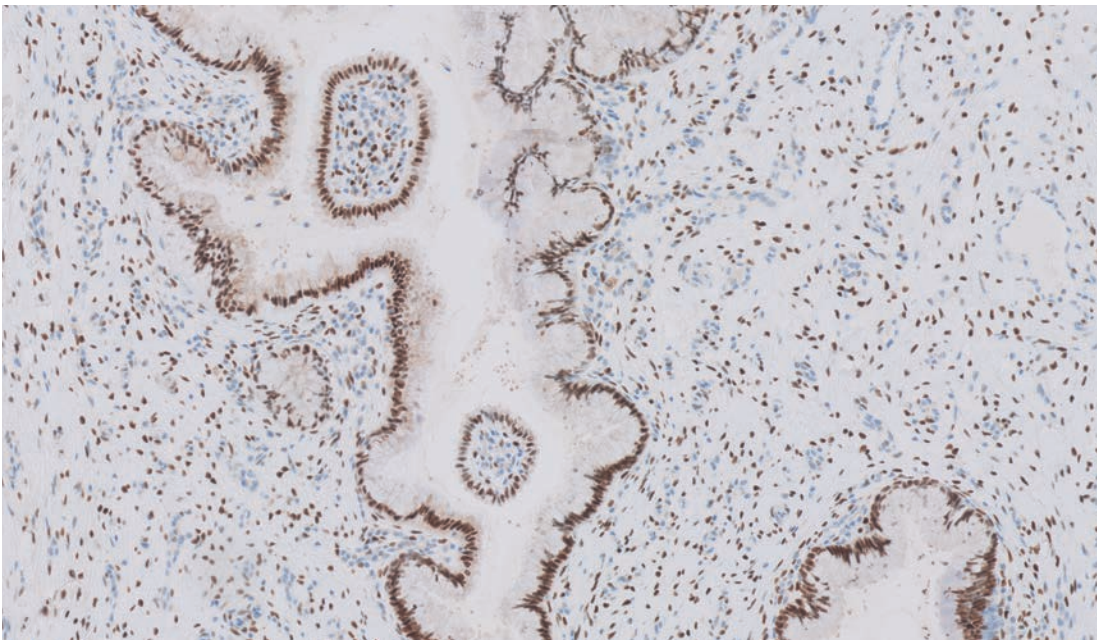
Appendix (10x)



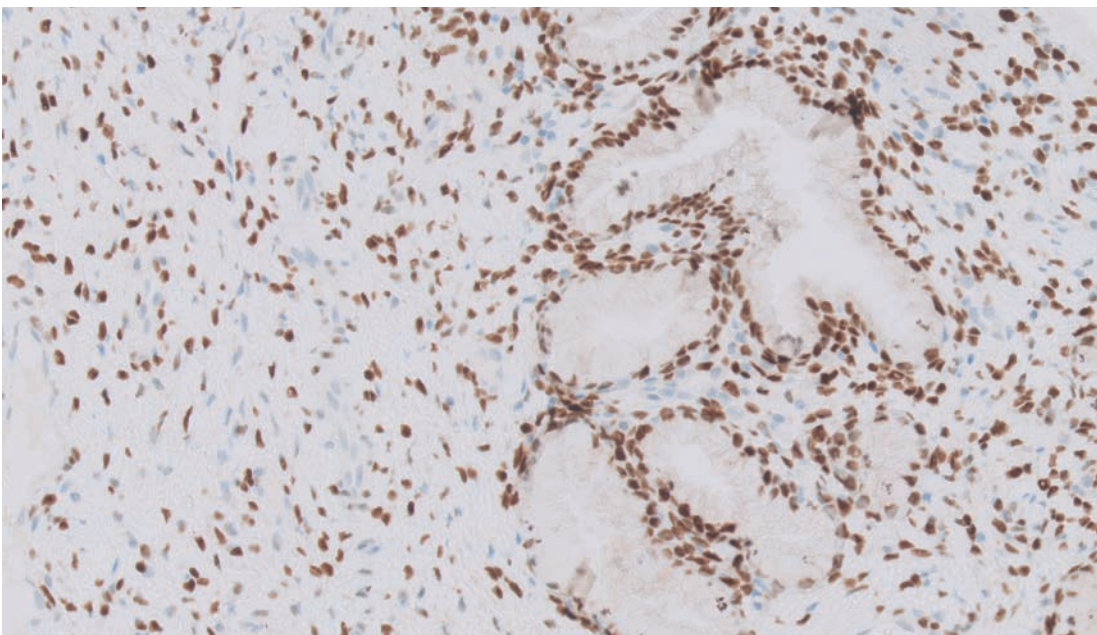
Appendix (20x)

**Antibody:** Monoclonal Mouse Anti-Human  
**Estrogen Receptor  $\alpha$**   
**Clone:** 1D5  
**Code:** IR657 *Not available in the US*

Reaction Location	Nucleus
Quality Control	<b>Cervix</b>
High Expression	Columnar epithelial cells and stromal cells show a moderate to strong staining reaction.
Low Expression	Intermediate and superficial squamous epithelial cells show a weak to moderate staining reaction.
Non-expression	Endothelial cells and lymphocytes.



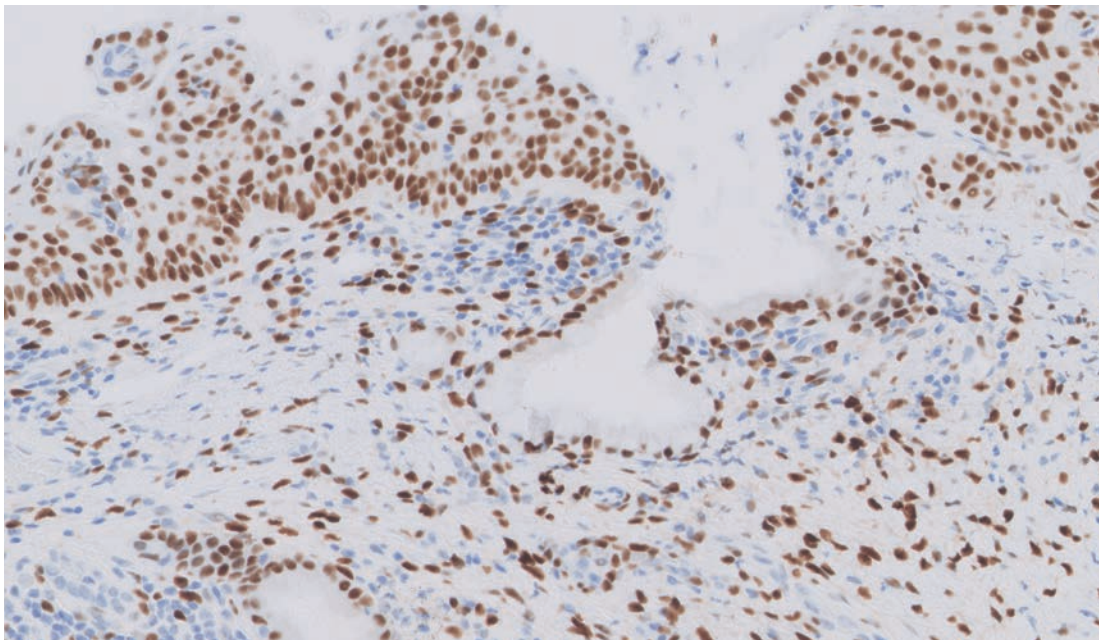
Cervix (10x)



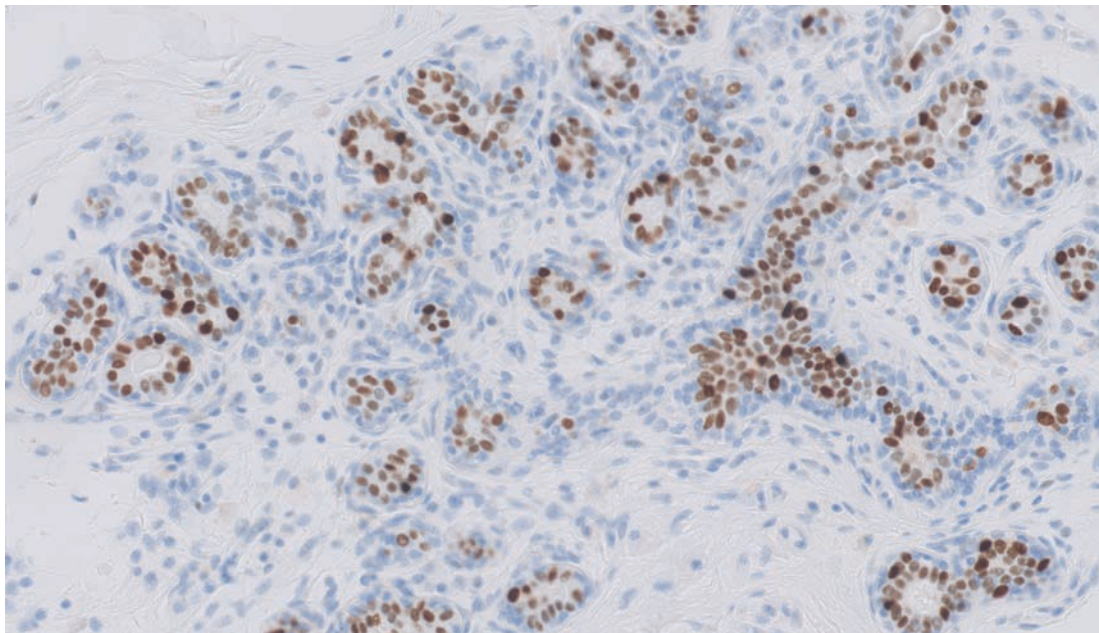
Cervix (20x)

**Antibody:** Monoclonal Rabbit Anti-Human  
**Clone:** Estrogen Receptor  $\alpha$   
**Code:** EP1  
 GA084 | IR084

Reaction Location	Nucleus	
Quality Control	Cervix	Breast hyperplasia
High Expression	Columnar epithelial cells and stromal cells show a moderate to strong staining reaction.	The neoplastic cells show a weak to strong staining reaction.
Low Expression	Intermediate and superficial squamous epithelial cells show a weak to moderate staining reaction.	The neoplastic cells show a weak to strong staining reaction.
Non-expression	Endothelial cells and lymphocytes.	NA



Cervix (20x)

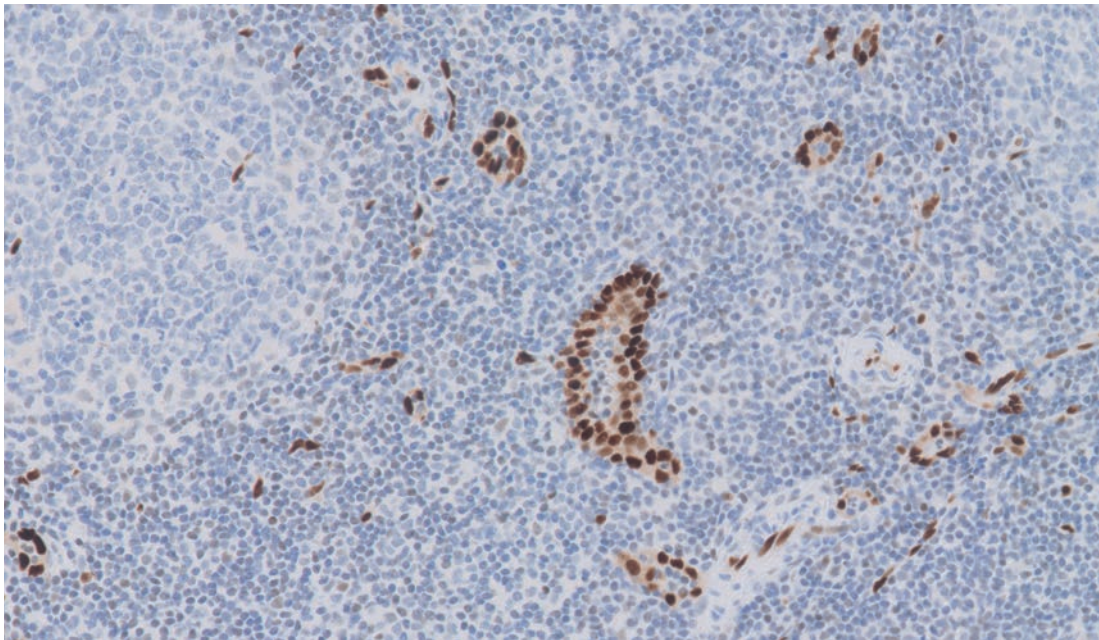


Breast hyperplasia (20x)

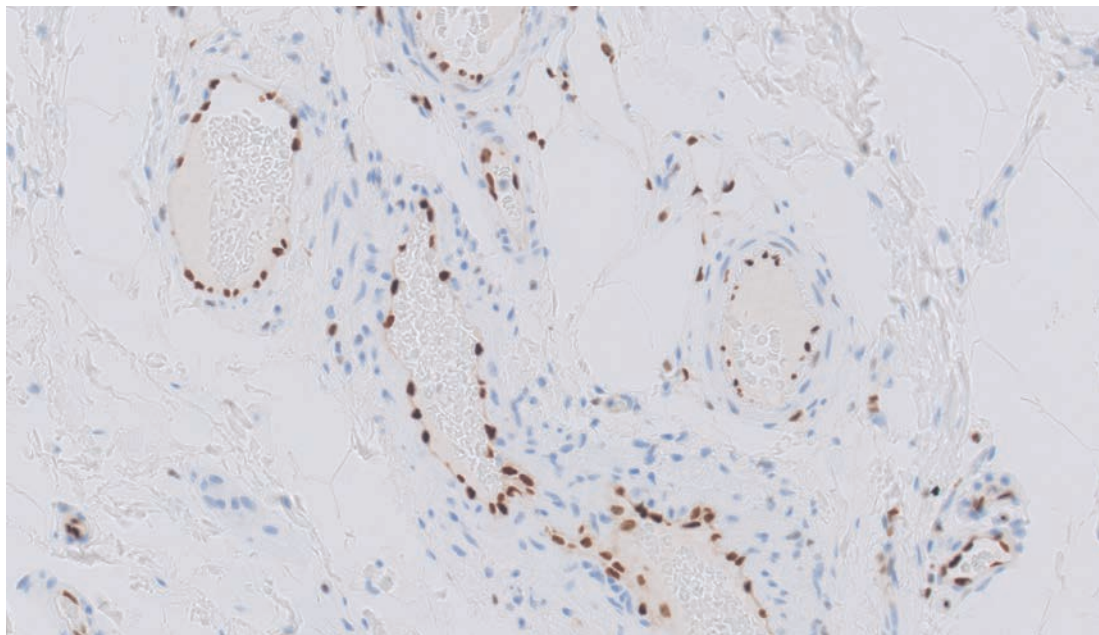
**Antibody:** Monoclonal Rabbit Anti-Human  
**Clone:** Ets-Related Gene (ERG)  
**Code:** EP111  
 GA659 | IR659

Reaction Location	Nucleus	
Quality Control	Tonsil	Colon/Appendix
High Expression	Endothelial cells show a moderate to strong staining reaction.	Endothelial cells show a moderate to strong staining reaction.
Low Expression	NA	NA
Non-expression	NA	NA

Note: Peripheral lymphocytes may show a weak staining reaction.



Tonsil (20x)



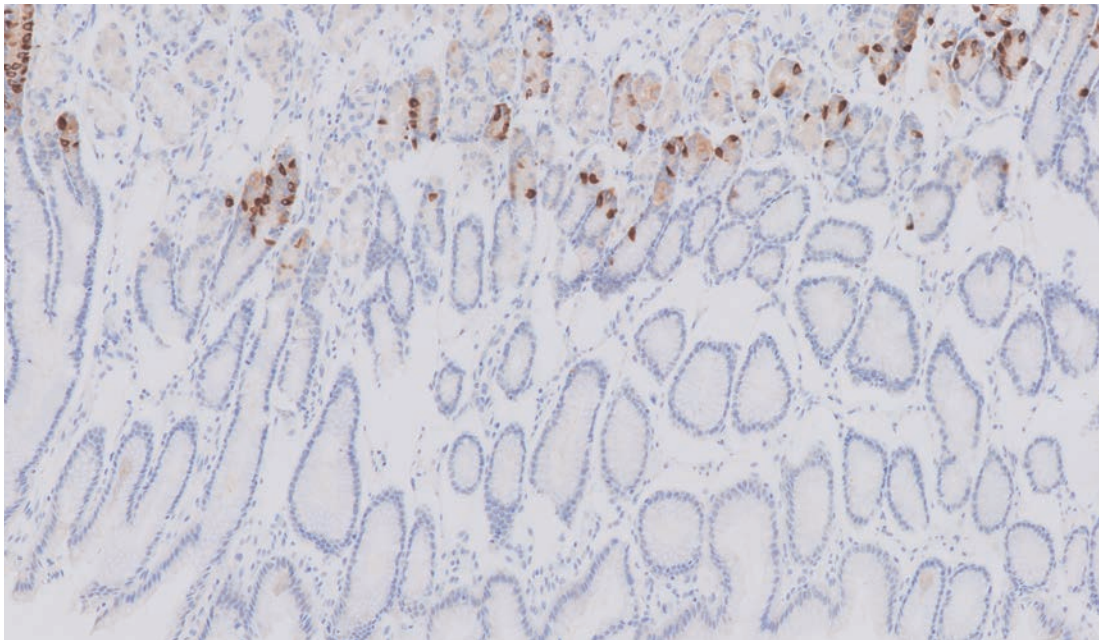
Colon (20x)



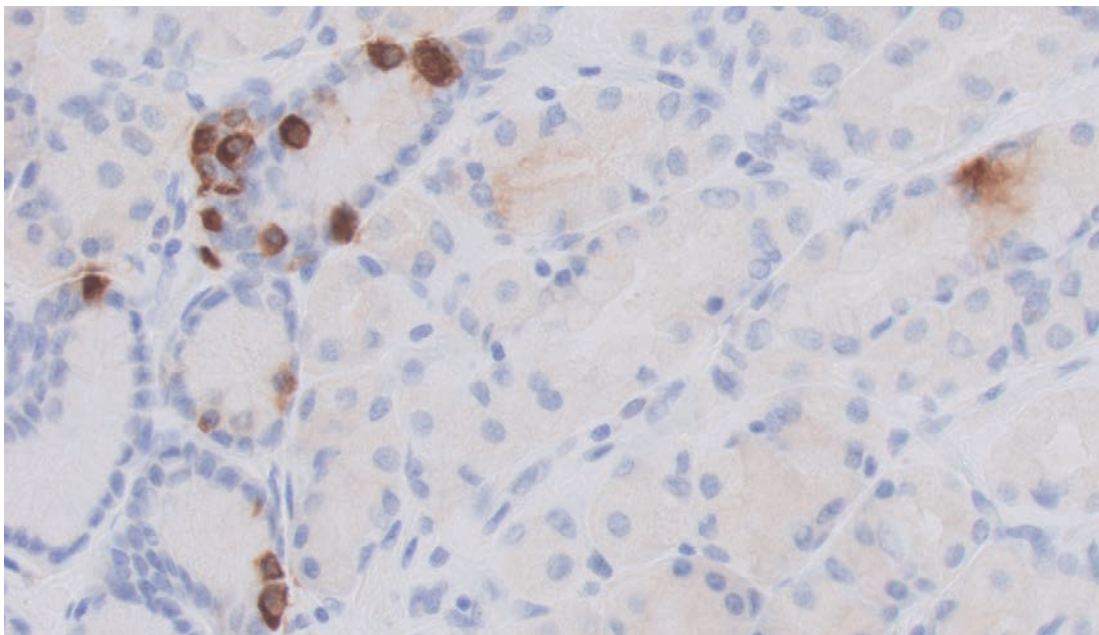
**Antibody:** Polyclonal Rabbit Anti-Human  
**Clone:** Gastrin  
**Code:** Polyclonal  
GA519 | IR519

Reaction Location	Cytoplasm
Quality Control	Stomach
High Expression	G cells in the pyloric antrum show moderate to strong staining reaction.
Low Expression	NA
Non-expression	Epithelial cells.

Note: Occasionally, a slightly diffuse background reaction in the vicinity of G cells can be observed.



Stomach (10x)

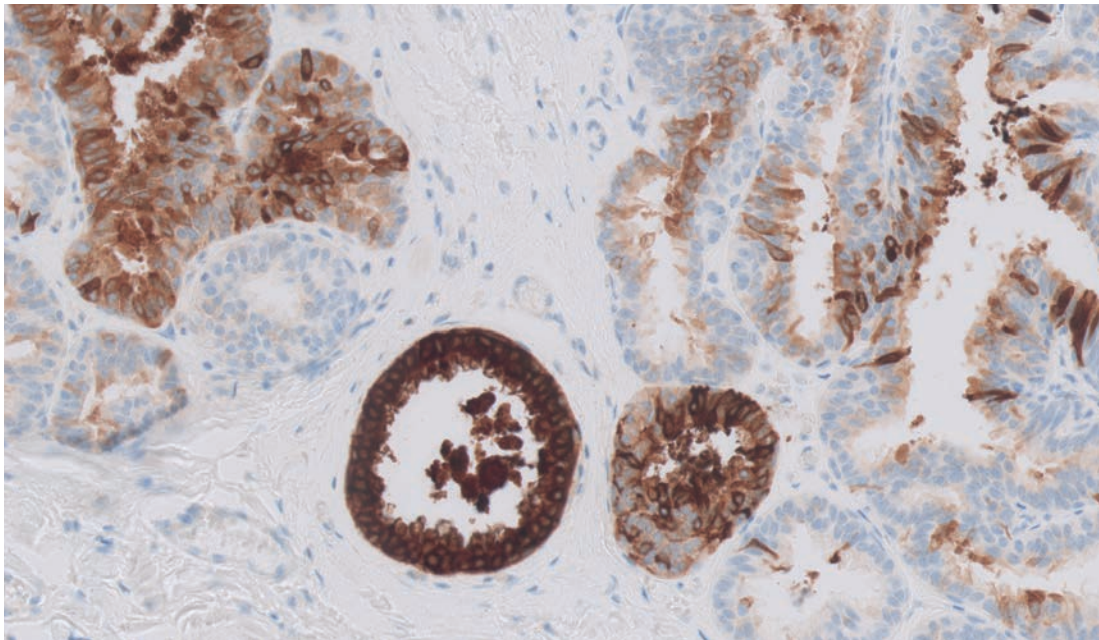


Stomach (40x)

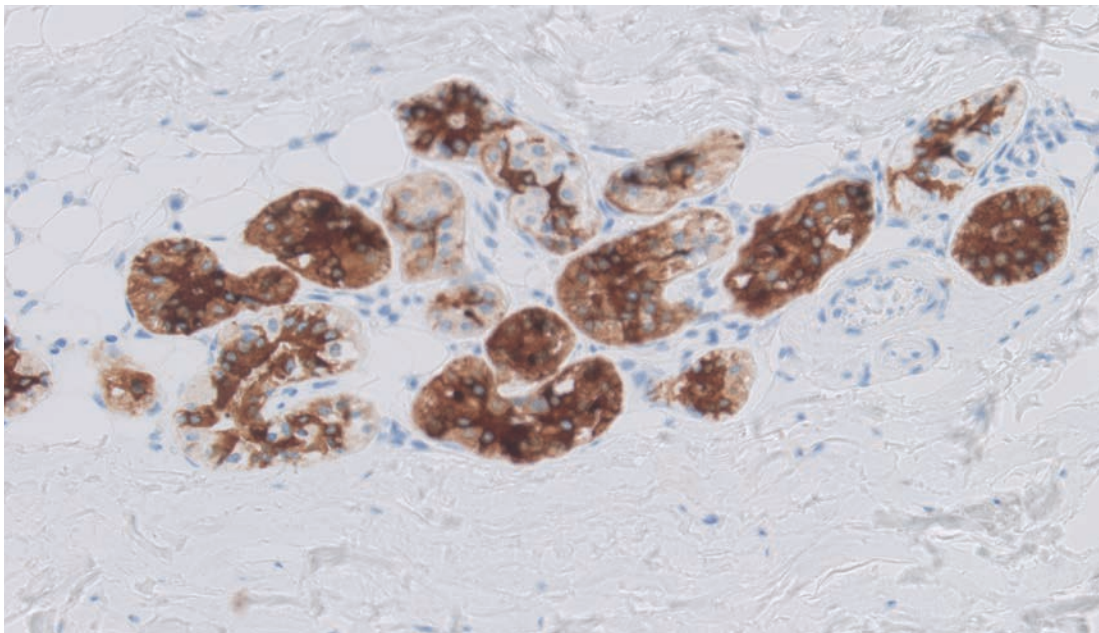
**Antibody:** Monoclonal Mouse Anti-Human  
**Clone:** GCDFP-15  
**Code:** 22A3  
 GA077 | IR077

Reaction Location	Cytoplasm	
Quality Control	Breast hyperplasia	Skin
High Expression	Glandular and ductal epithelial cells show at least a moderate to strong focal staining reaction.	Epithelial cells of the sweat glands show a moderate to strong, at least focally, staining reaction.
Low Expression	NA	NA
Non-expression	NA	Squamous epithelial cells.

Note: A weak background staining can be expected.



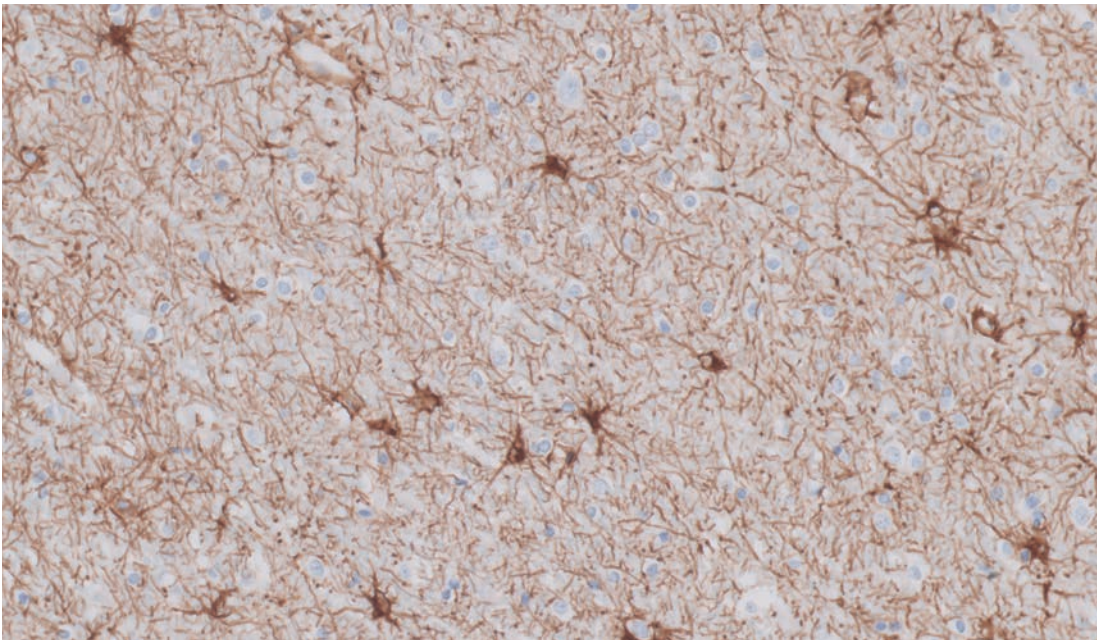
Breast hyperplasia (20x)



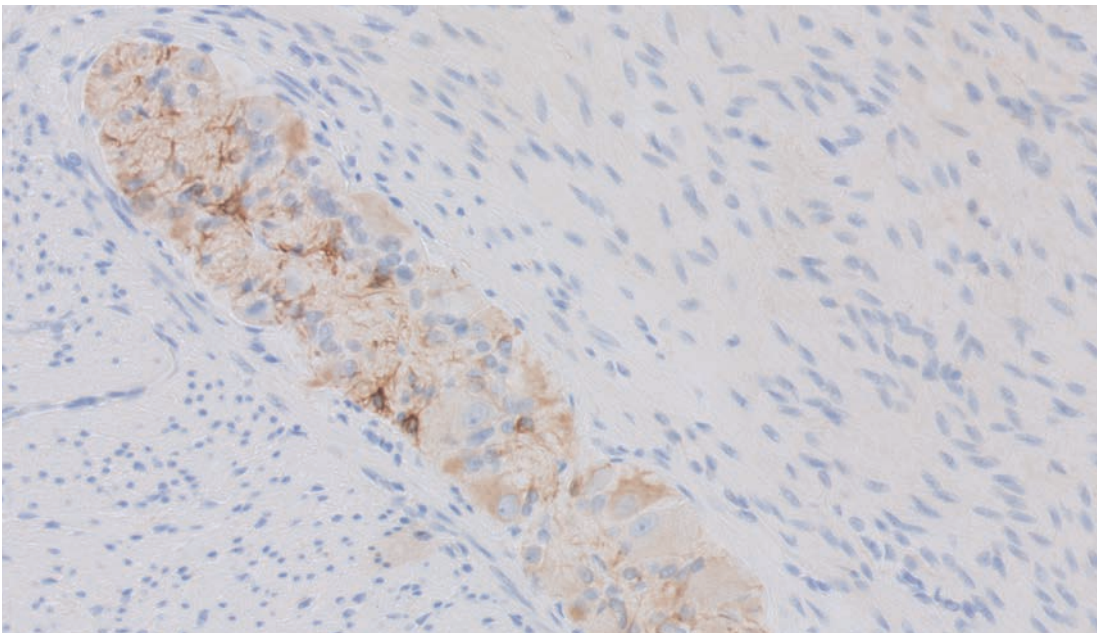
Skin (20x)

**Antibody:** Polyclonal Rabbit Anti-Human  
**Glial Fibrillary Acidic Protein**  
**Clone:** Polyclonal  
**Code:** GA524 | IR524

Reaction Location	Cytoplasm	
Quality Control	Brain	Colon
High Expression	Astrocytes show a moderate to strong staining reaction.	NA
Low Expression	NA	Ganglion cells in the Auerbach's and Meissner's plexus show a weak to moderate staining reaction.
Non-expression	NA	NA



Brain (20x)

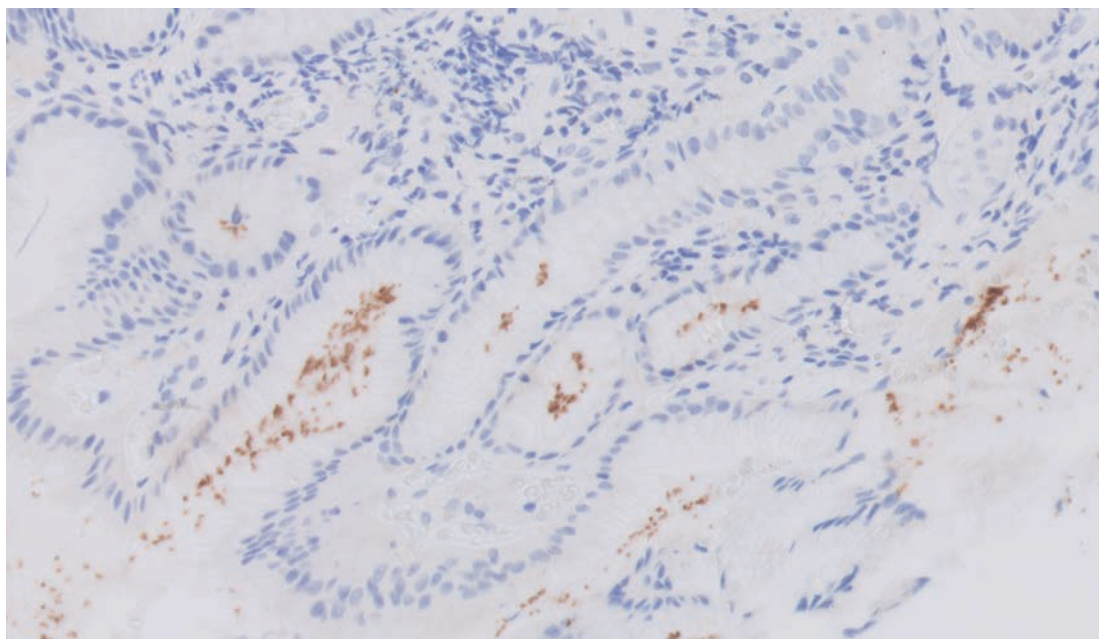


Colon (20x)

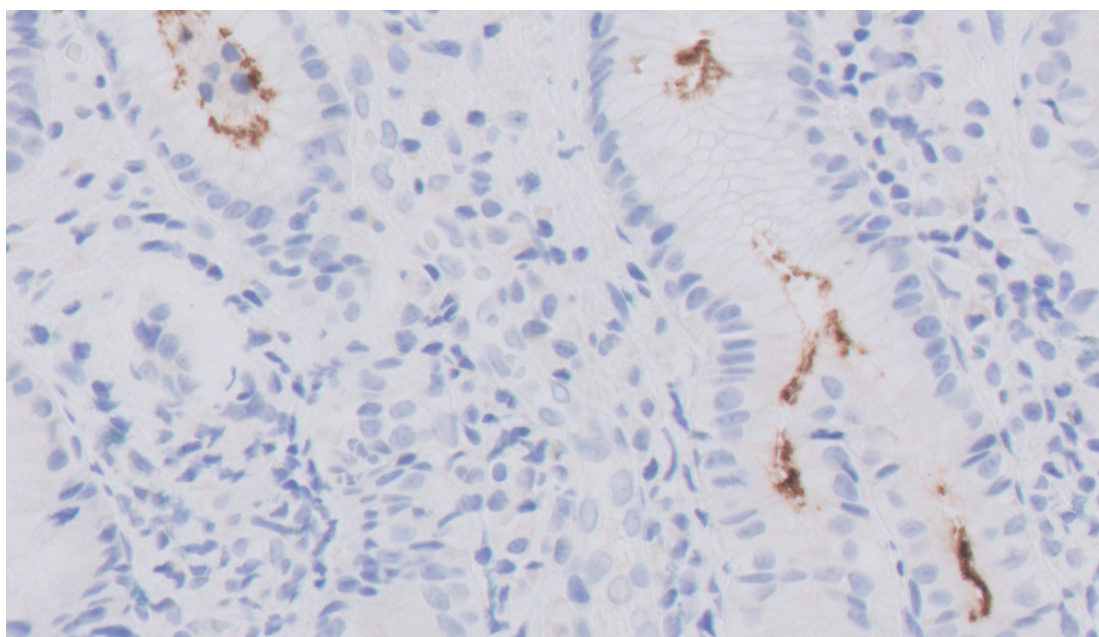
**Antibody:** Polyclonal Rabbit Anti-  
**Helicobacter Pylori**  
**Clone:** Polyclonal  
**Code:** GA523 | IR523 *Not available in the US*

Reaction Location	Bacteria
Quality Control	<b>Gastric mucosa</b>
High Expression	Helicobacter pylori bacteria lining gastric mucosa show a weak to strong staining reaction.
Low Expression	Helicobacter pylori bacteria lining gastric mucosa show a weak to strong staining reaction.
Non-expression	No staining reaction is seen in the epithelial cells. In the lamina propria, scattered macrophages can show a staining reaction.

Note: Precipitates may form in the tissue during the IHC staining procedure, which in some cases can resemble *Helicobacter Pylori* staining. It is therefore essential to always use normal tissue known to be negative for *Helicobacter Pylori* to identify unexpected precipitates.



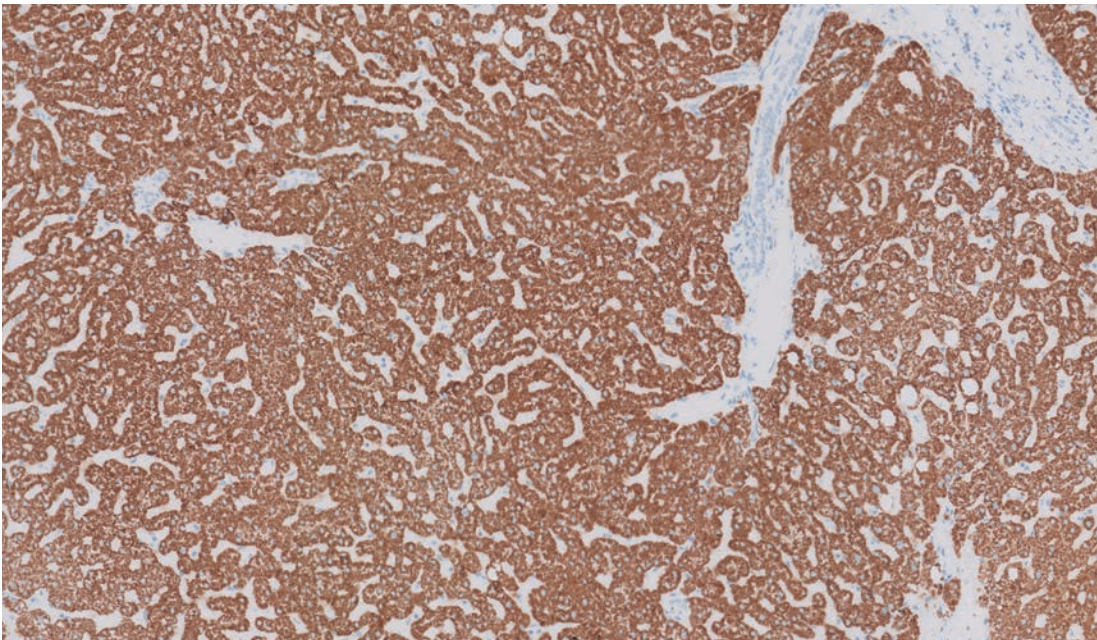
Gastric (20x)



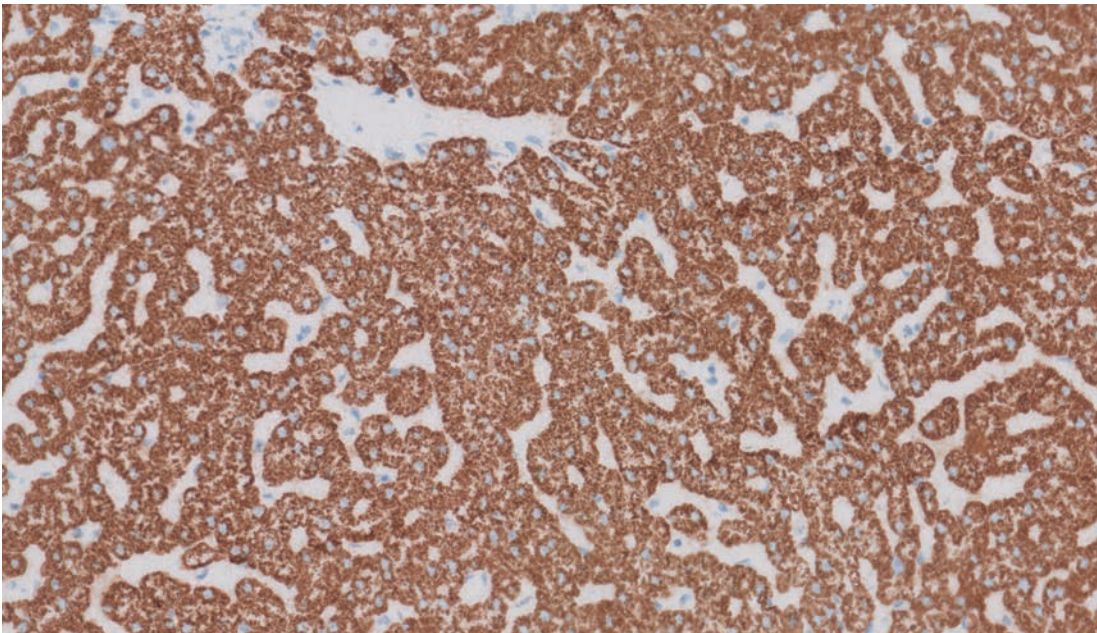
Gastric (40x)

Antibody: Monoclonal Mouse Anti-Human  
Hepatocyte  
Clone: OCH1E5  
Code: GA624 | IR624

Reaction Location	Cytoplasm
Quality Control	Liver
High Expression	Hepatocytes show a moderate to strong staining reaction.
Low Expression	NA
Non-expression	Bile duct epithelial cells.



Liver (10x)



Liver (20x)

Antibody:

Polyclonal Rabbit Anti-  
Herpes Simplex Virus Type 1

Clone:

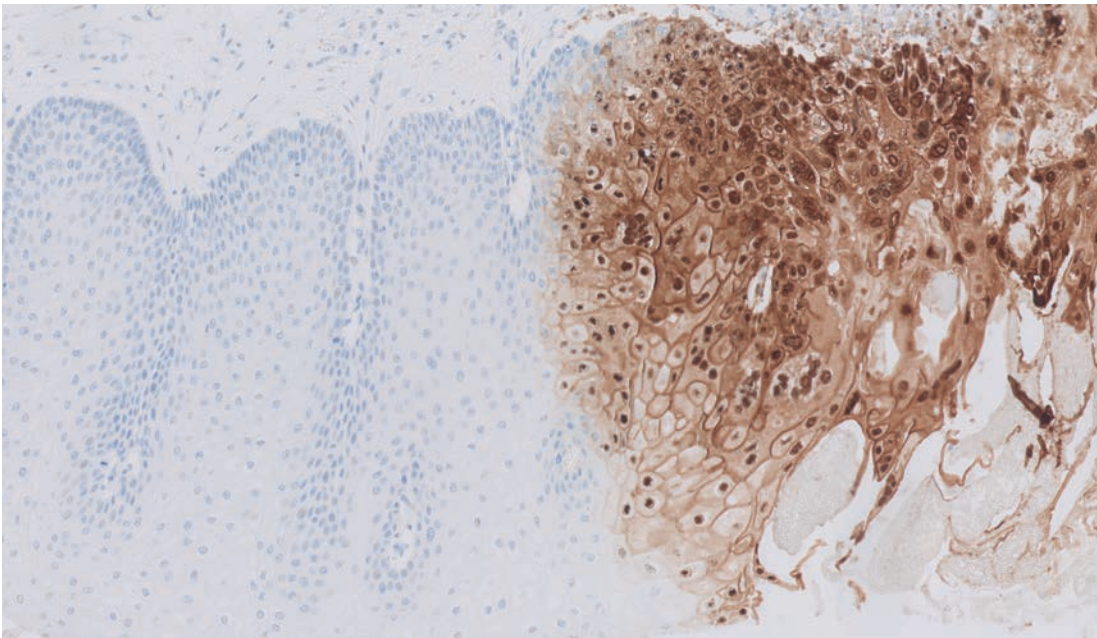
Polyclonal

Code:

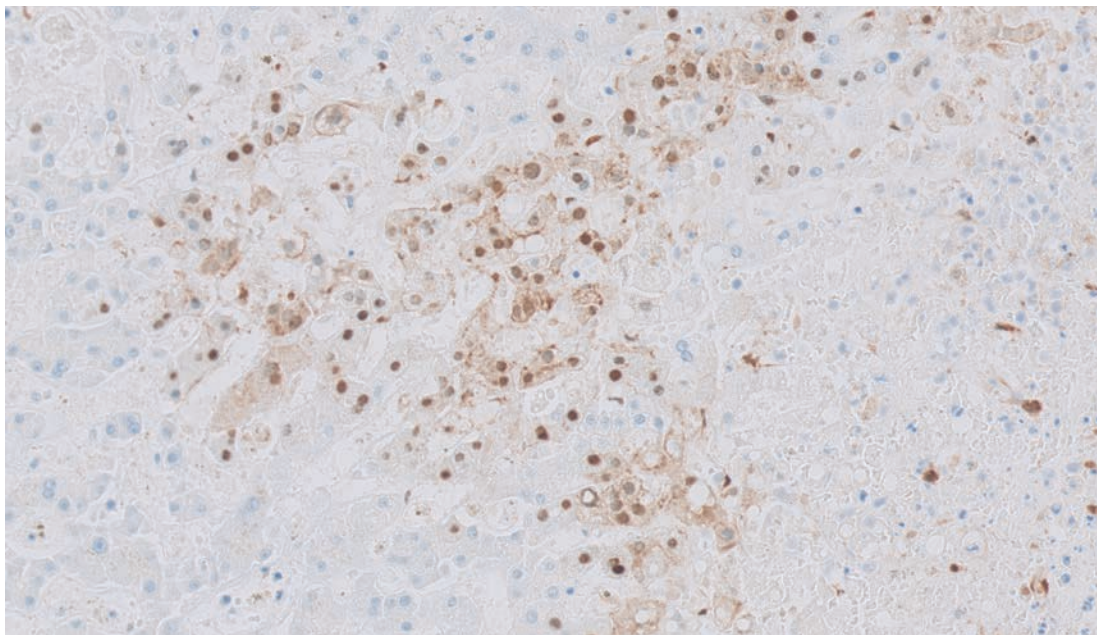
GA521 | IR521 *Not available in the US*

Reaction Location	Nucleus
Quality Control	Lesion with HSV
High Expression	T Cells infected with herpes simplex virus (type 1 or type 2) show a moderate to strong staining reaction.
Low Expression	T Cells infected with herpes simplex virus (type 1 or type 2) show a weak to moderate staining reaction.
Non-expression	NA

Note: The staining reaction intensity may vary from low to high depending of the level of protein expression.



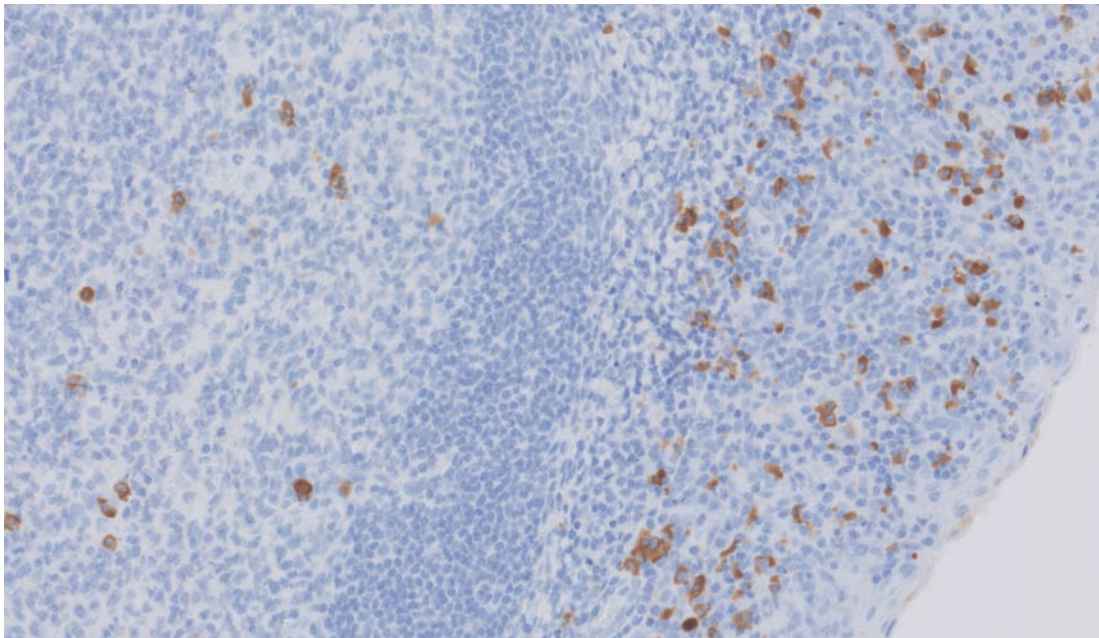
Esophagus (10x)



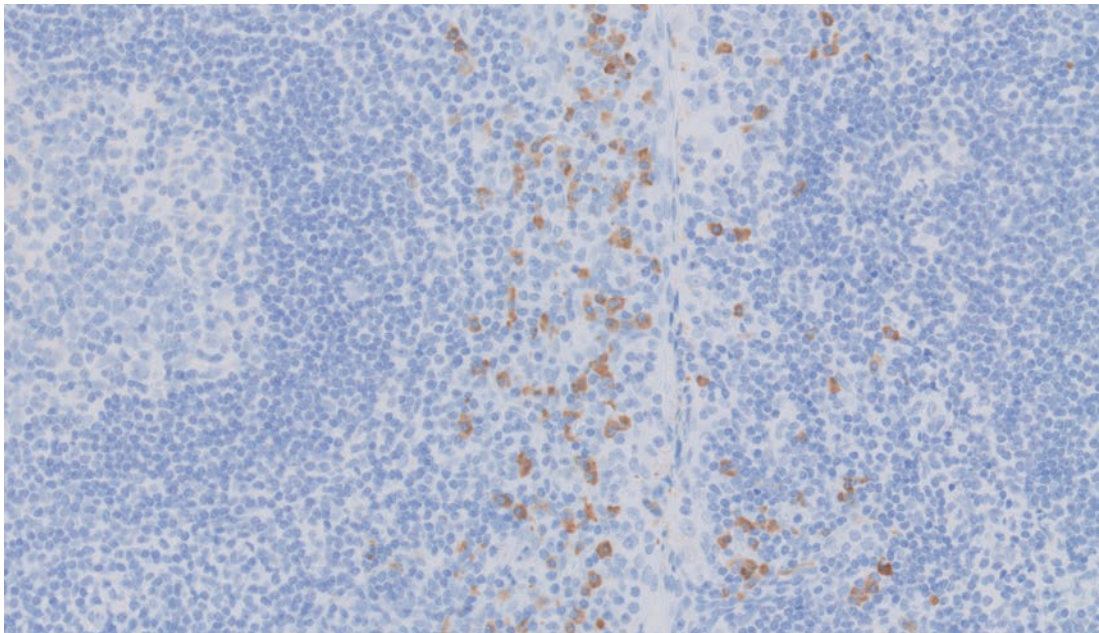
Liver (20x)

**Antibody:** Polyclonal Rabbit Anti-Human IgA  
**Clone:** Polyclonal  
**Code:** GA510 | IR510

Reaction Location	Cytoplasm and/or membrane
Quality Control	Tonsil
High Expression	Plasma cells and germinal center immunoblasts show a moderate to strong staining reaction.
Low Expression	NA
Non-expression	NA



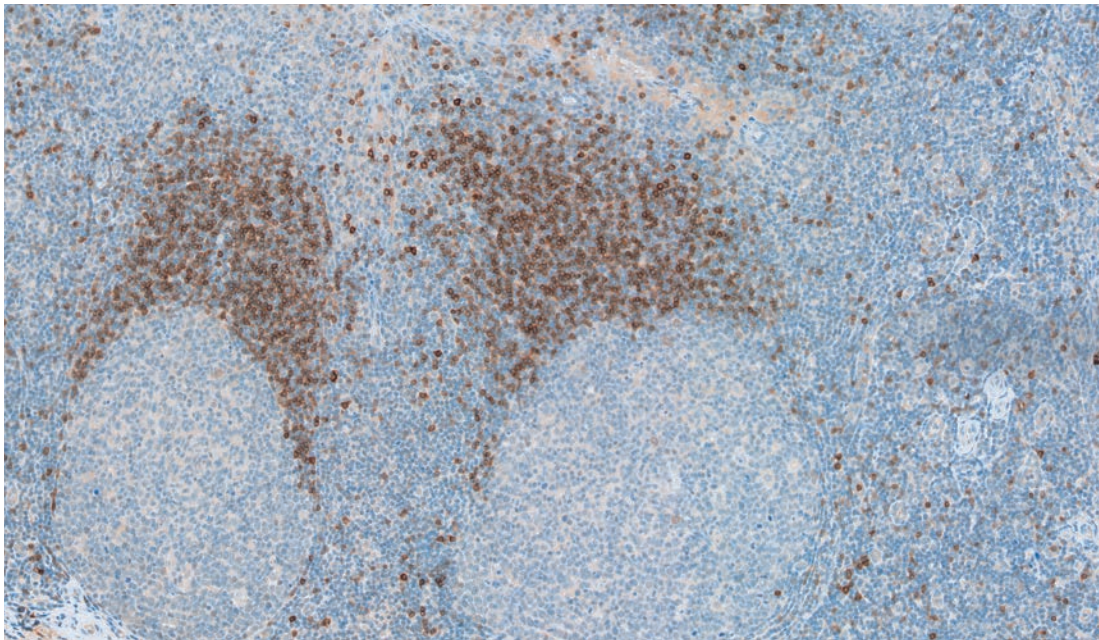
Tonsil (20x)



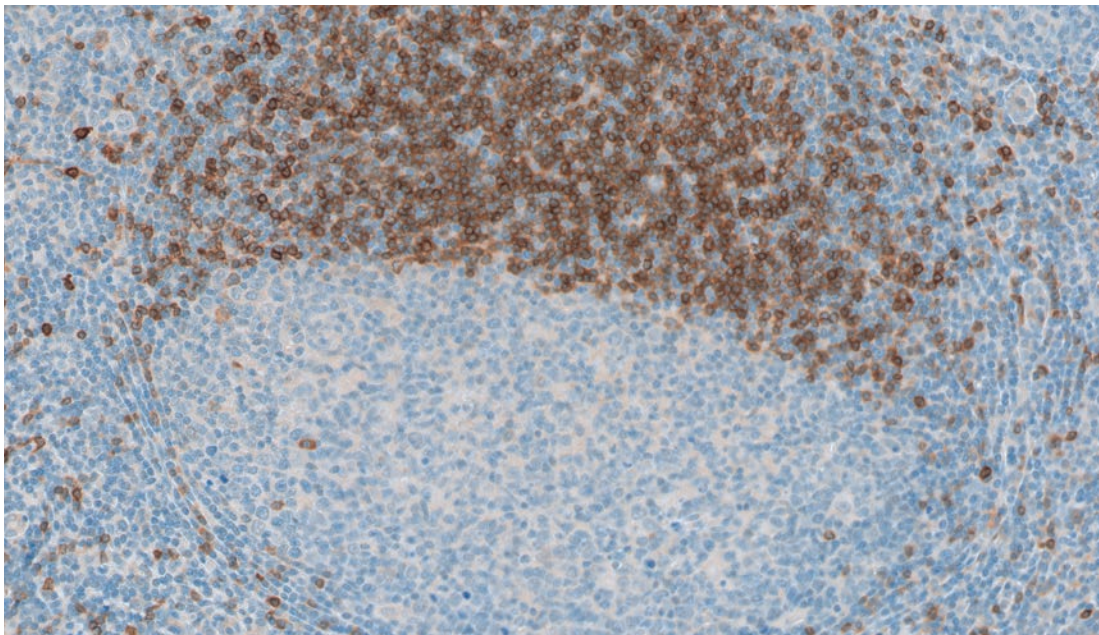
Tonsil (20x)

**Antibody:** Polyclonal Rabbit Anti-Human IgD  
**Clone:** Polyclonal  
**Code:** IR517

Reaction Location	Membrane and cytoplasm
Quality Control	Tonsil
High Expression	Mantle zone B cells show a moderate to strong, predominantly membranous reaction. Dispersed plasma cells show a moderate to strong cytoplasmic staining reaction.
Low Expression	NA
Non-expression	The background should be negative or show only a minimal staining reaction.



Tonsil (10x)



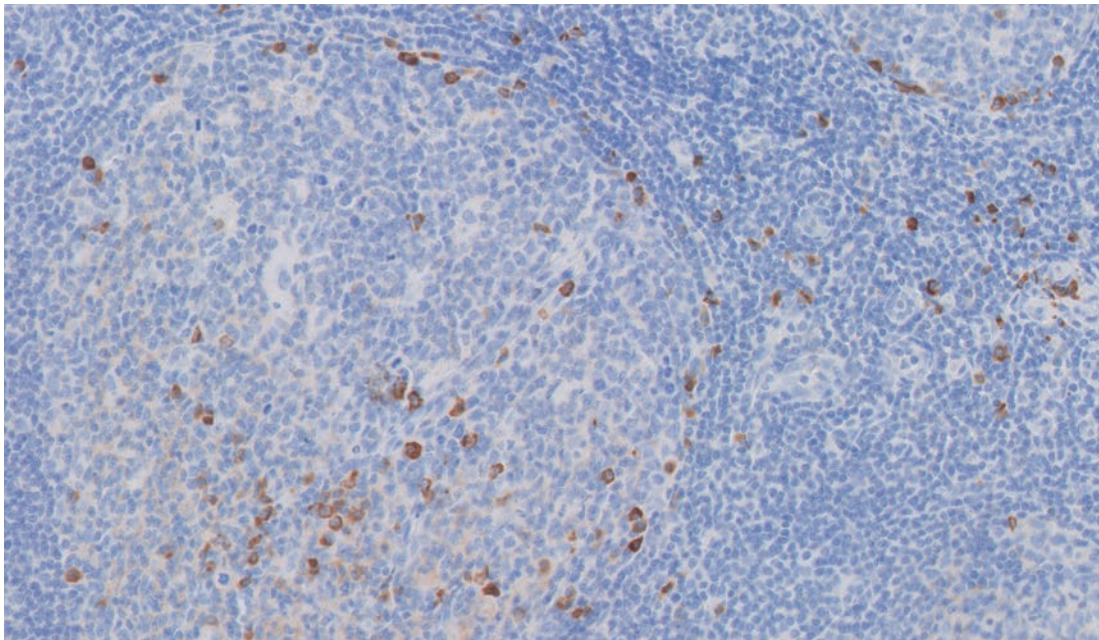
Tonsil (20x)



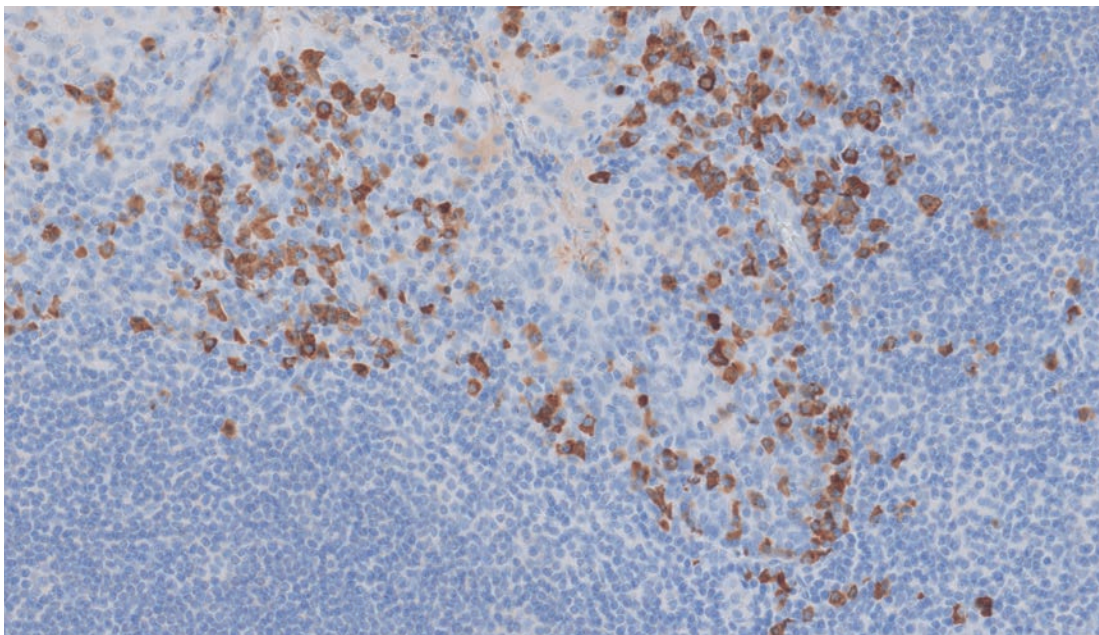
**Antibody:** Polyclonal Rabbit Anti-Human IgG  
**Clone:** Polyclonal  
**Code:** GA512 | IR512

Reaction Location	Cytoplasm and/or membrane
Quality Control	Tonsil
High Expression	Plasma cells and germinal center immunoblasts show a moderate to strong staining reaction.
Low Expression	NA
Non-expression	NA

Note: In bone marrow, the majority of plasma cells show a strong cytoplasmic staining reaction.



Tonsil (20x)

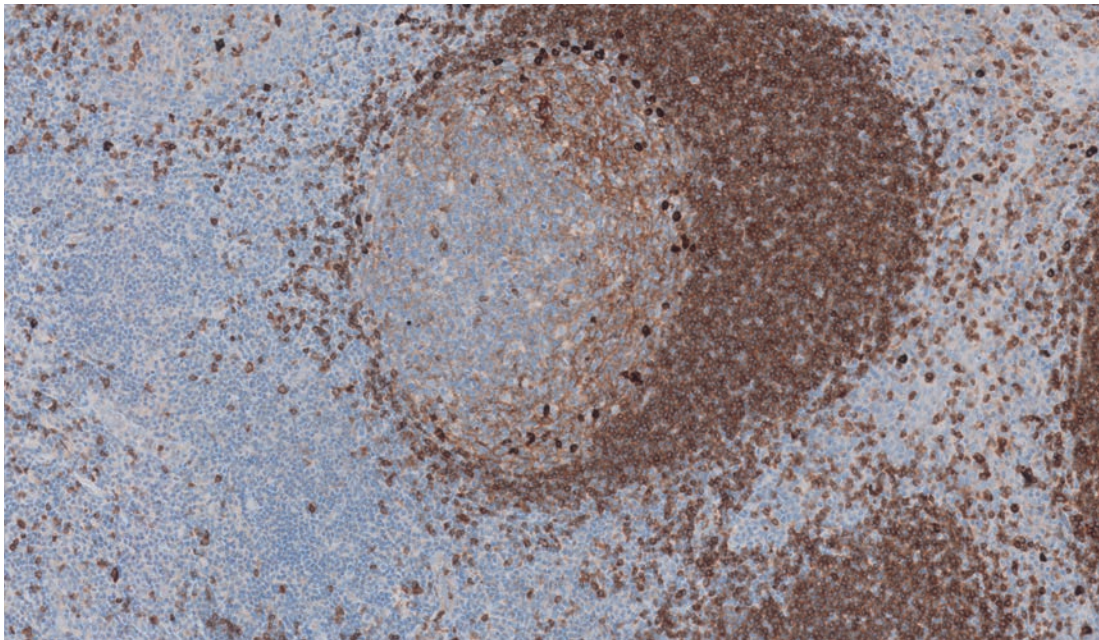


Tonsil (20x)

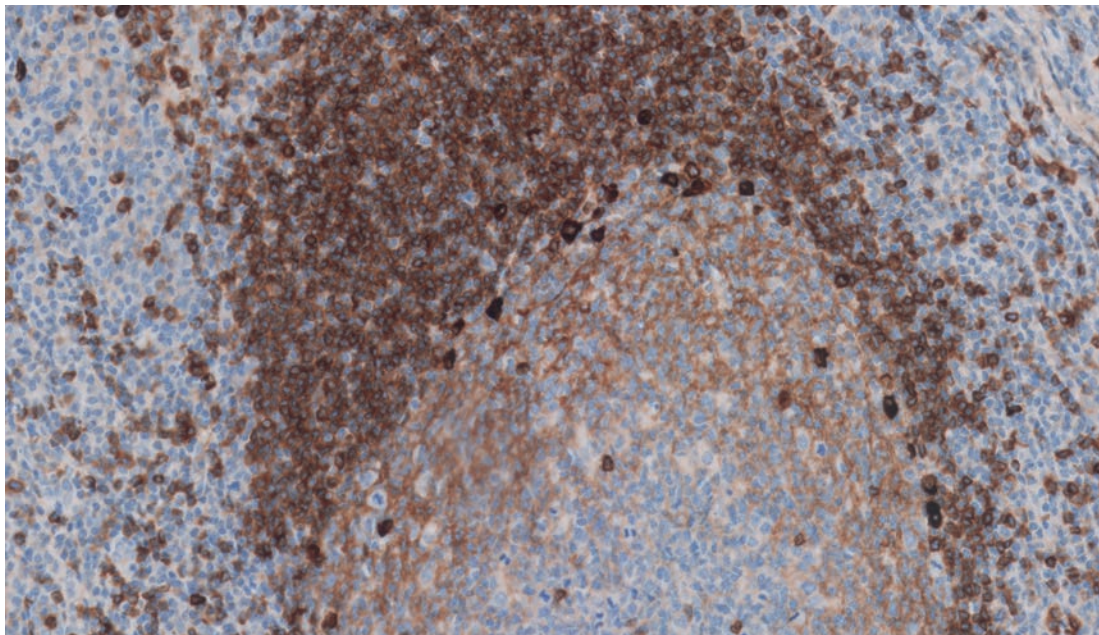
**Antibody:** Polyclonal Rabbit Anti-Human IgM  
**Clone:** Polyclonal  
**Code:** GA513 | IR513

Reaction Location	Cytoplasm and/or membrane
Quality Control	Tonsil
High Expression	Virtually all the mantle zone B cells show a moderate to strong membranous staining reaction, while immunoblasts and plasma cells in the germinal center show a strong cytoplasmic staining reaction.
Low Expression	NA
Non-expression	NA

Note: Some background reaction in serum, connective tissue and epithelial cells may be observed.



Tonsil (10x)

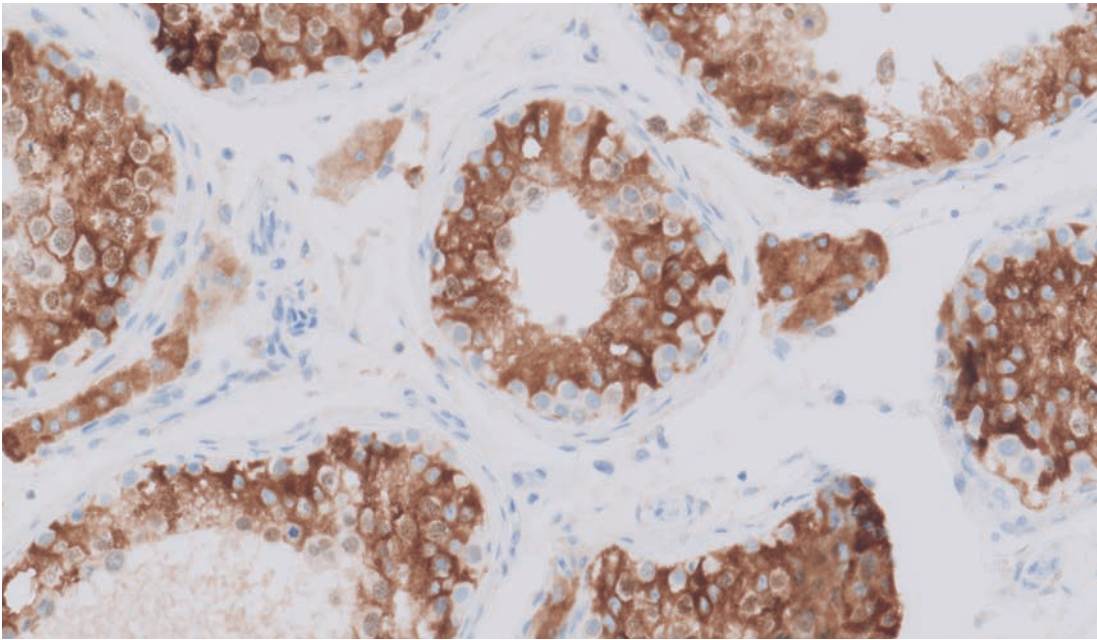


Tonsil (20x)

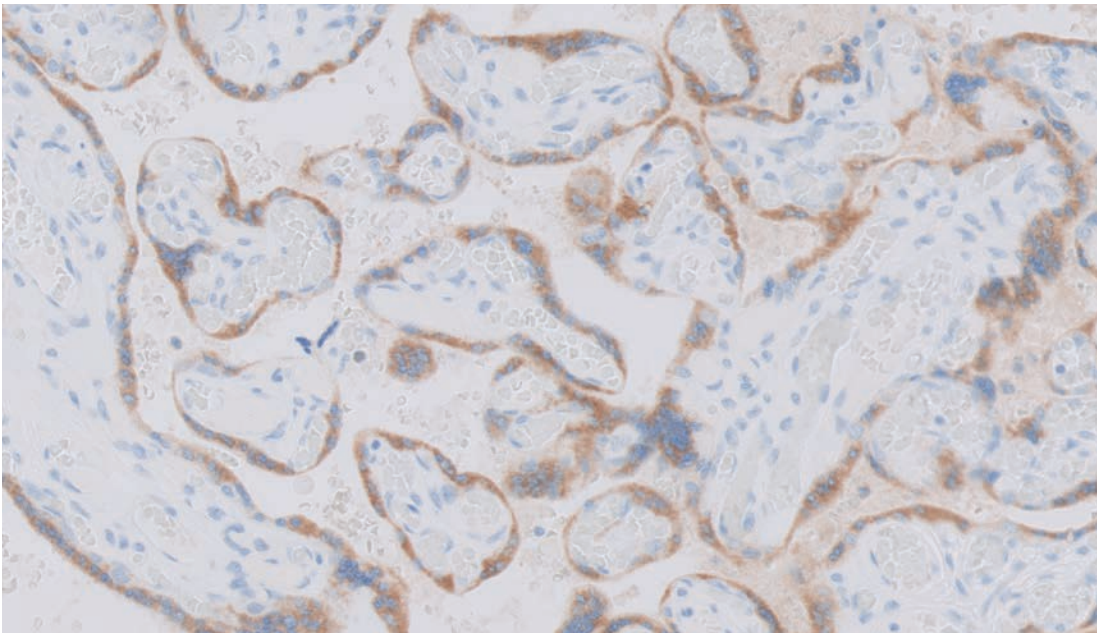
**Antibody:** Monoclonal Mouse Anti-Human  
**Clone:** Inhibin  $\alpha$   
**Code:** R1  
 GA058 | IR058

Reaction Location	Cytoplasm	
Quality Control	Testis	Placenta
High Expression	Leydig cells and the Sertoli cells show a moderate to strong distinct granular staining reaction.	NA
Low Expression	NA	Thropho- and syncytiotrophoblasts show a weak to moderate staining reaction.
Non-expression	NA	NA

Note: Occasionally, a weak to moderate coexisting nuclear staining reaction can be observed.



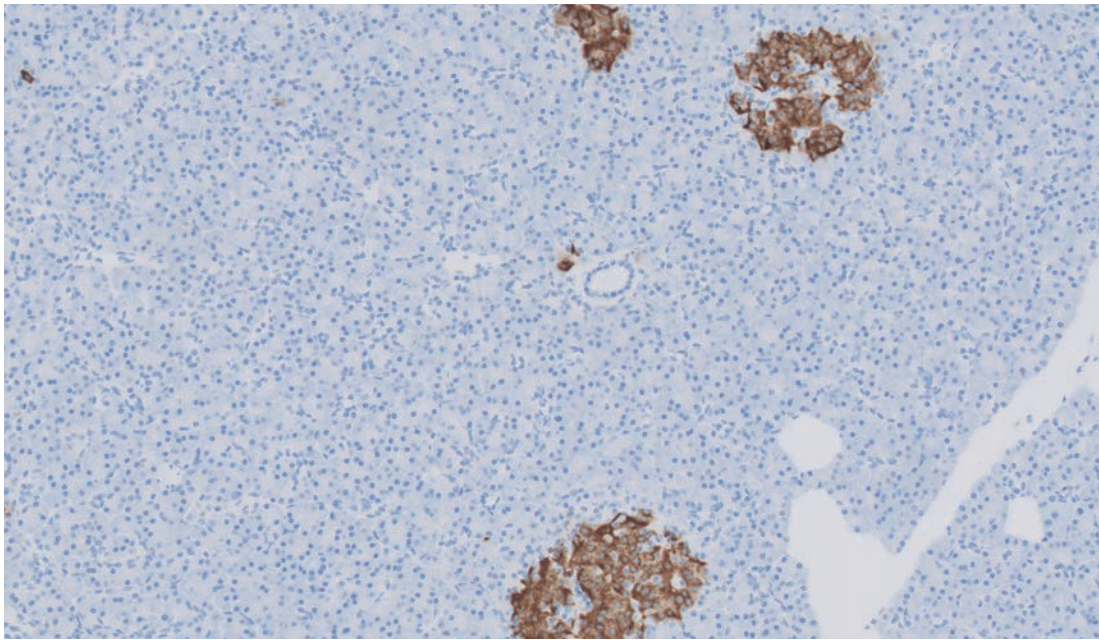
Testis (20x)



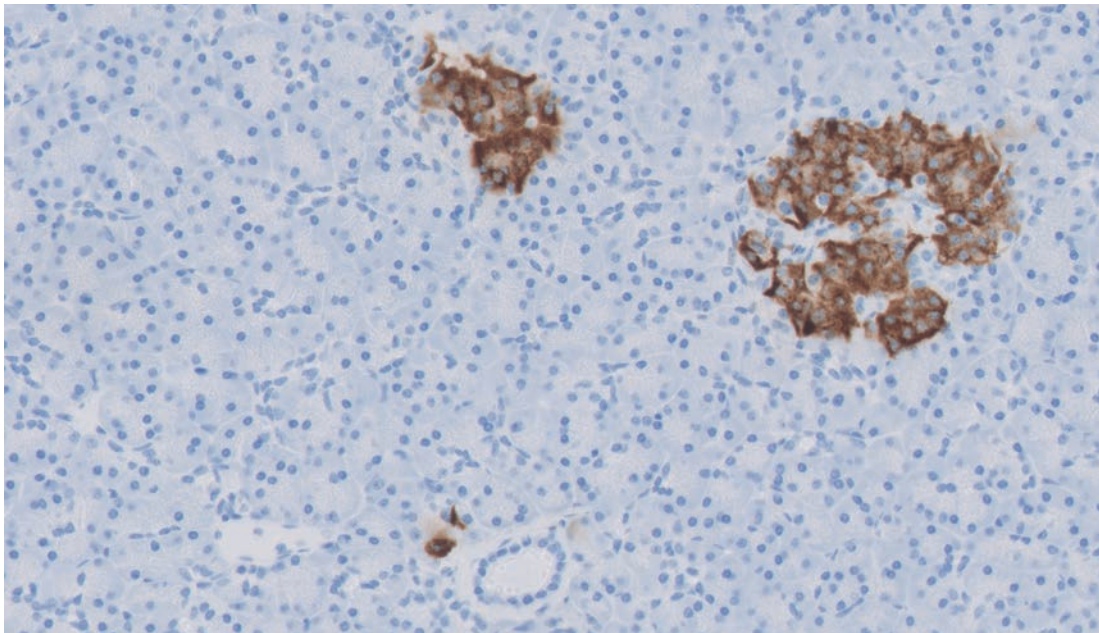
Placenta (20x)

**Antibody:** Polyclonal Guinea Pig Anti-Insulin  
**Clone:** Polyclonal  
**Code:** IR002

Reaction Location	Cytoplasm
Quality Control	<b>Pancreas</b>
High Expression	B cells in the islets of Langerhans show a moderate to strong staining reaction.
Low Expression	NA
Non-expression	Acinar epithelial cells.



Pancreas (10x)

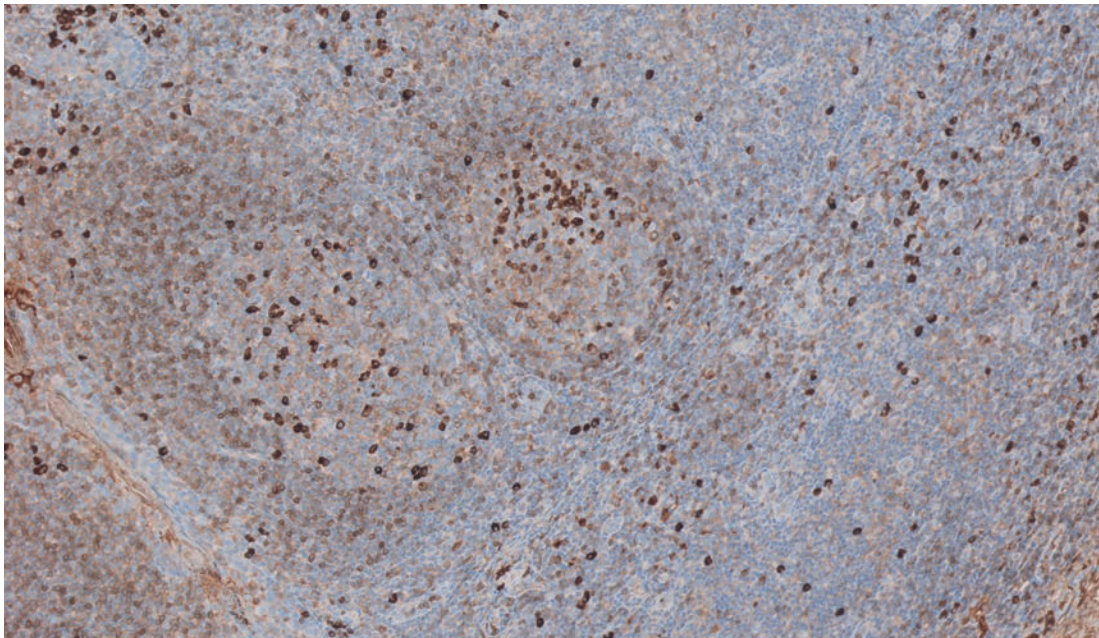


Pancreas (20x)

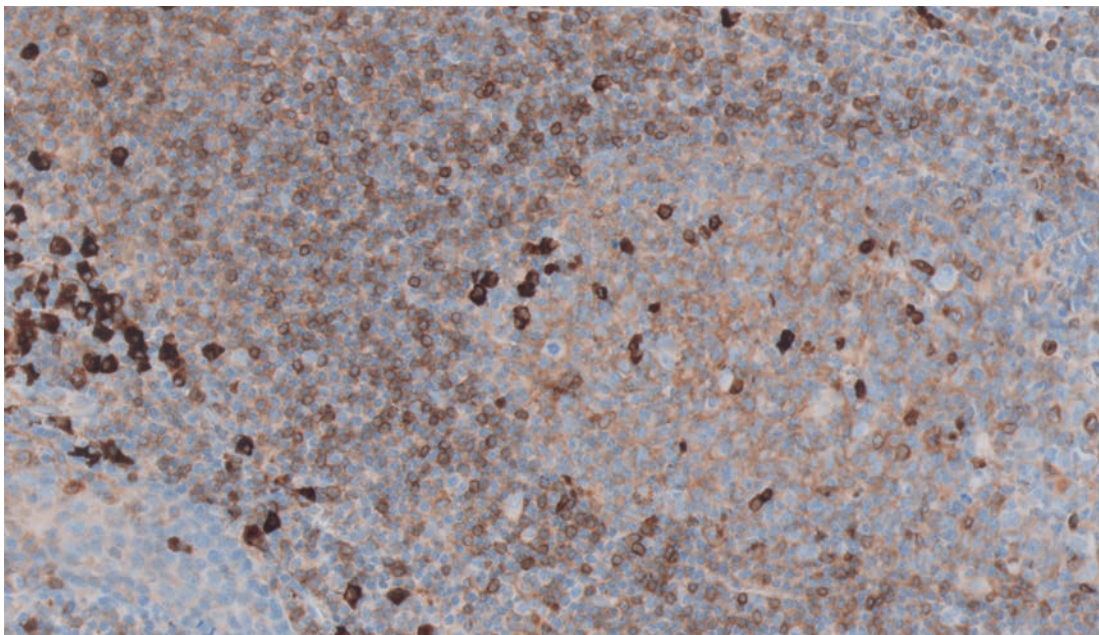
**Antibody:** Polyclonal Rabbit Anti-Human  
**Clone:** Kappa Light Chains  
**Code:** Polyclonal  
 GA506 | IR506

Reaction Location	Membrane and cytoplasm
Quality Control	Tonsil
High Expression	Immunoblasts and plasma cells in the germinal center show moderate to strong cytoplasmic staining.
Low Expression	Approximately 50% of the mantle zone B cells show a weak to moderate membranous staining reaction.
Non-expression	All T and B cells with lambda light chain expression.

Note: Some background reaction in serum, connective tissue and epithelial cells may be observed.



Tonsil (10x)

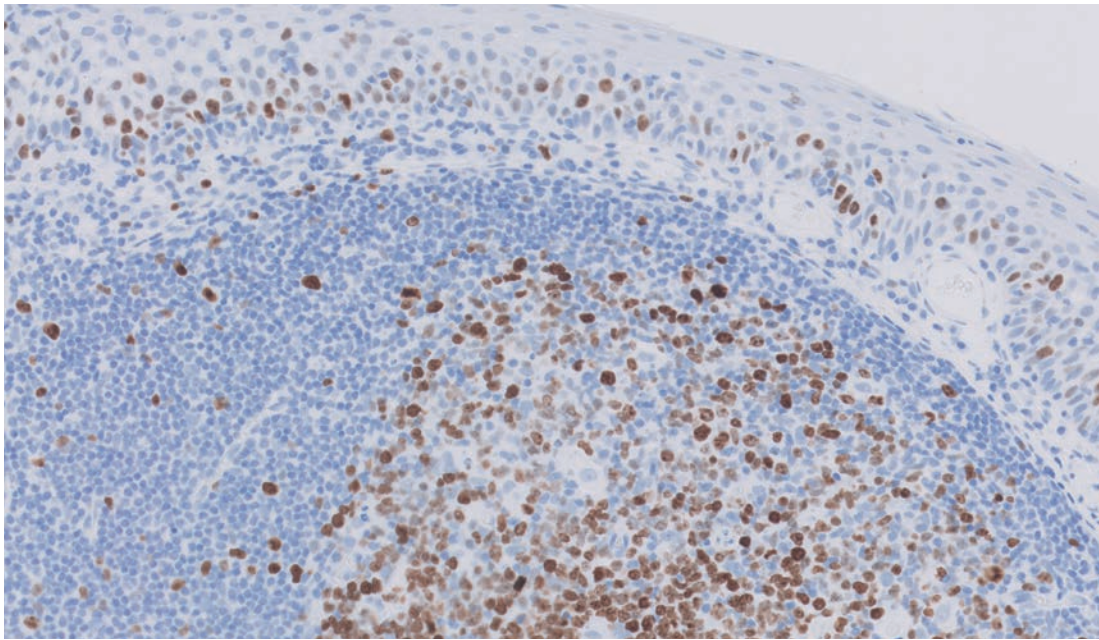


Tonsil (20x)

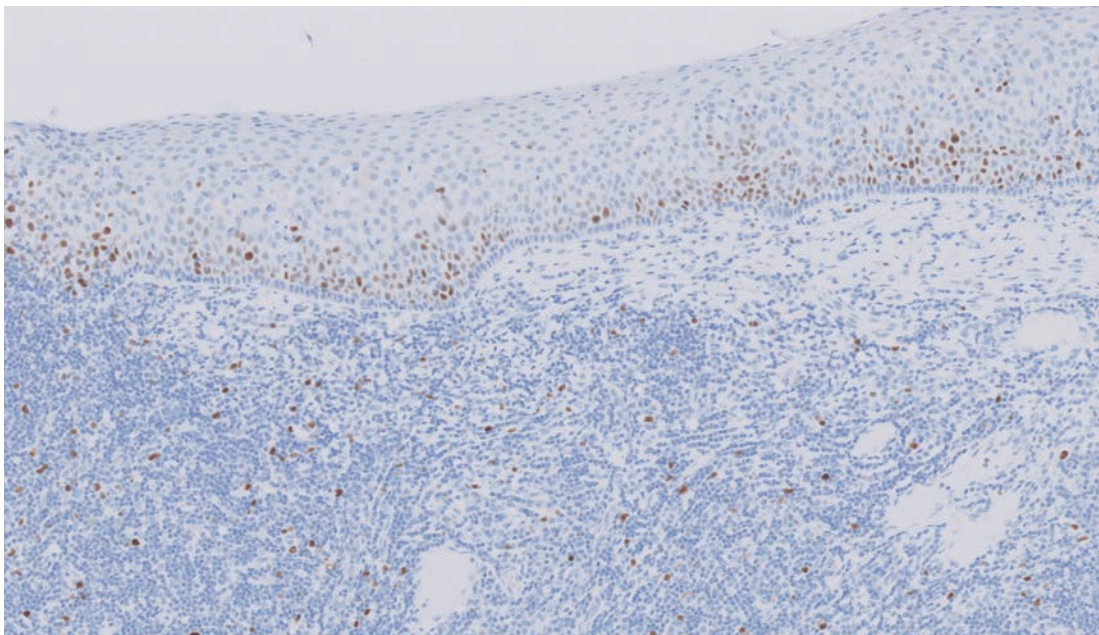
**Antibody:** Monoclonal Mouse Anti-Human  
**Clone:** Ki-67 Antigen  
**Code:** MIB-1  
 GA626 | IR626

Reaction Location	Nucleus
Quality Control	Tonsil
High Expression	Germinal center B cells of the dark zone show a moderate to strong staining reaction.
Low Expression	Basal and parabasal squamous epithelial cells show a weak to moderate staining reaction.
Non-expression	NA

Note: In mitotic cells, the chromosomes and the cytoplasm are labeled.



Tonsil (20x)

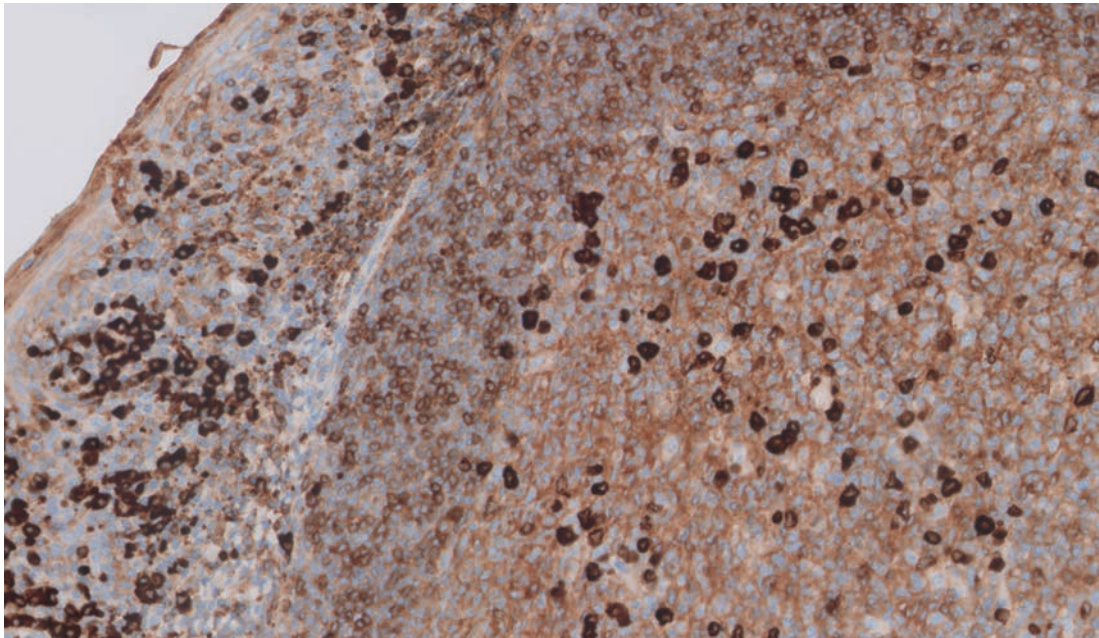


Tonsil (10x)

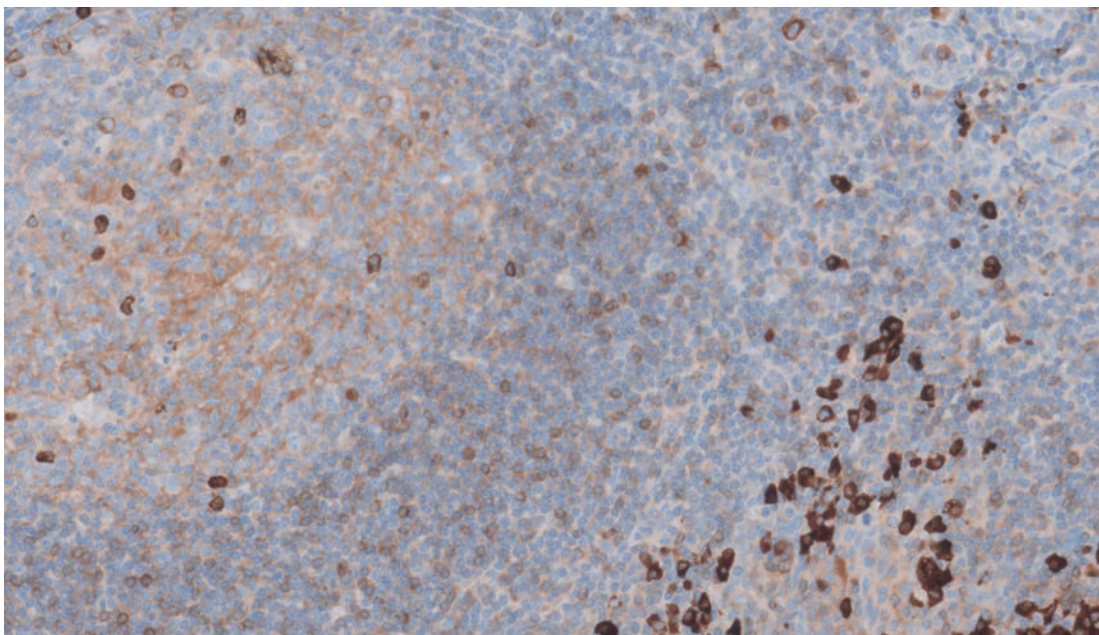
**Antibody:** Polyclonal Rabbit Anti-Human  
**Clone:** Lambda Light Chains  
**Code:** GA507 | IR507

Reaction Location	Membrane and cytoplasm
Quality Control	Tonsil
High Expression	Immunoblasts and plasma cells in the germinal center show moderate to strong cytoplasmic staining.
Low Expression	Approximately 50% of the mantle zone B cells show weak to moderate membranous staining reaction.
Non-expression	All T and B cells with kappa light chain expression.

Note: Some background reaction in serum, connective tissue and epithelial cells may be observed.



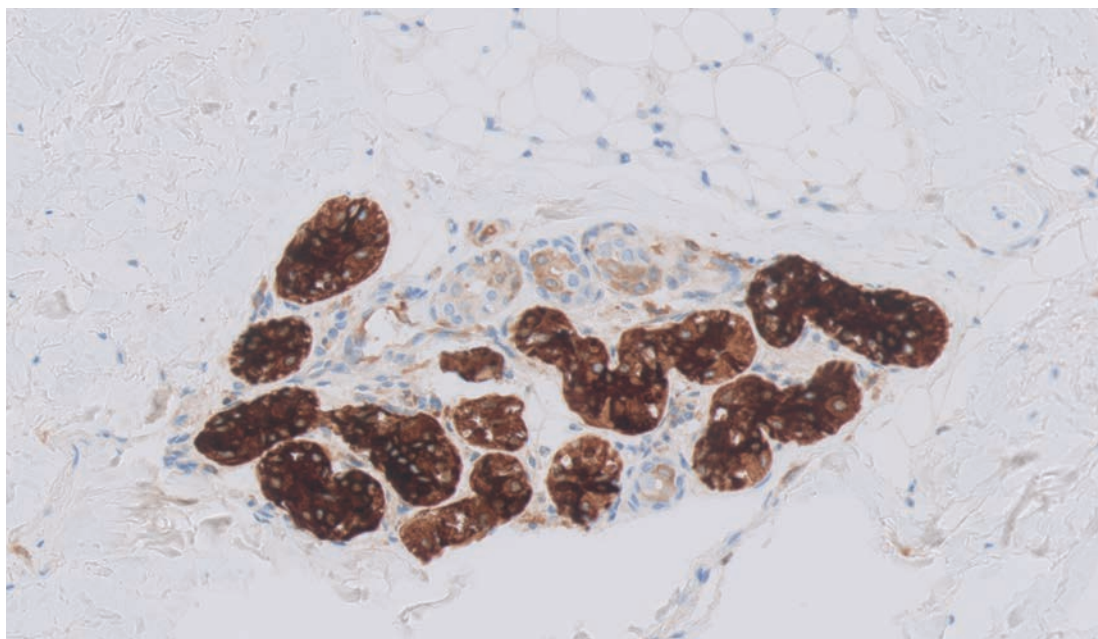
Tonsil (20x)



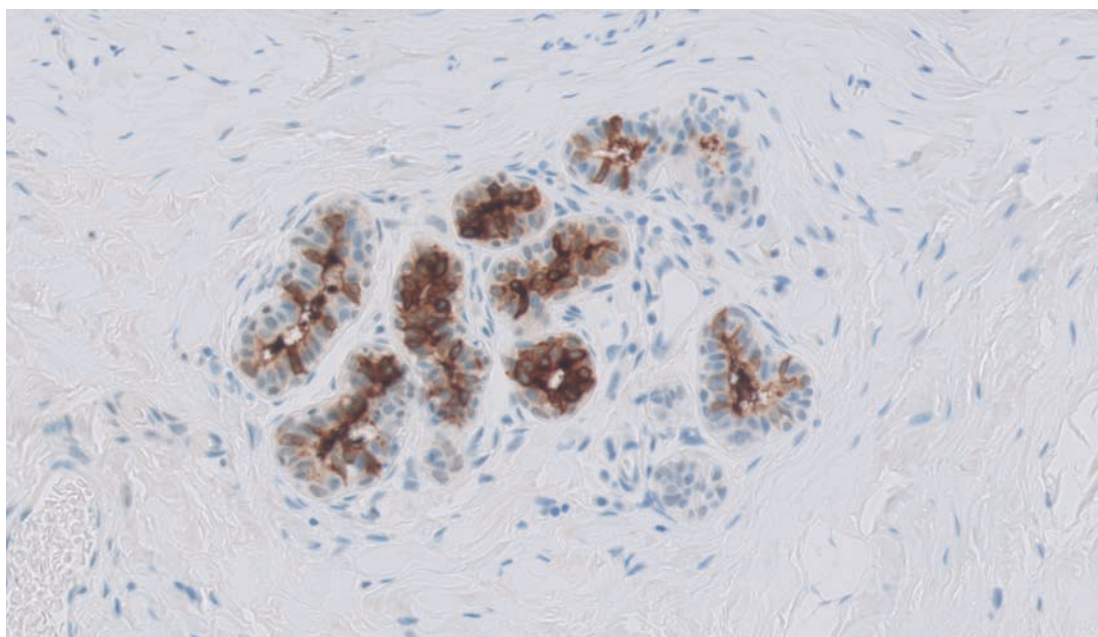
Tonsil (20x)

**Antibody:** Monoclonal Mouse Anti-Human  
**Clone:** Mammaglobin  
**Code:** 304-1A5  
 GA074 | IR074

Reaction Location	Cytoplasm	
Quality Control	Skin	Breast hyperplasia
High Expression	Epithelial cells in sweat glands show at least a focal, moderate to strong staining reaction.	At least focally, ductal epithelial cells show moderate to strong staining reaction.
Low Expression	NA	NA
Non-expression	Squamous epithelial cells.	NA



Skin (20x)



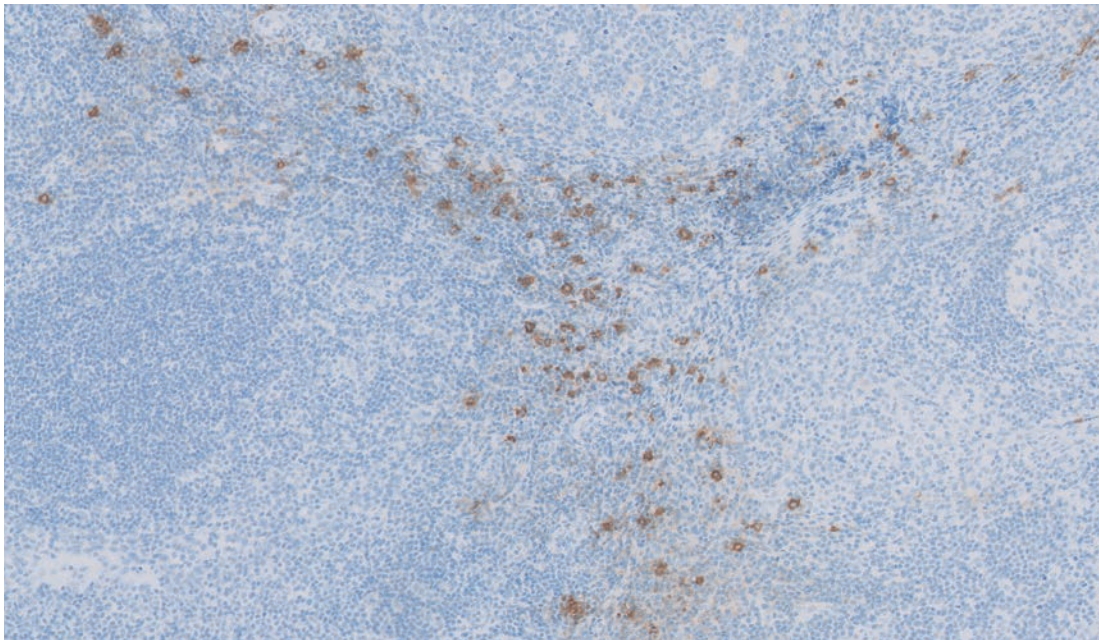
Breast hyperplasia (20x)



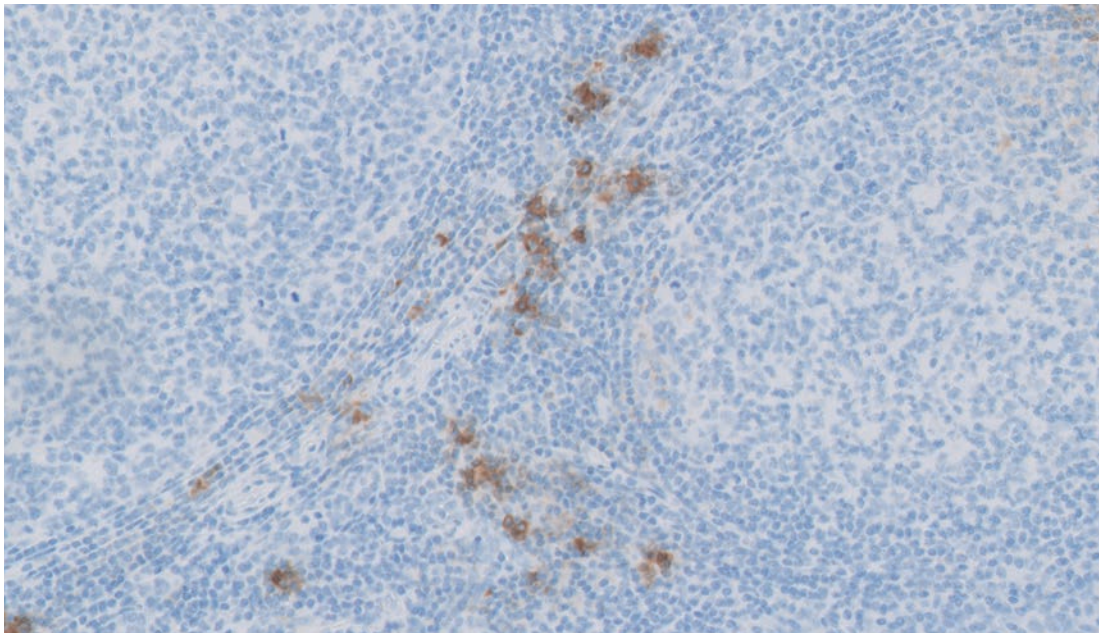
**Antibody:** Monoclonal Mouse Anti-Human  
**Mast Cell Tryptase**  
**Clone:** AA1  
**Code:** IR640

Reaction Location	Cytoplasm
Quality Control	Tonsil
High Expression	Mast cells show a moderate to strong staining reaction.
Low Expression	NA
Non-expression	Lymphocytes

Note: Occasionally, a weak and diffuse staining pattern in the vicinity of the labeled cells may be seen.



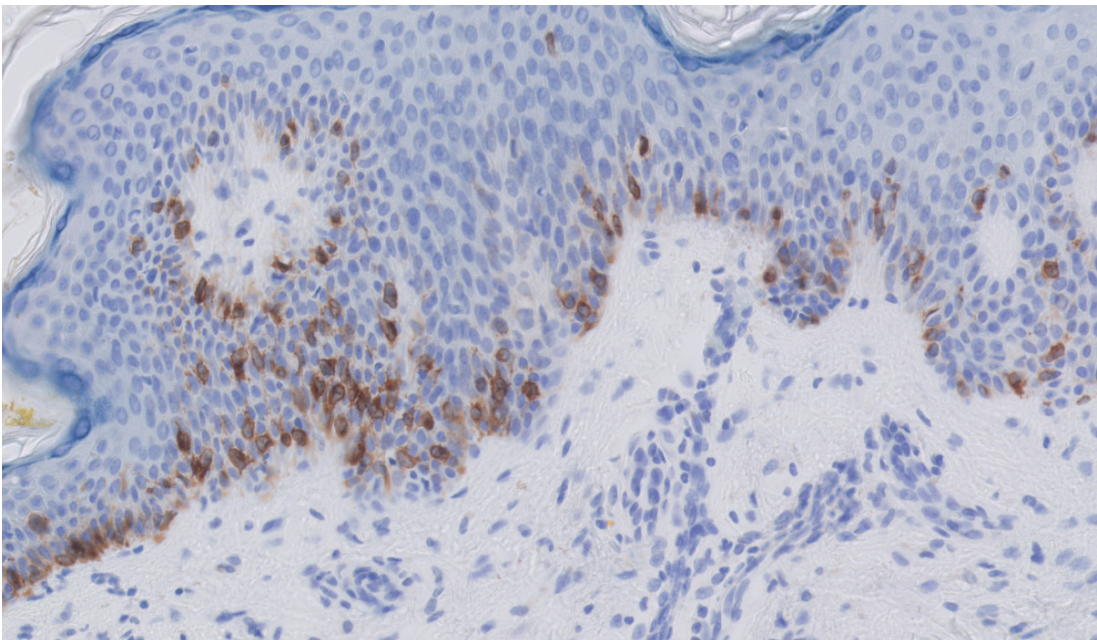
Tonsil (10x)



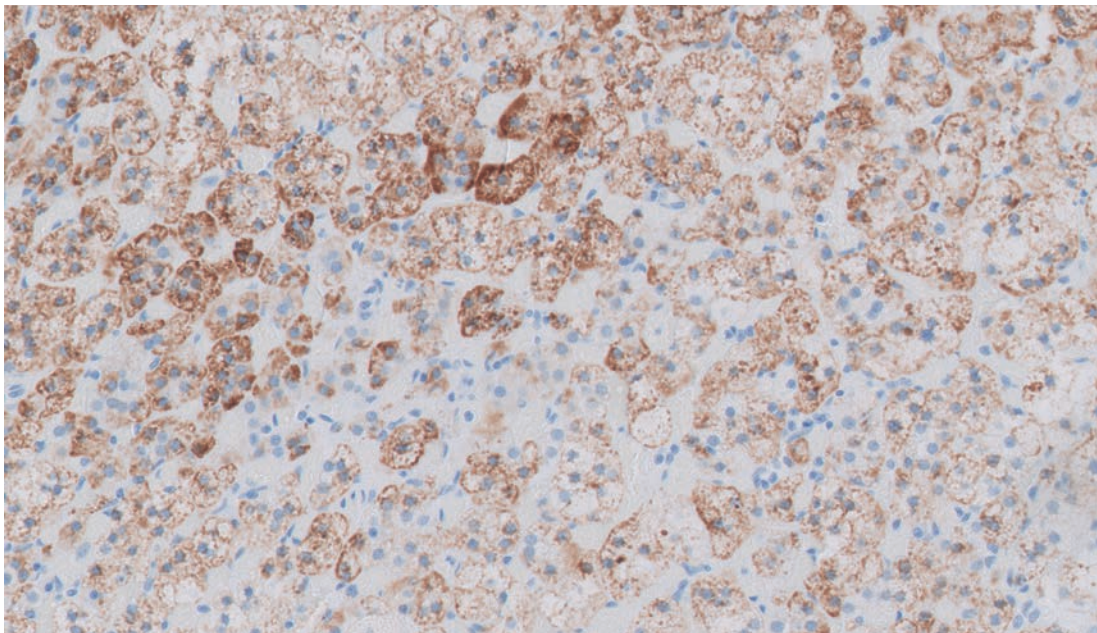
Tonsil (20x)

Antibody: Monoclonal Mouse Anti-Human  
 Clone: Melan-A  
 Code: A103  
 IR633

Reaction Location	Cytoplasm	
Quality Control	Skin	Adrenal gland
High Expression	Melanocytes in the basal layer of the epidermis show a moderate to strong staining reaction.	NA
Low Expression	NA	Virtually all the adrenal cortical cells show a weak to moderate granular staining reaction throughout all zones of the gland.
Non-expression	Squamous epithelial cells.	NA



Skin (20x)

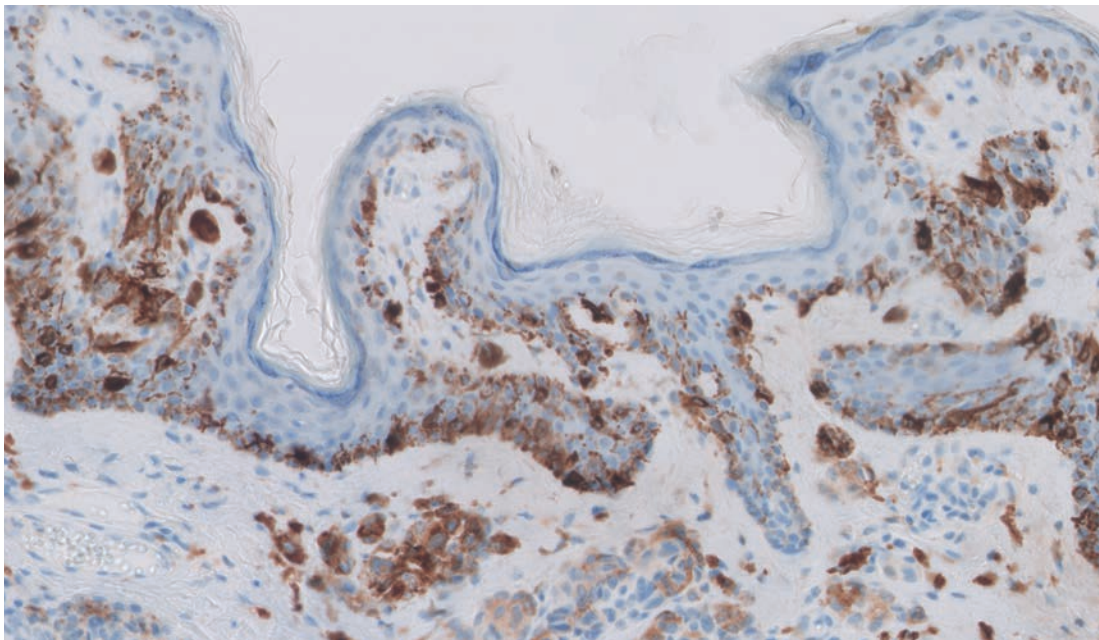


Adrenal gland (20x)

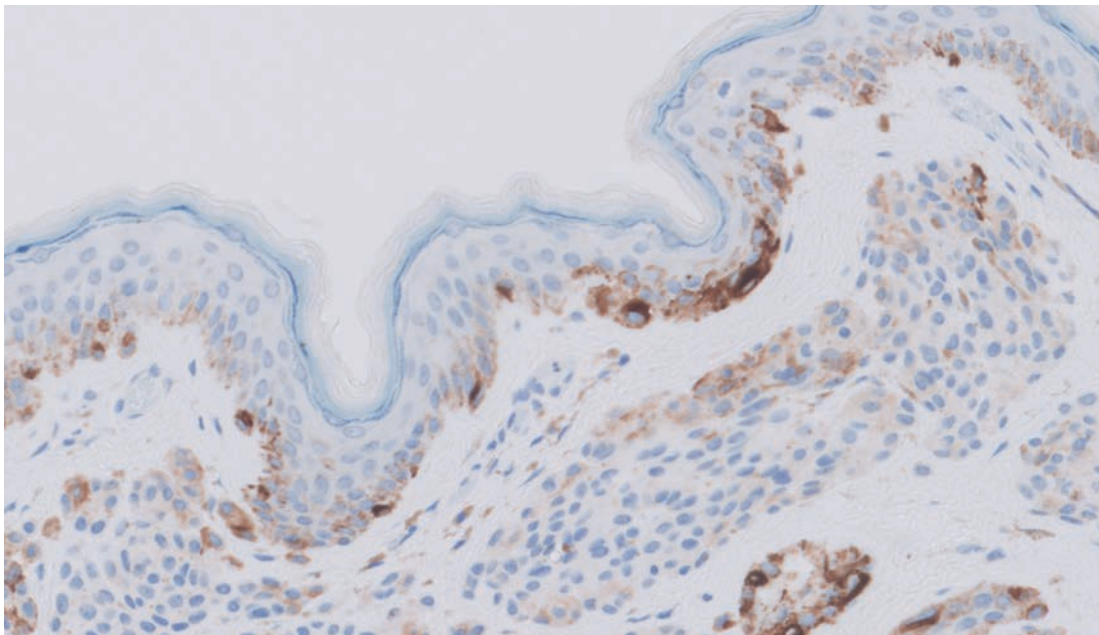
**Antibody:** Monoclonal Mouse Anti-Human  
**Clone:** Melanosome  
**Code:** HMB45  
 GA052 | IR052

Reaction Location	Cytoplasm	
Quality Control	Nevus	Kidney (not shown)
High Expression	The nevus cells in the dermis show a weak to strong staining reaction.	NA
Low Expression	The nevus cells in the dermis show a weak to strong staining reaction.	NA
Non-expression	NA	Epithelial cells.

Note: Normal resting melanocytes in skin are typically not demonstrated by the antibody.



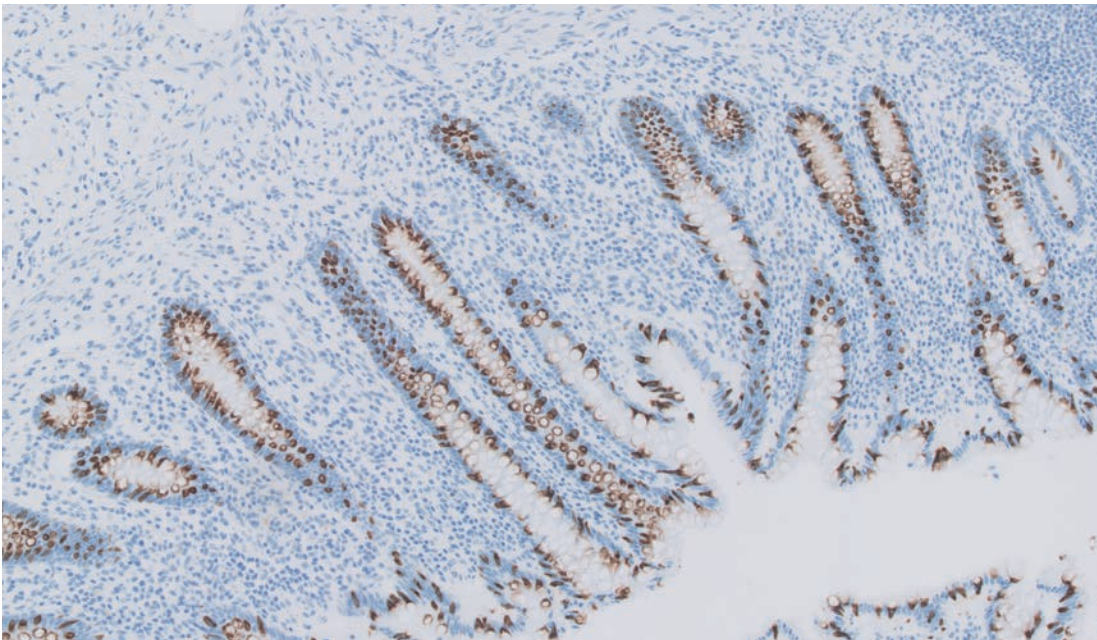
Nevus (20x)



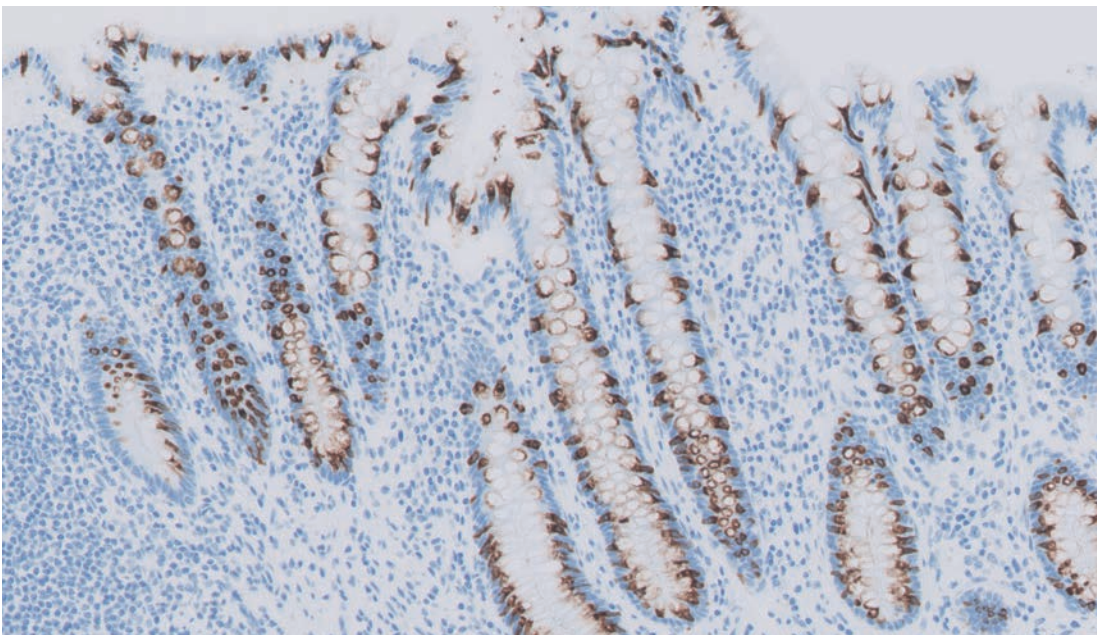
Nevus (20x)

Antibody: Monoclonal Mouse Anti-Human  
Clone: MUC2  
Code: CCP58  
Code: IR658

Reaction Location	Cytoplasm
Quality Control	Colon/Appendix
High Expression	Goblet cells show a moderate to strong staining reaction.
Low Expression	NA
Non-expression	NA



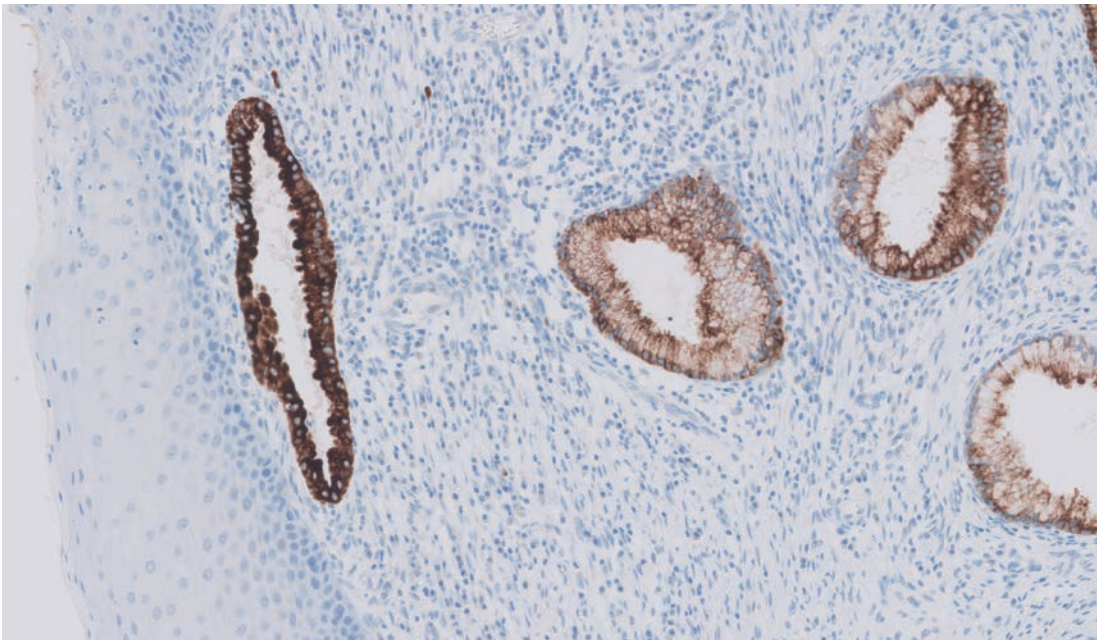
Appendix (10x)



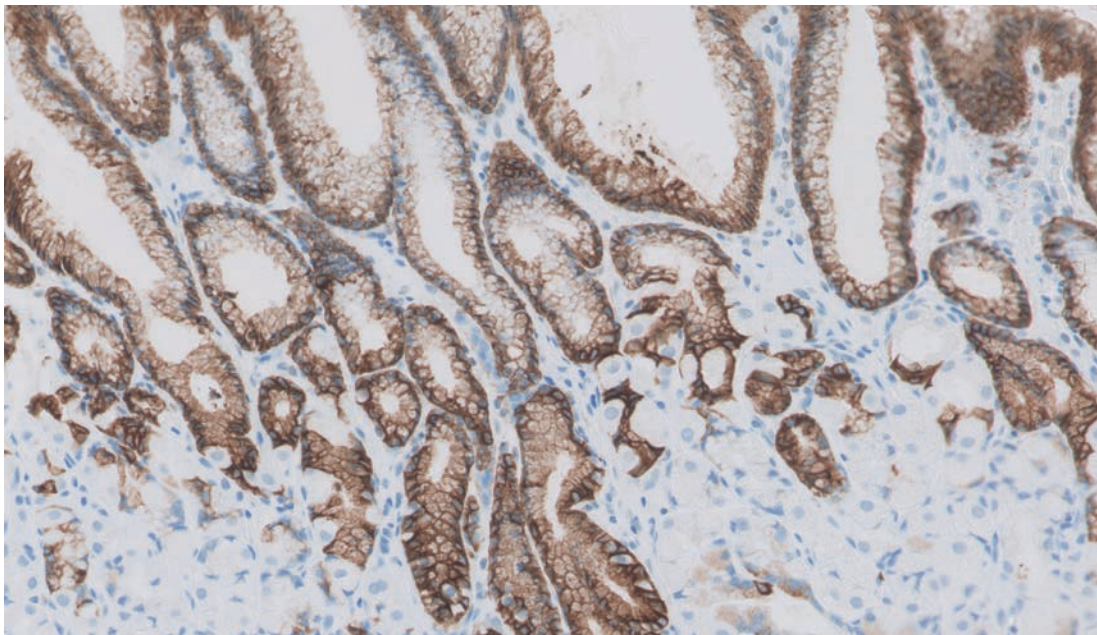
Appendix (20x)

**Antibody:** Monoclonal Mouse Anti-Human  
**Clone:** MUC5AC  
**Code:** CLH2  
 IR661

Reaction Location	Cytoplasm and/or nucleus	
Quality Control	Cervix	Gastric
High Expression	Columnar epithelial cells show a moderate to strong staining reaction.	Foveolar and mucopeptic neck cells show a moderate to strong staining reaction.
Low Expression	NA	NA
Non-expression	NA	NA



Cervix (10x)

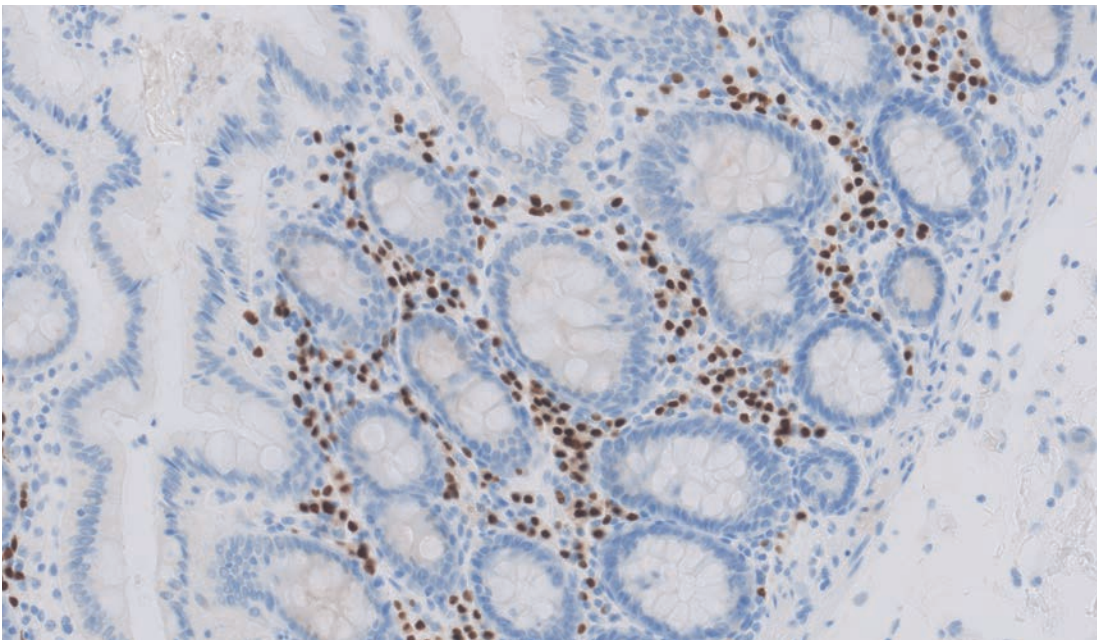


Gastric (20x)

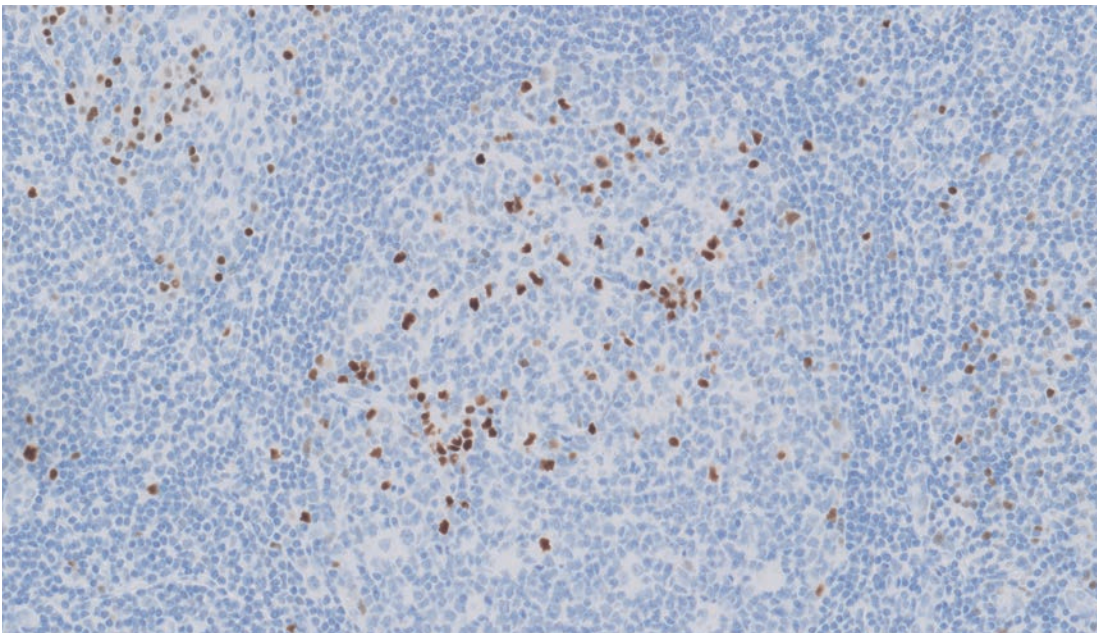
**Antibody:** Monoclonal Mouse Anti-Human  
**Clone:** MUM1p  
**Code:** GA644 | IR644

Reaction Location	Nucleus and cytoplasm	
Quality Control	Colon/Appendix	Tonsil
High Expression	Plasma cells show a moderate to strong predominantly nuclear staining reaction.	NA
Low Expression	NA	Activated B cells show a weak to moderate predominantly nuclear staining reaction.
Non-expression	NA	Epithelial cells.

Note: Interfollicular cells show a moderate to strong nuclear staining reaction. Only a minimal cytoplasmic staining reaction should be seen.



Colon (20x)

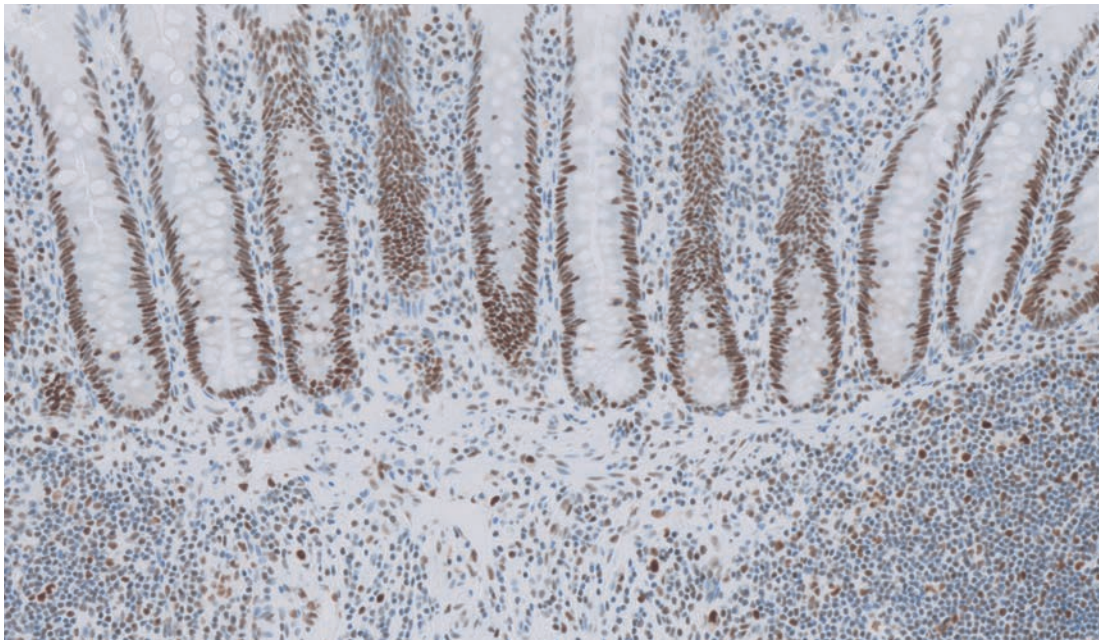


Tonsil (20x)

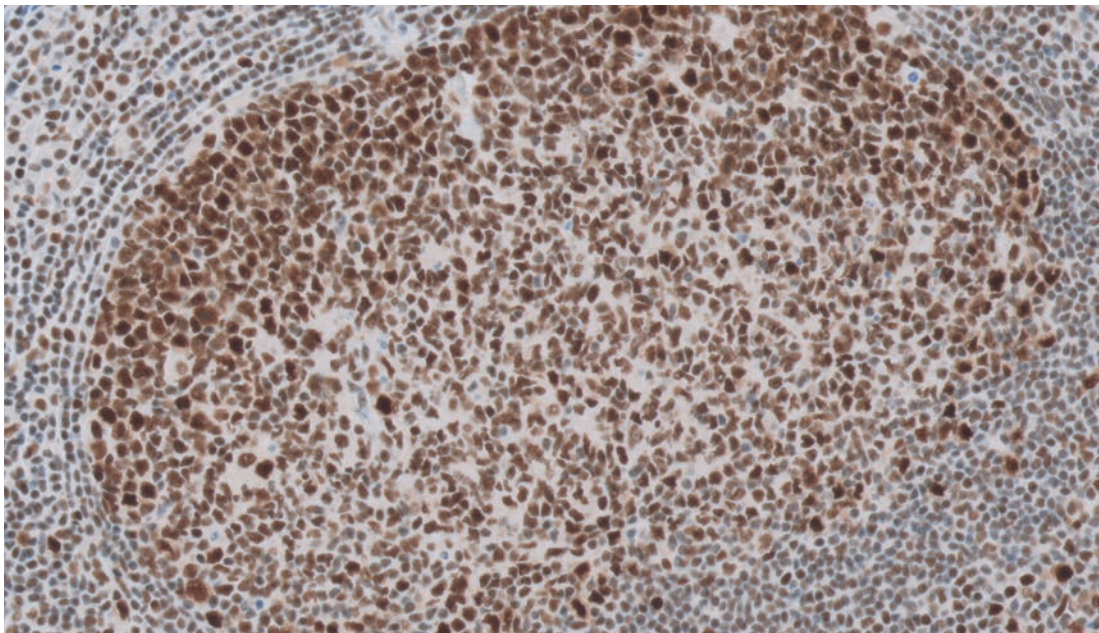
**Antibody:** Monoclonal Mouse Anti-Human  
**Clone:** MutL Protein Homolog 1 (MLH1)  
**Code:** ES05  
**Code:** IR079

Reaction Location	Nucleus	
Quality Control	Colon/Appendix	Tonsil
High Expression	Basal epithelial cells show a moderate to strong staining reaction.	Germinal center cells show a moderate to strong staining reaction.
Low Expression	Luminal epithelial cells and smooth muscle cells at least show a weak to moderate staining reaction.	Mantle zone B and T cells show a weak to moderate staining reaction.
Non-expression	NA	NA

Note: Delayed fixation or long term storage of cut sections may reduce staining intensity which may impact interpretation.



Appendix (20x)

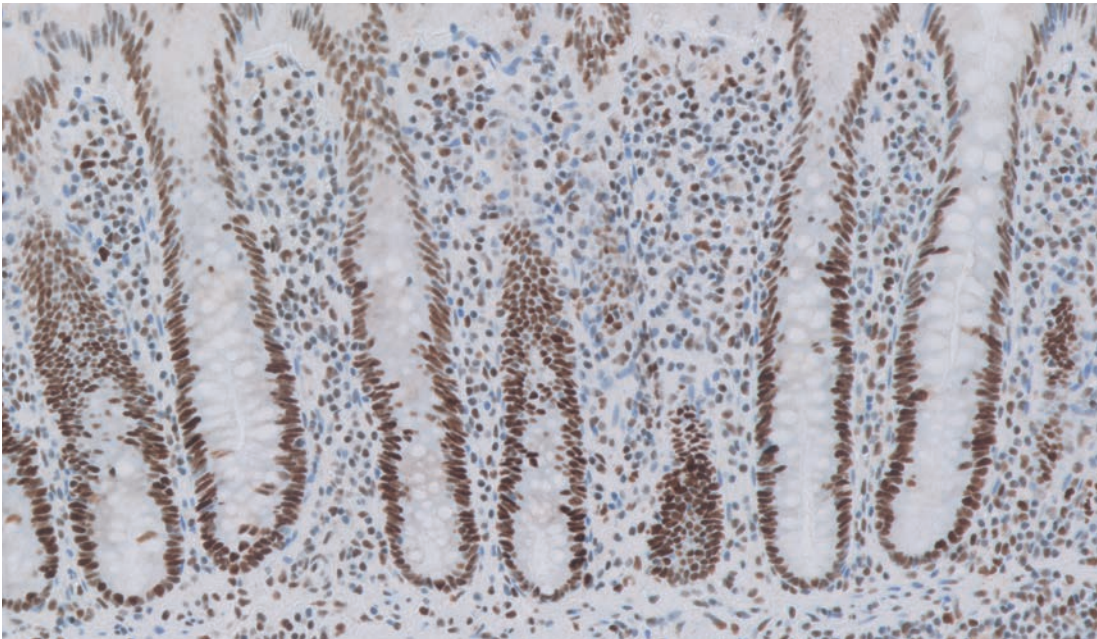


Tonsil (20x)

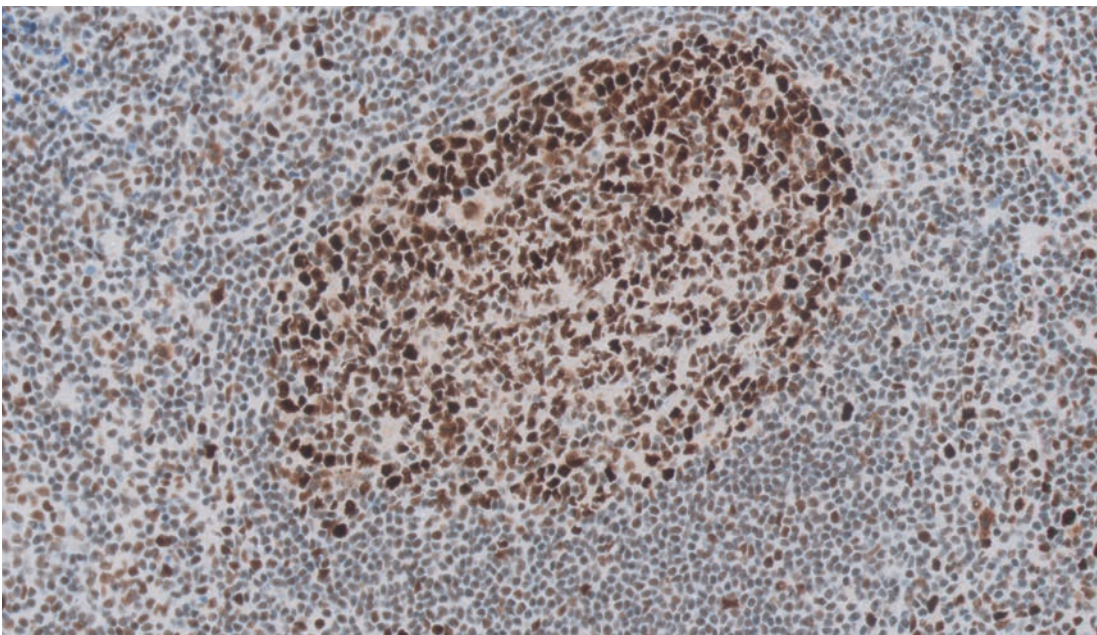
**Antibody:** Monoclonal Mouse Anti-Human  
**Clone:** MutS Protein Homolog 2 (MSH2)  
**Code:** FE11  
**Code:** IR085

Reaction Location	Nucleus	
Quality Control	Colon/Appendix	Tonsil
High Expression	Basal epithelial cells show a moderate to strong staining reaction.	Germinal center cells show a moderate to strong staining reaction.
Low Expression	Luminal epithelial cells and smooth muscle cells at least show a weak to moderate staining reaction.	Mantle zone B and T cells show a weak to moderate staining reaction.
Non-expression	NA	NA

Note: Delayed fixation or long term storage of cut sections may reduce staining intensity which may impact interpretation.



Appendix (20x)



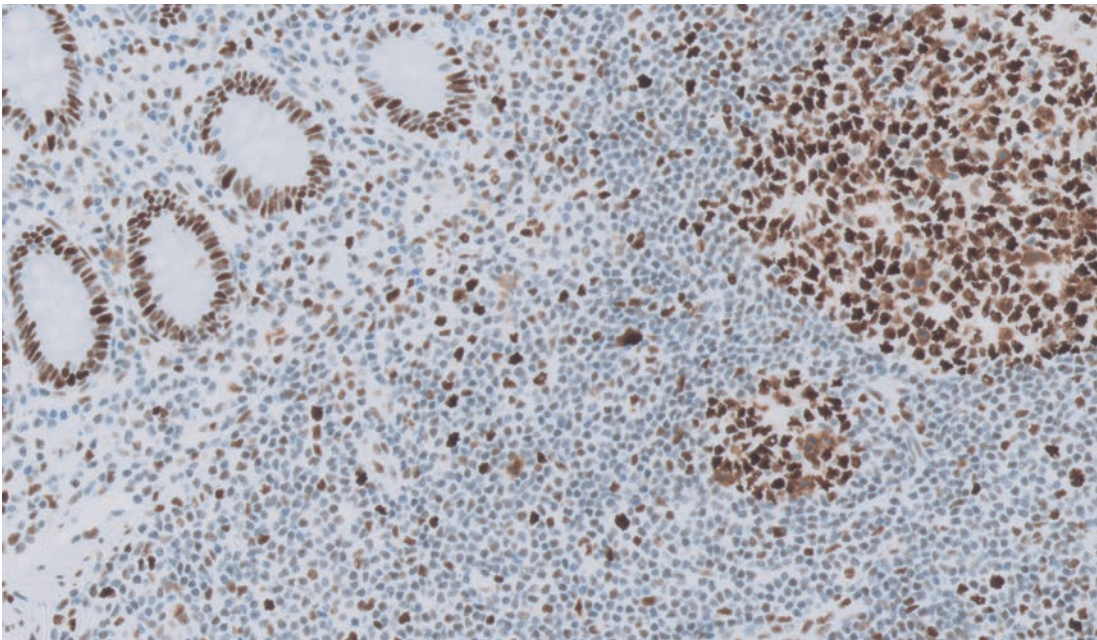
Tonsil (20x)



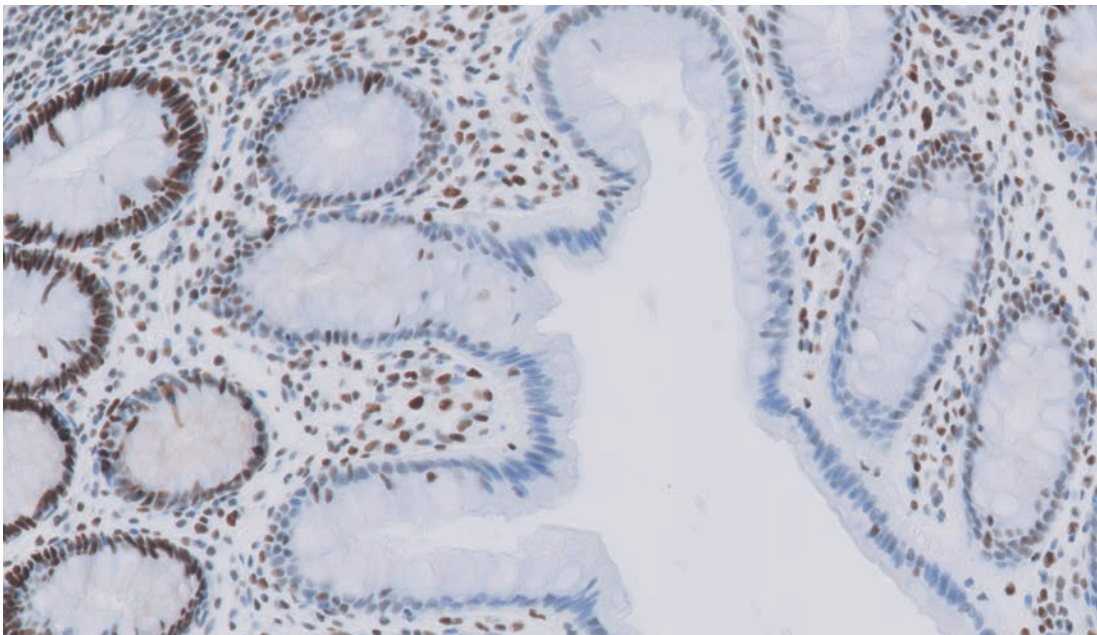
**Antibody:** Monoclonal Rabbit Anti-Human  
**Clone:** MutS Protein Homolog 6 (MSH6)  
**Code:** EP49  
**Code:** IR086

Reaction Location	Nucleus
Quality Control	Colon/Appendix
High Expression	Virtually all cells show a distinct nuclear staining reaction. The basal epithelial cells and germinal center cells in lymphoid follicles show a moderate to strong staining reaction.
Low Expression	Luminal epithelial cells and stromal cells should at least show a weak to moderate staining reaction.
Non-expression	NA

Note: Delayed fixation or long term storage of cut sections may reduce staining intensity which may impact interpretation.



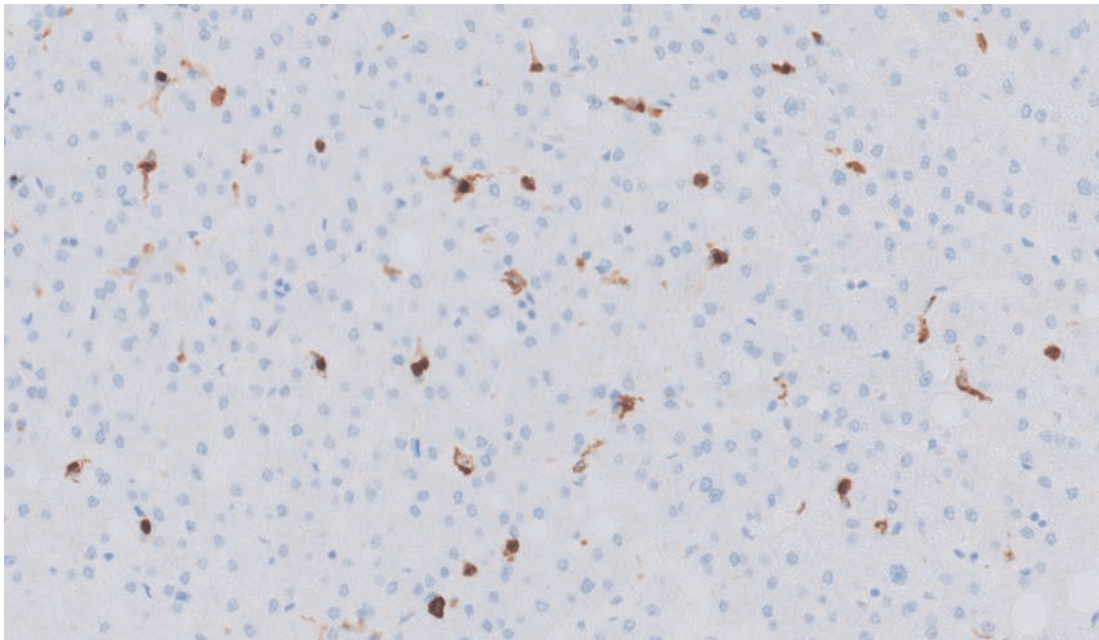
Appendix (20x)



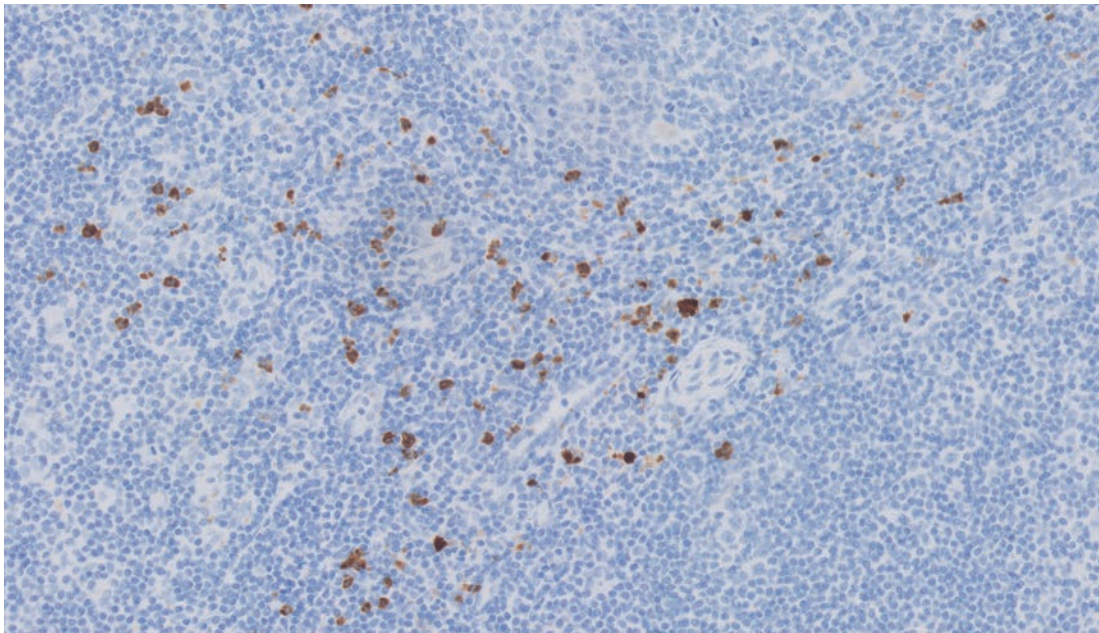
Colon (20x)

**Antibody:** Polyclonal Rabbit Anti-Human  
**Clone:** Myeloperoxidase  
**Code:** Polyclonal  
 GA511 | IR511

Reaction Location	Cytoplasm	
Quality Control	Liver	Tonsil
High Expression	Neutrophils and Kupffer cells show a moderate to strong granular cytoplasmic staining reaction.	Neutrophils and eosinophils in the interfollicular zones and the germinal center macrophages show a moderate to strong granular cytoplasmic staining reaction.
Low Expression	NA	NA
Non-expression	Hepatocytes (or only weak staining reaction).	NA



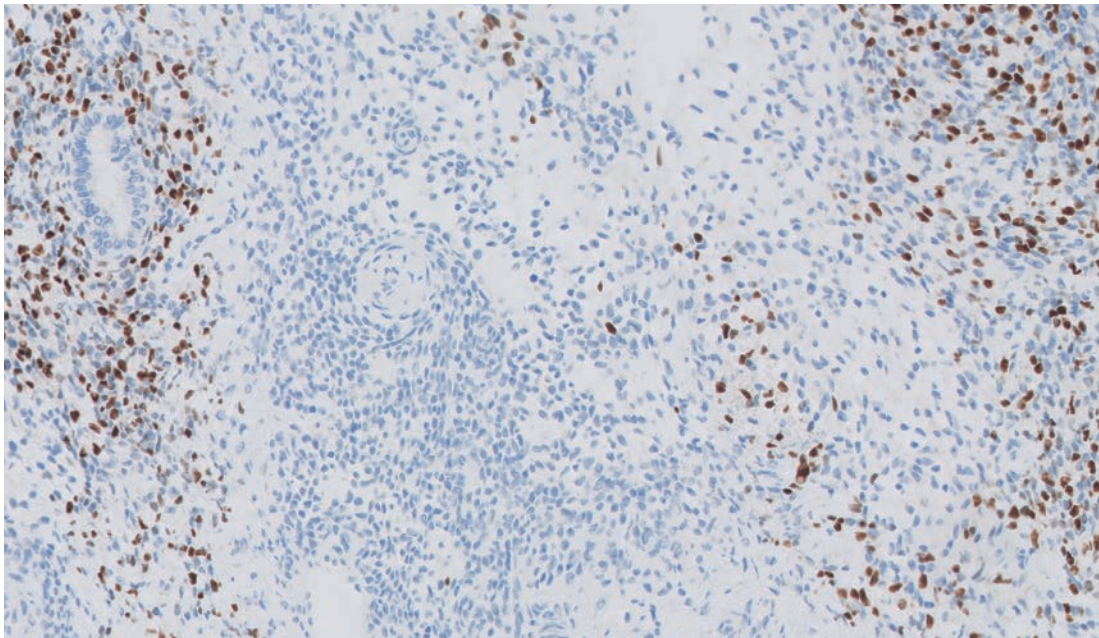
Liver (20x)



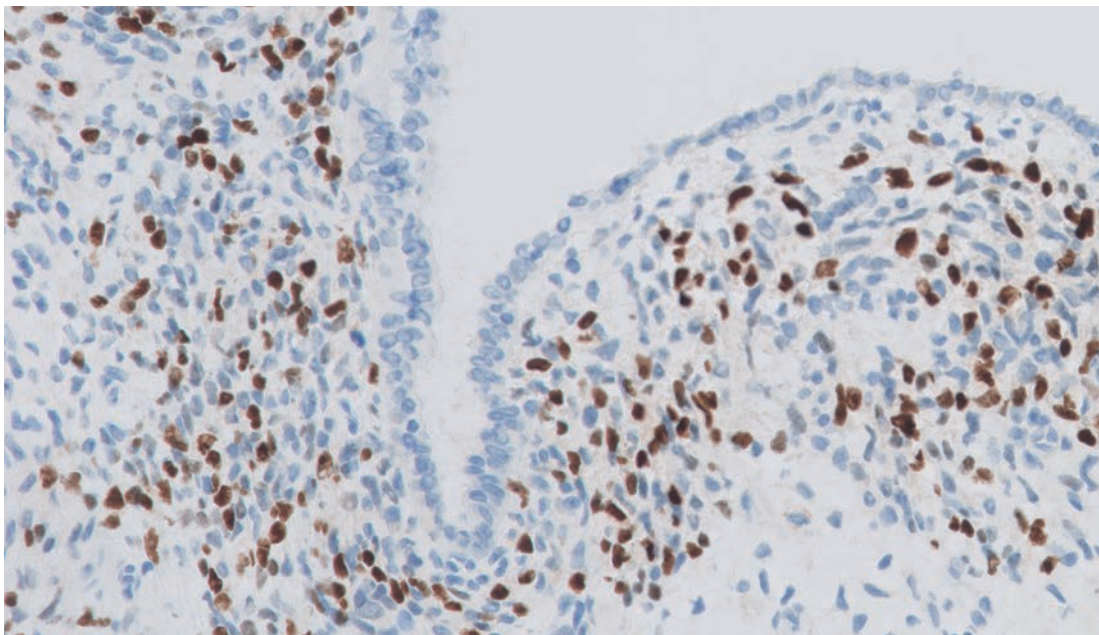
Tonsil (20x)

**Antibody:** Monoclonal Mouse Anti-Myogenin  
**Clone:** F5D  
**Code:** GA067 | IR067

Reaction Location	Nucleus	
Quality Control	Rhabdomyosarcoma	Leiomyosarcoma (not shown)
High Expression	At least focally, neoplastic cells show a moderate to strong nuclear staining reaction and no, or only a minimal, cytoplasmic staining reaction.	NA
Low Expression	NA	NA
Non-expression	NA	Neoplastic cells.



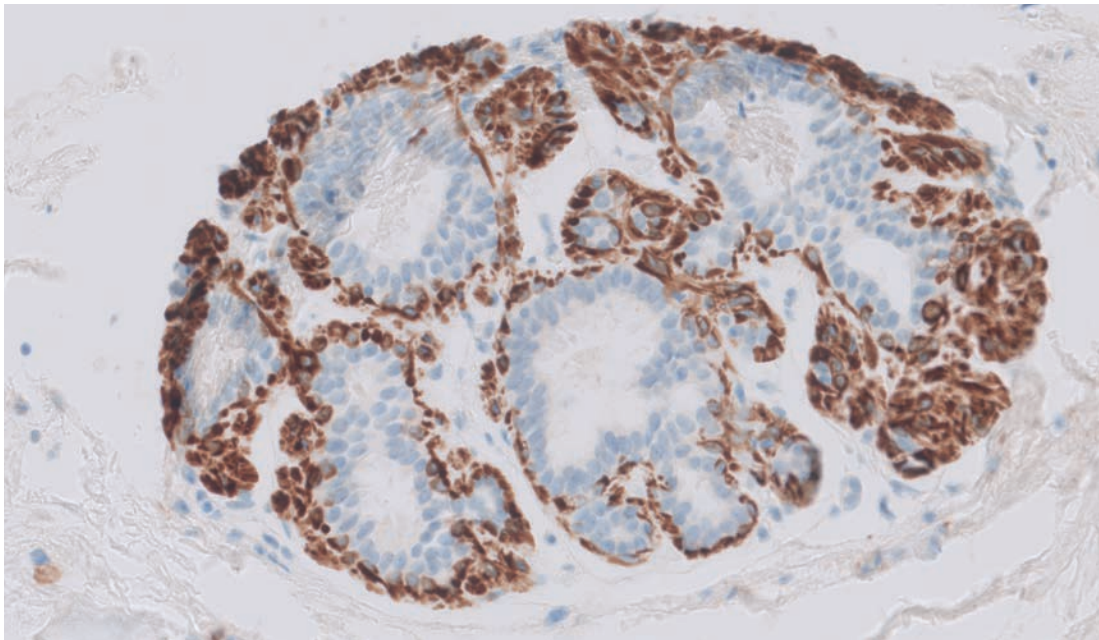
Rhabdomyosarcoma (10x)



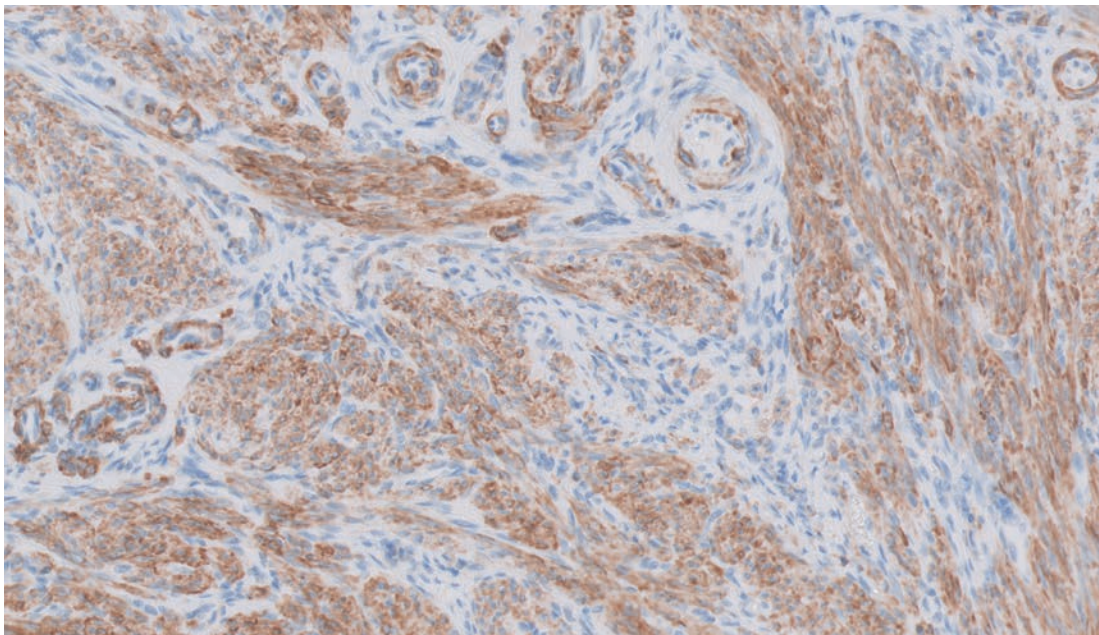
Rhabdomyosarcoma (20x)

**Antibody:** Monoclonal Mouse Anti-Human  
**Clone:** Myosin Heavy Chain (Smooth Muscle)  
**Code:** SMMS-1  
 IR066

Reaction Location	Cytoplasm	
Quality Control	Breast	Uterus
High Expression	Myoepithelial show a moderate to strong staining reaction.	NA
Low Expression	Smooth muscle cells of small vessels show a weak to moderate staining reaction.	Smooth muscle cells of the myometrium show a weak to moderate staining reaction.
Non-expression	Epithelial cells.	NA



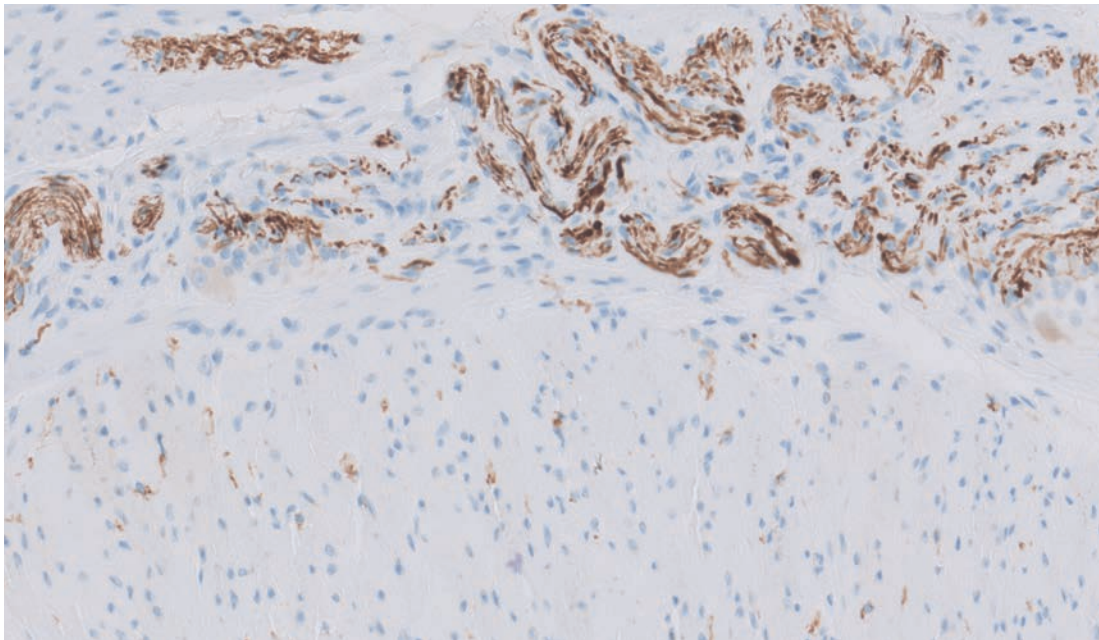
Breast (20x)



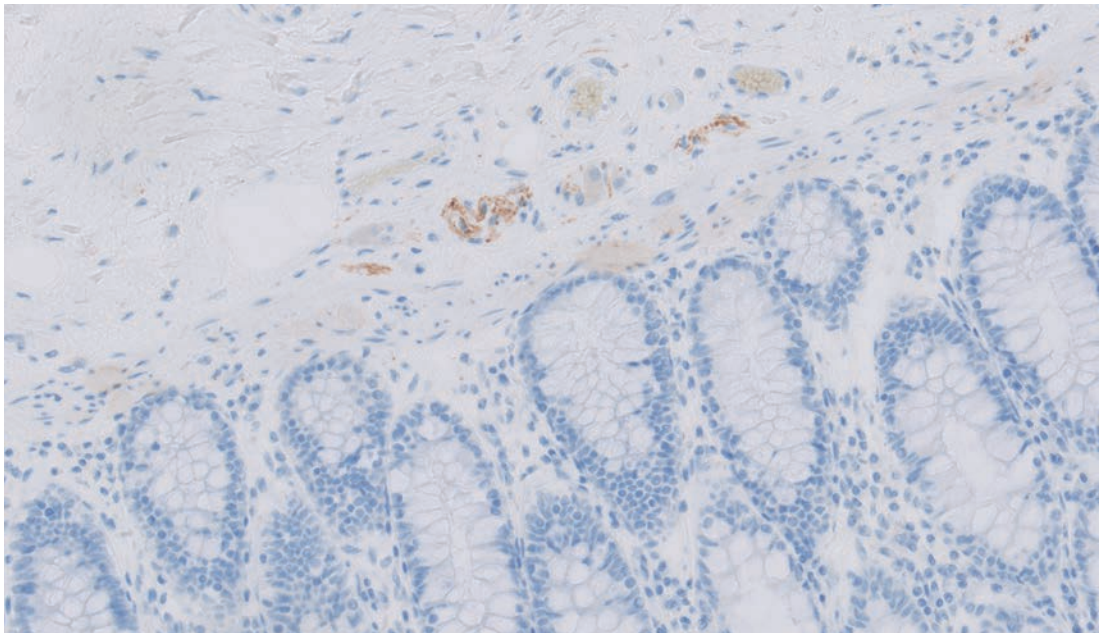
Uterus (20x)

**Antibody:** Monoclonal Mouse Anti-Human  
**Neurofilament Protein**  
**Clone:** 2F11  
**Code:** GA607 | IR607

Reaction Location	Cytoplasm
Quality Control	Colon/Appendix
High Expression	Large axons and ganglion cells in Auerbach's plexus show a moderate to strong staining reaction.
Low Expression	Isolated axons in the muscularis externa show a weak to moderate staining reaction.
Non-expression	Smooth muscle cells and epithelium



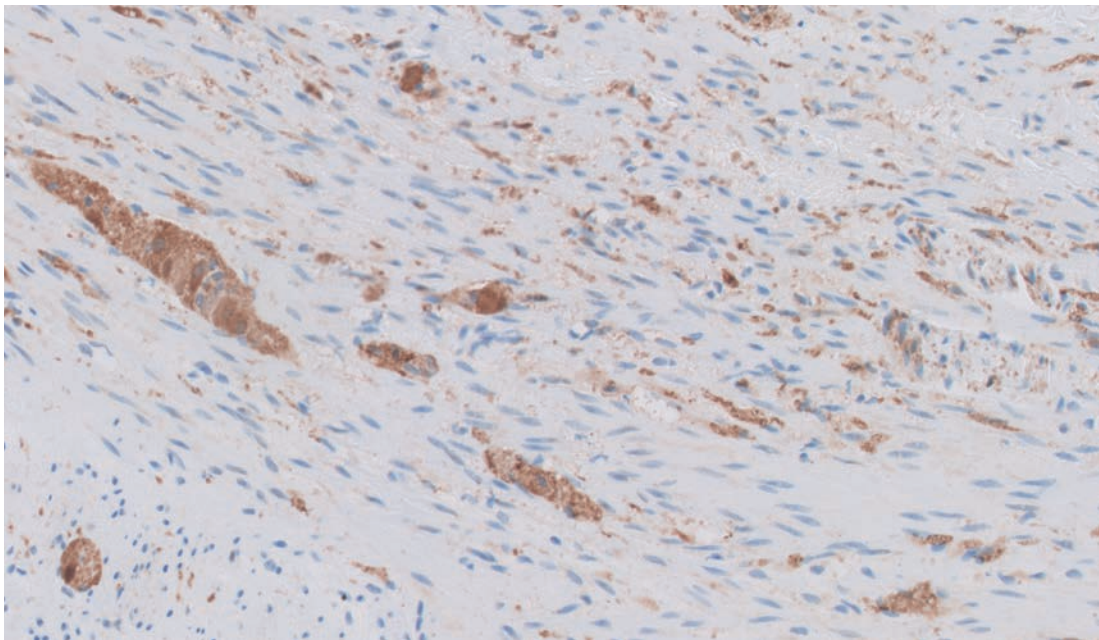
Colon (20x)



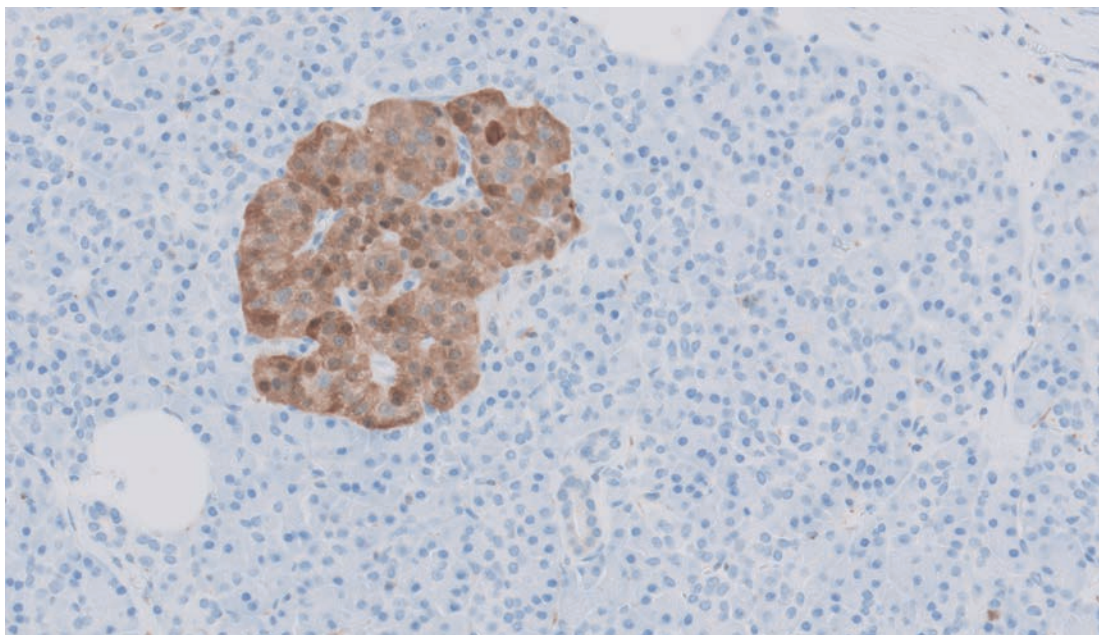
Colon (20x)

**Antibody:** Monoclonal Mouse Anti-Human  
**Clone:** Neuron-Specific Enolase  
**Code:** BBS/NC/VI-H14  
 IR612

Reaction Location	Nucleus and cytoplasm	
Quality Control	Colon/Appendix	Pancreas
High Expression	Ganglion cells of the Auerbach's plexus show a moderate to strong cytoplasmic and nuclear staining reaction.	Langerhans' islets and single neuroendocrine cells in the pancreatic ducts show a moderate to strong granular cytoplasmic and nuclear staining reaction.
Low Expression	Isolated axons in the muscularis externa show a weak to moderate cytoplasmic staining reaction.	NA
Non-expression	Epithelial cells.	NA



Appendix (20x)

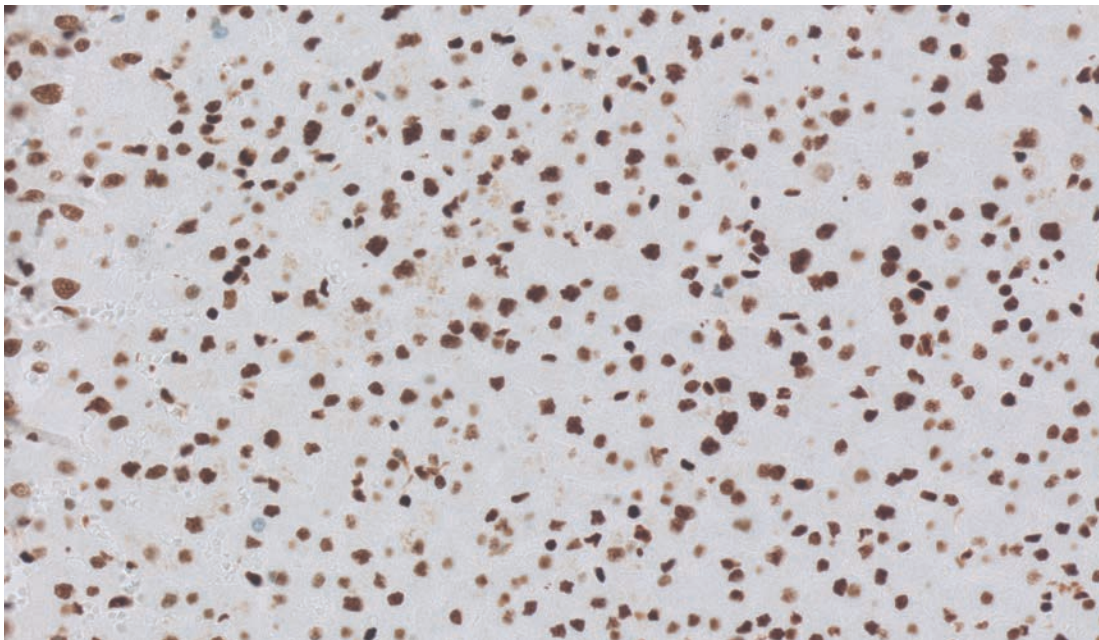


Pancreas (20x)

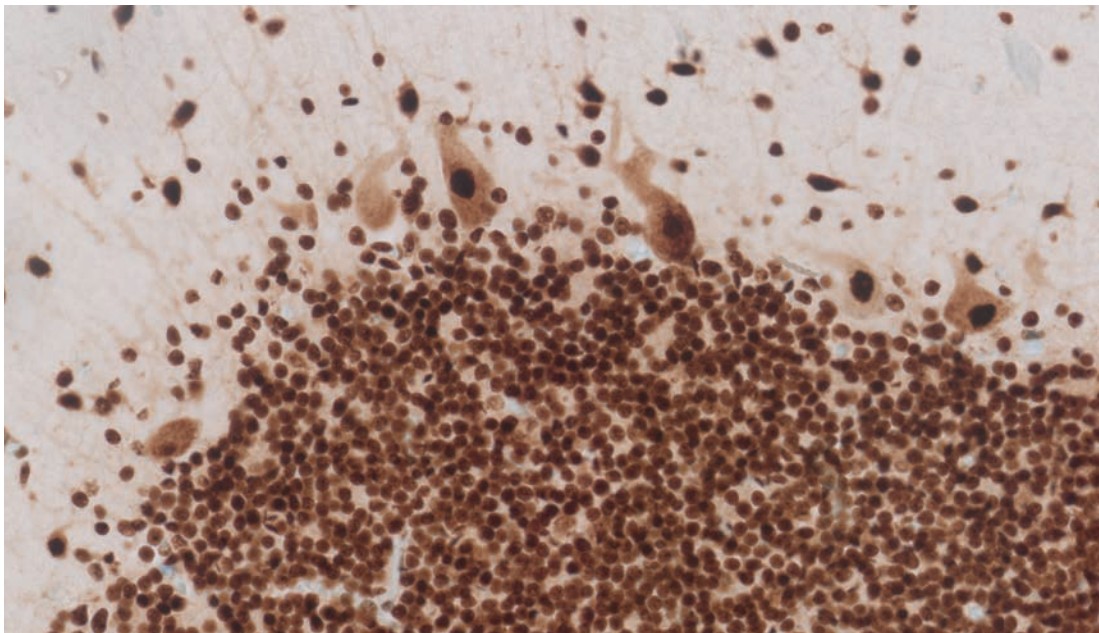
**Antibody:** Monoclonal Mouse Anti-Human  
**Clone:** Nucleophosmin  
**Code:** 376  
 GA652 | IR652

Reaction Location	Nucleus and cytoplasm	
Quality Control	Liver	Brain
High Expression	The vast majority of hepatocytes show a moderate to strong nuclear staining reaction.	Normal neurons show a moderate to strong distinct nuclear staining reaction.
Low Expression	Scattered mitotic and post-mitotic cells show a weak to moderate cytoplasmic and nuclear staining reaction.	Large Purkinje cells and some small neurons show a weak to moderate cytoplasmic staining reaction.
Non-expression	NA	NA

Note: Some nuclei in liver and brain are negative.



Liver (20x)

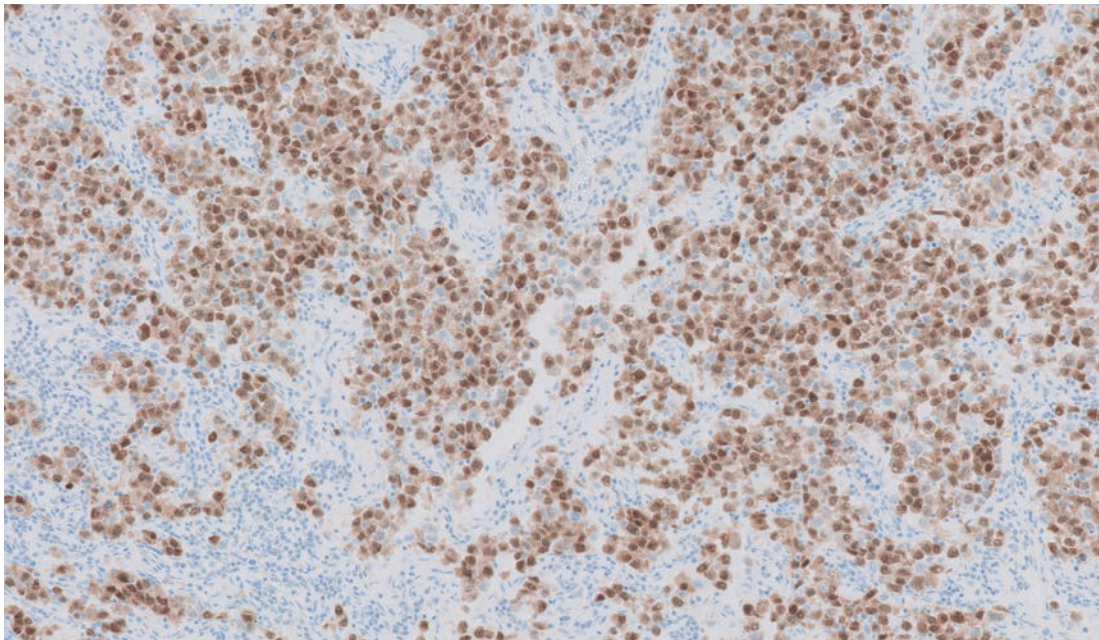


Brain (20x)

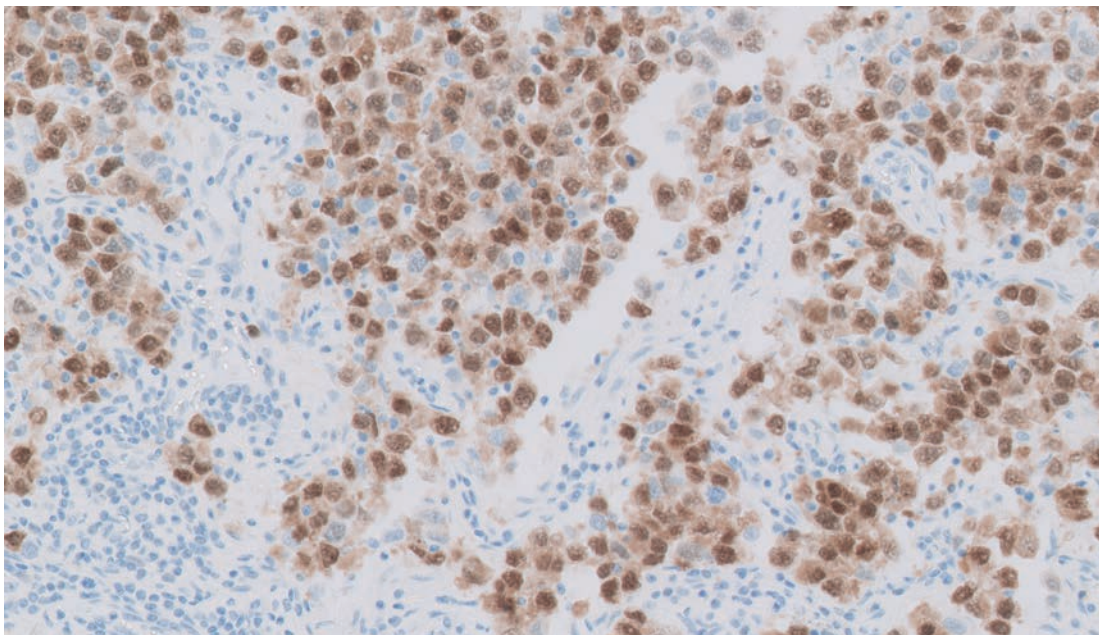
**Antibody:** Monoclonal Mouse Anti-Human  
**Clone:** Octamer-Binding Transcription Factor 3/4  
**Code:** N1NK  
 IR092

Reaction Location	Nucleus
Quality Control	<b>Seminoma</b>
High Expression	The majority of neoplastic cells show a moderate to strong staining reaction.
Low Expression	NA
Non-expression	Placenta or colon/appendix can serve as negative tissue control showing no nuclear staining reaction.

Note: Weakly positive immunostaining in the cytoplasm of epithelial cells was observed in epithelia of the testis, stomach, and small intestine.



Seminoma (10x)



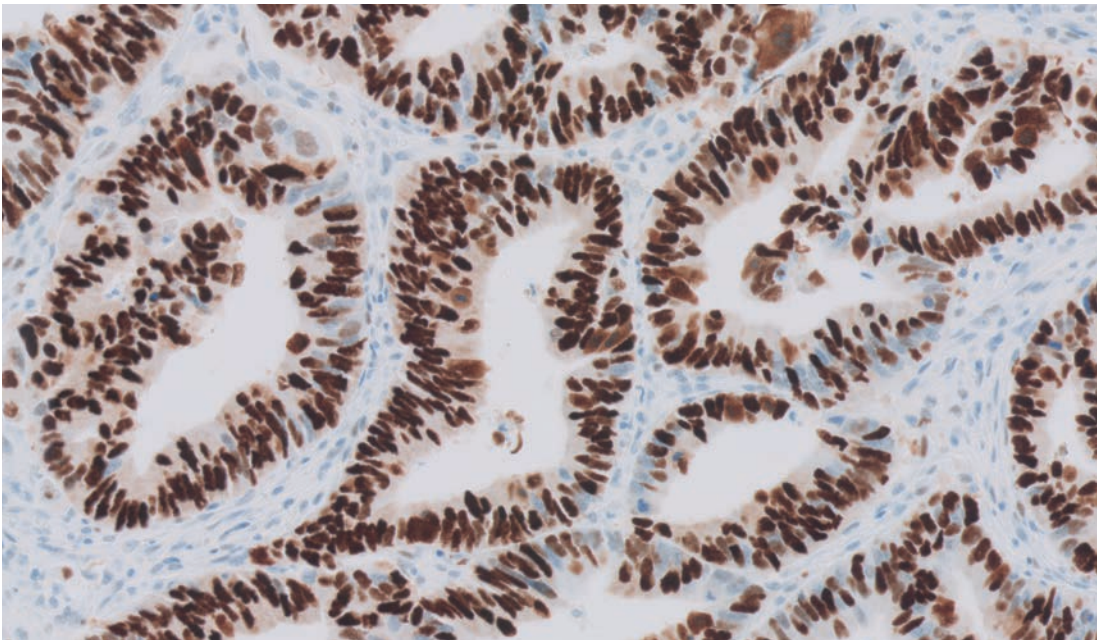
Seminoma (20x)



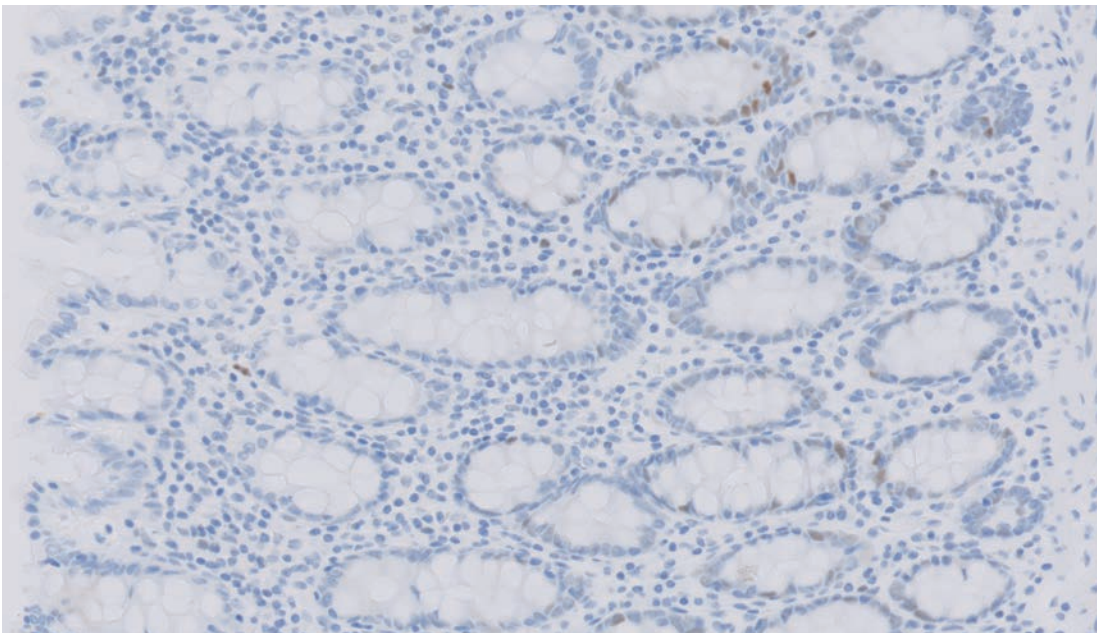
**Antibody:** Monoclonal Mouse Anti-Human  
**Clone:** p53 Protein  
**Code:** DO-7  
 GA616 | IR616

Reaction Location	Nucleus	
Quality Control	Colon adenocarcinoma	Colon/Appendix
High Expression	Neoplastic cells show a moderate to strong staining reaction.	NA
Low Expression	Scattered benign basal epithelial cells show a weak to moderate staining reaction.	Scattered basal epithelial cells show a weak to moderate staining reaction.
Non-expression	The vast majority of normal epithelial cells.	The vast majority of normal epithelial cells.

Note: Basal cells may show a weak to moderate nuclear staining reaction.



Colon adenocarcinoma (20x)

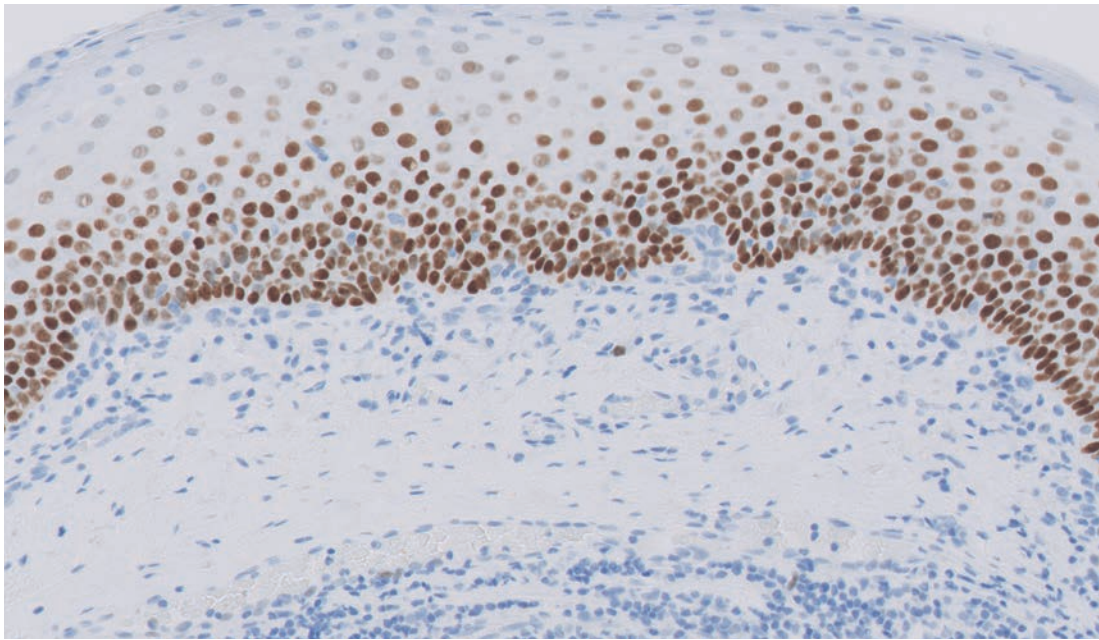


Colon (20x)

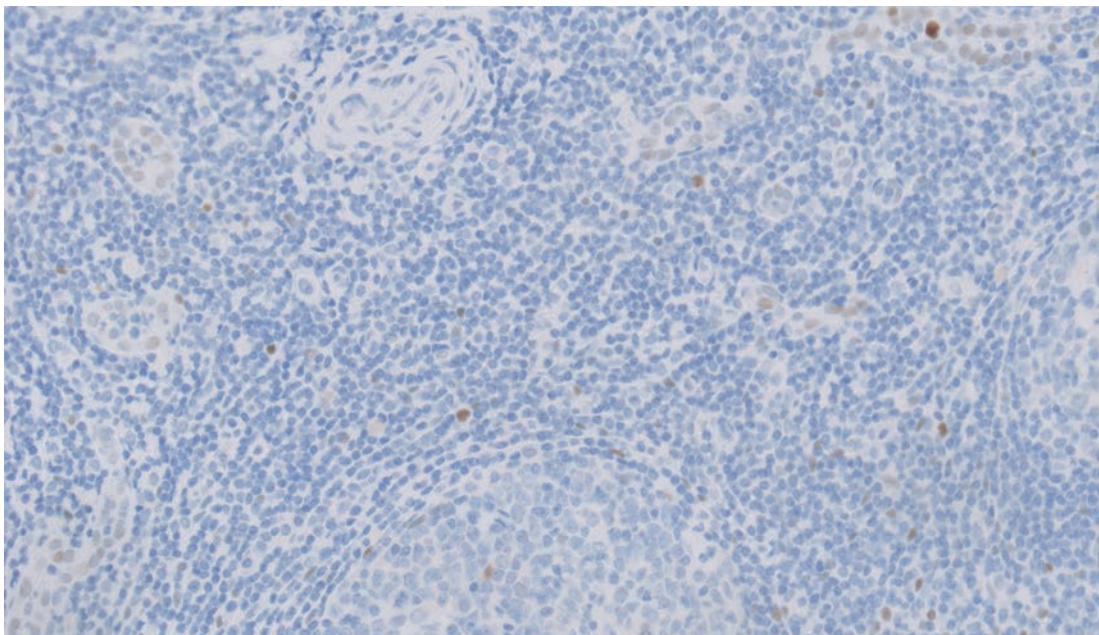
**Antibody:** Monoclonal Mouse Anti-Human  
**Clone:** p63 Protein  
**Code:** DAK-p63  
 GA662 | IR662

Reaction Location	Nuclear
Quality Control	Tonsil
High Expression	Squamous epithelial cells show a moderate to strong staining reaction.
Low Expression	Dispersed lymphocytes and endothelial cells show a weak to moderate staining.
Non-expression	NA

Note: Occasionally, cytoplasmic labeling of granulocytes may be observed.



Tonsil (20x)

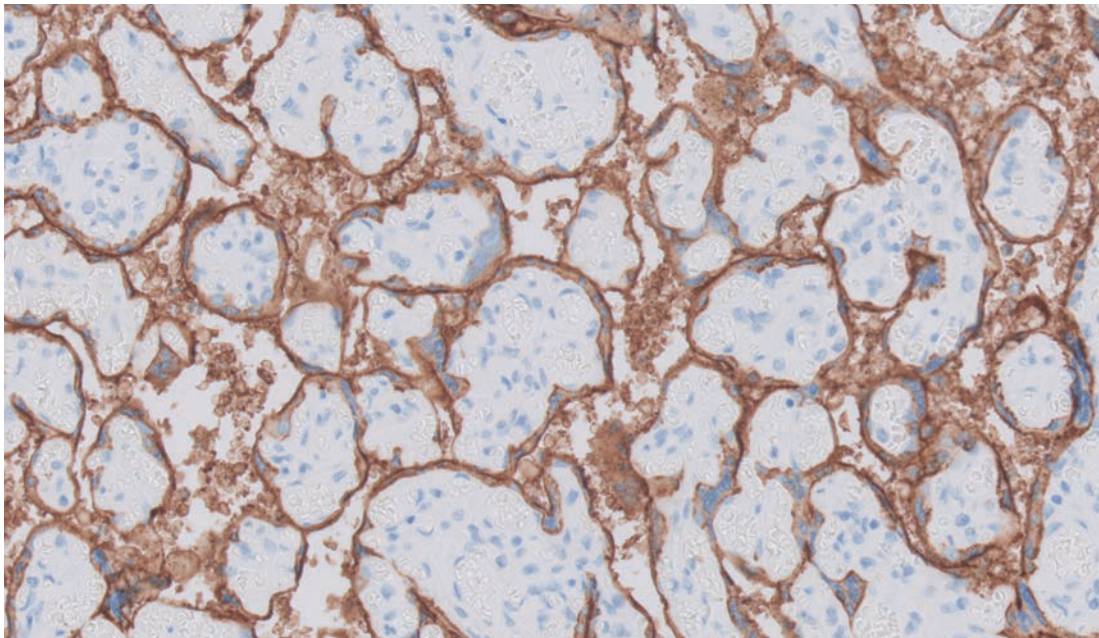


Tonsil (20x)

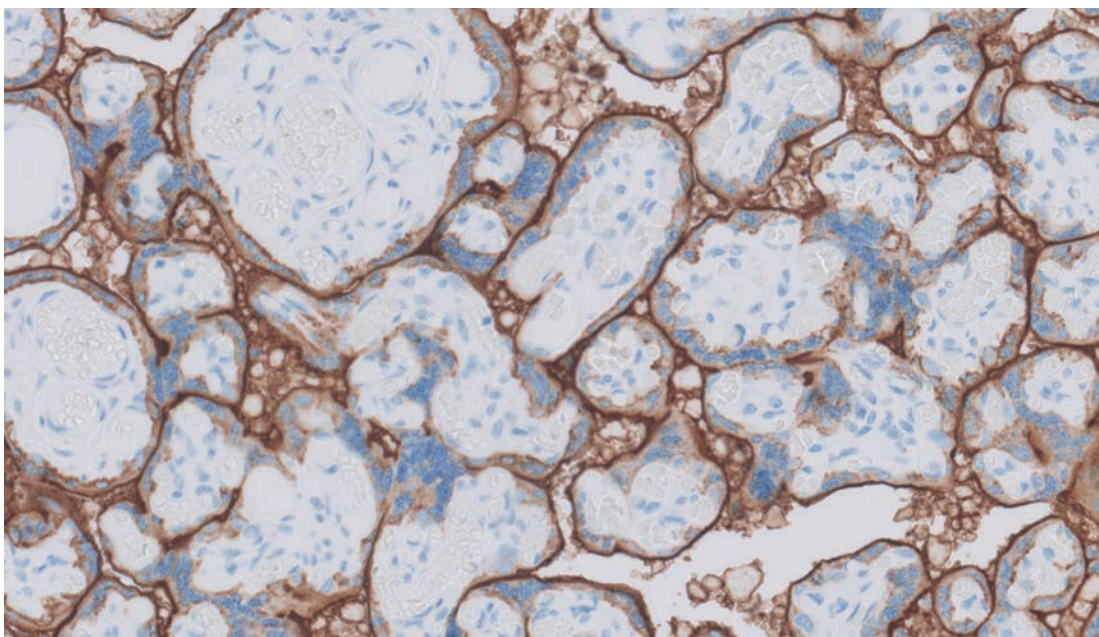
**Antibody:** Monoclonal Mouse Anti-Human  
**Placental Alkaline Phosphatase**  
**Clone:** 8A9  
**Code:** IR779

Reaction Location	Membrane and cytoplasm
Quality Control	Placenta
High Expression	The brush border of the syncytiotrophoblast and trophoblast shows a moderate to strong, predominantly membranous, staining reaction.
Low Expression	Cytoplasmic compartment of the syncytiotrophoblast and trophoblast shows a weak to moderate staining reaction.
Non-expression	NA

Note: Some cytoplasmic staining in the smooth muscle cells and myofibroblasts is acceptable.



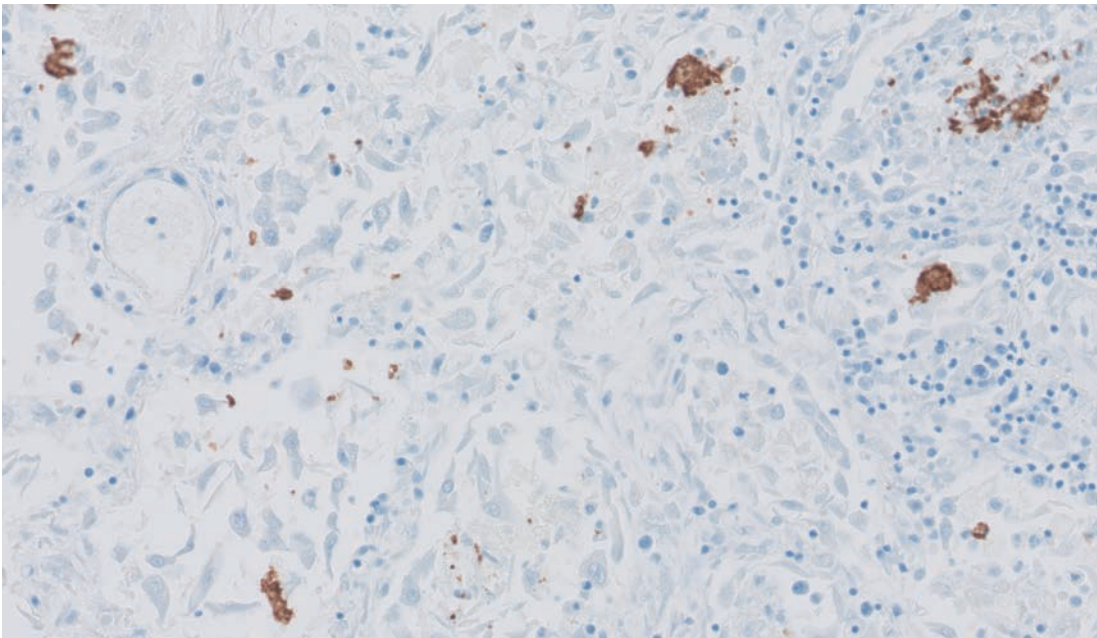
Placenta (20x)



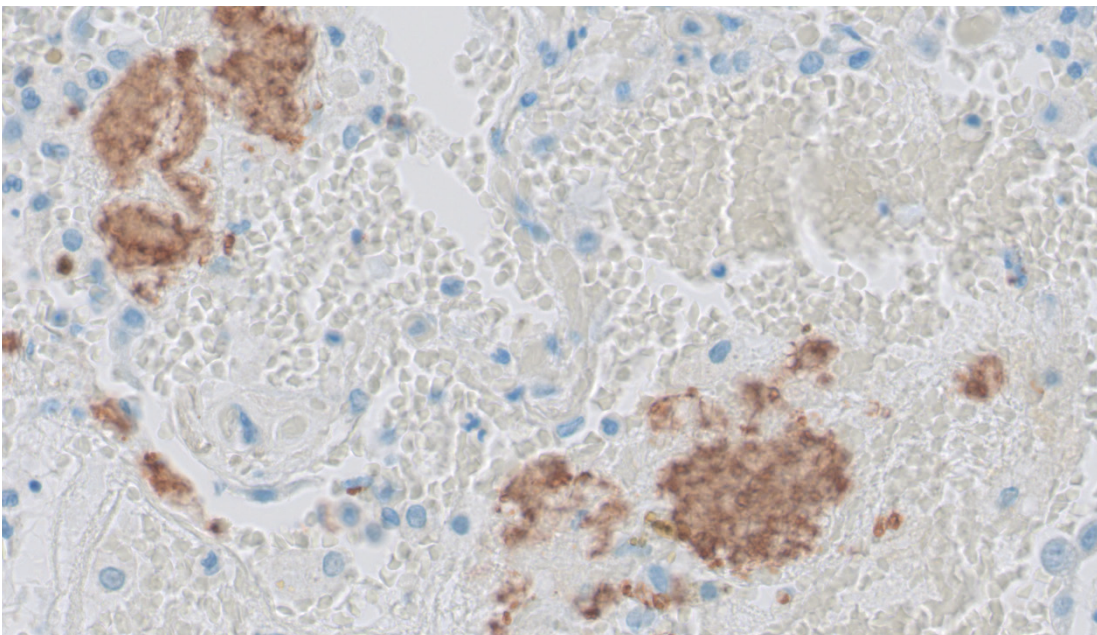
Placenta (20x)

Antibody: Monoclonal Mouse Anti-  
Pneumocystis Jiroveci  
Clone: 3F6  
Code: IR635

Reaction Location	Membrane
Quality Control	Lung (P. jiroveci infection)
High Expression	P. jiroveci cyst walls show a moderate to strong staining reaction.
Low Expression	Trophozoites show a weak to moderate, diffuse and granular, staining reaction.
Non-expression	Epithelial or lymphatic cells.



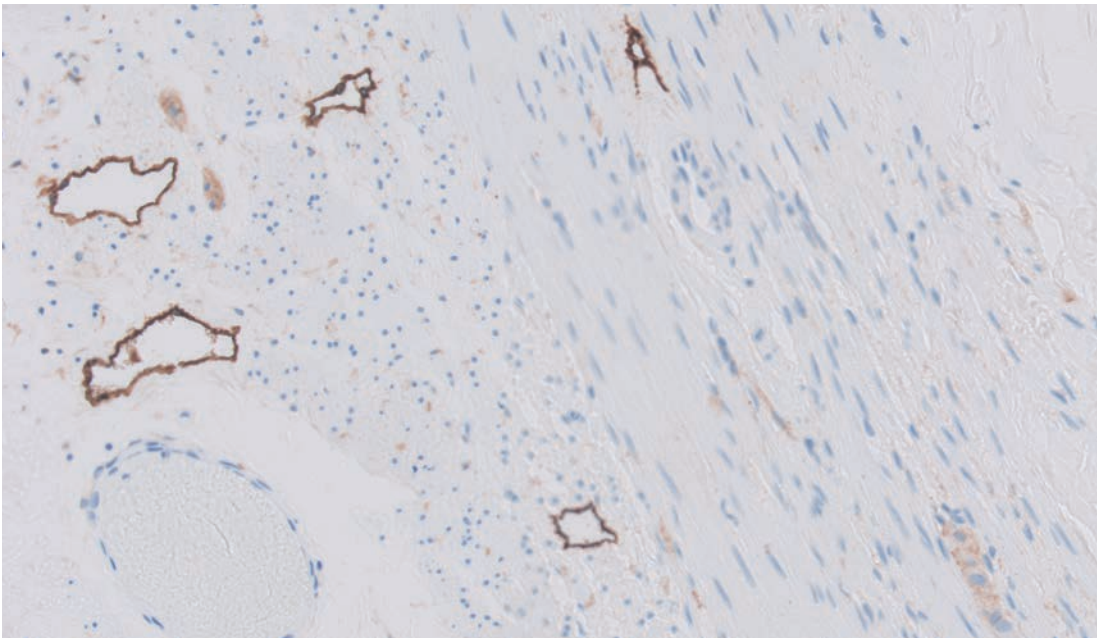
Lung (20x)



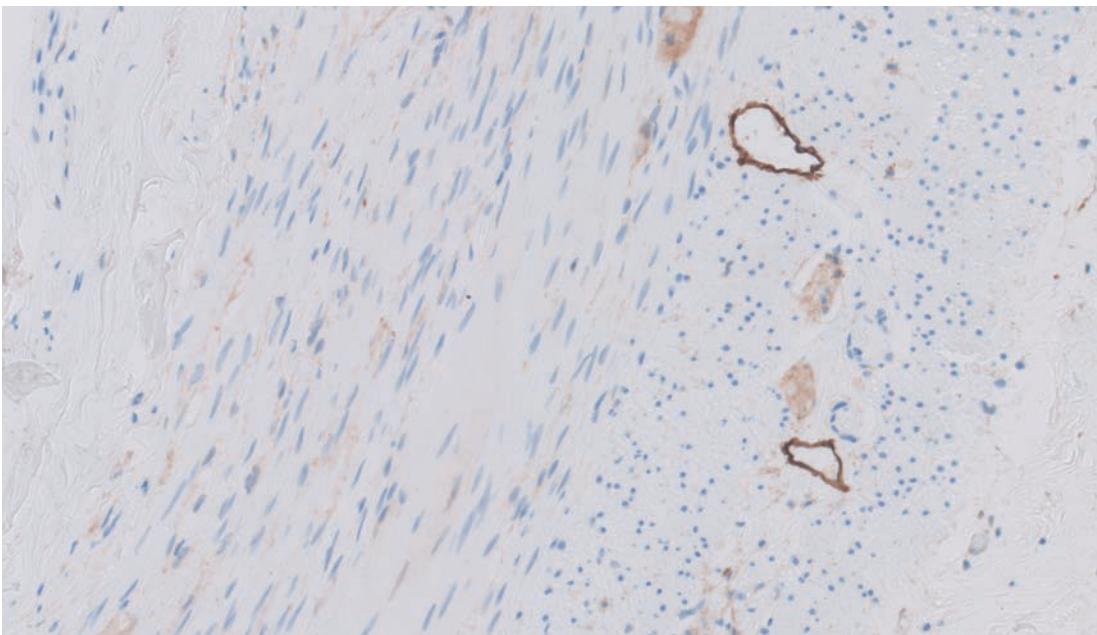
Lung (40x)

**Antibody:** Monoclonal Mouse Anti-Human Podoplanin  
**Clone:** D2-40  
**Code:** IR072

Reaction Location	Membrane and cytoplasm
Quality Control	<b>Appendix</b>
High Expression	Lymphatic endothelial cells show a moderate to strong predominantly cytoplasmic staining reaction.
Low Expression	Cajal cells of the muscularis propria show a weak to moderate predominantly membranous staining reaction.
Non-expression	Vascular endothelial cells.



Appendix (20x)

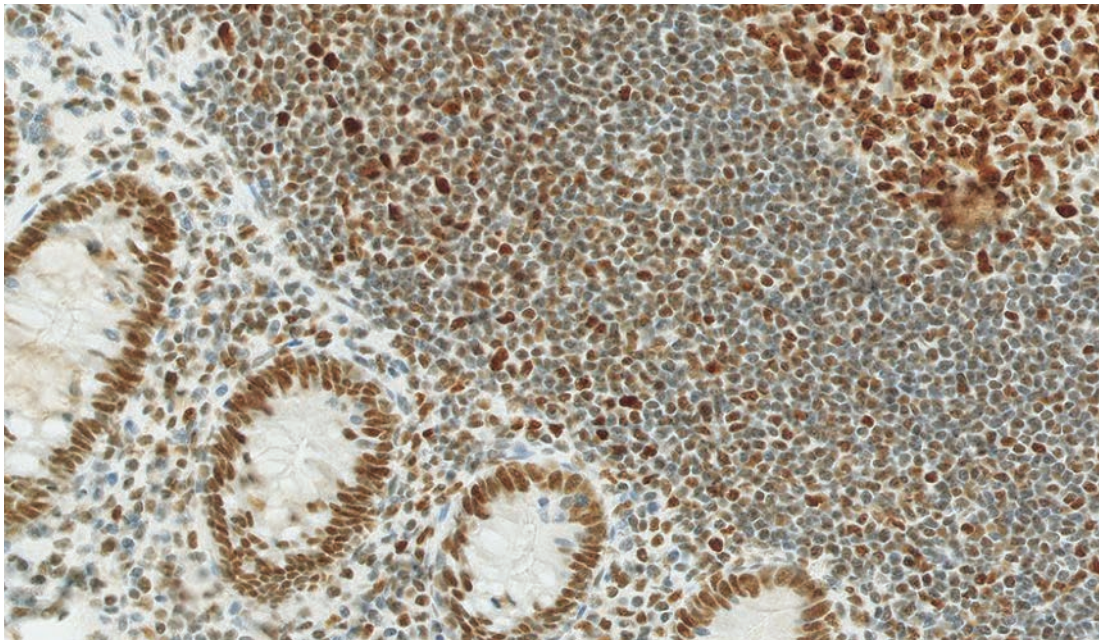


Appendix (20x)

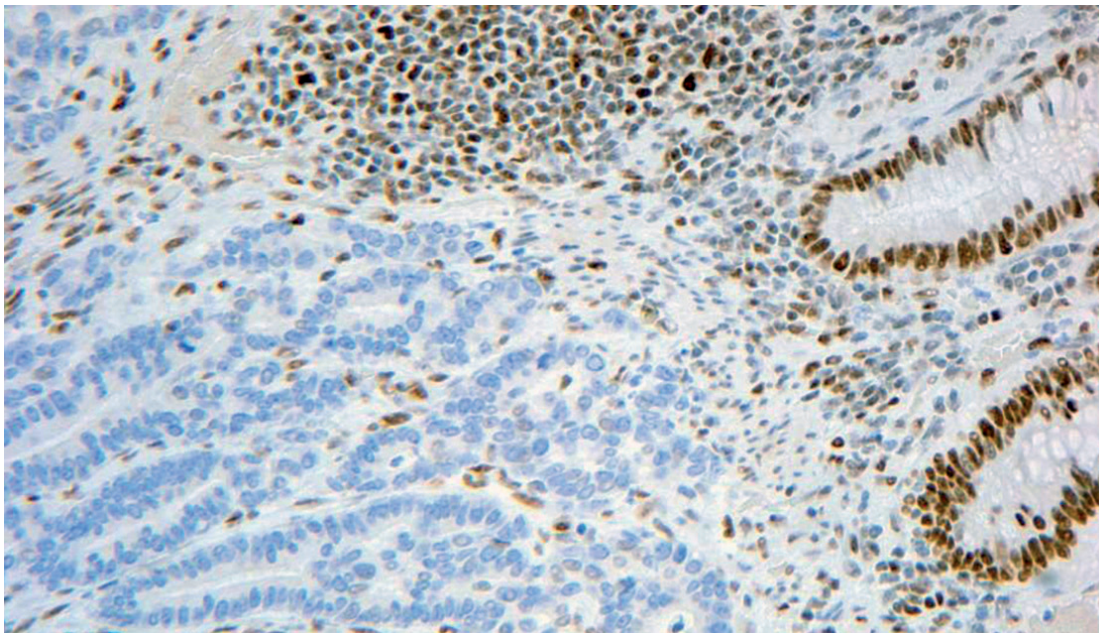
**Antibody:** Monoclonal Rabbit Anti-Human  
**Clone:** Postmeiotic Segregation Increased 2 (PSM2)  
**Code:** EP51  
 IR087 *Not available in the US*

Reaction Location	Nucleus
Quality Control	Colon/Appendix
High Expression	Virtually all cells show a distinct nuclear staining reaction. The basal epithelial cells and germinal center cells in lymphoid follicles show a moderate to strong staining reaction.
Low Expression	Luminal epithelial cells and stromal cells should at least show a weak to moderate staining reaction.
Non-expression	NA

Note: Delayed fixation or long term storage of cut sections may reduce staining intensity which may impact interpretation.



Appendix (20x)

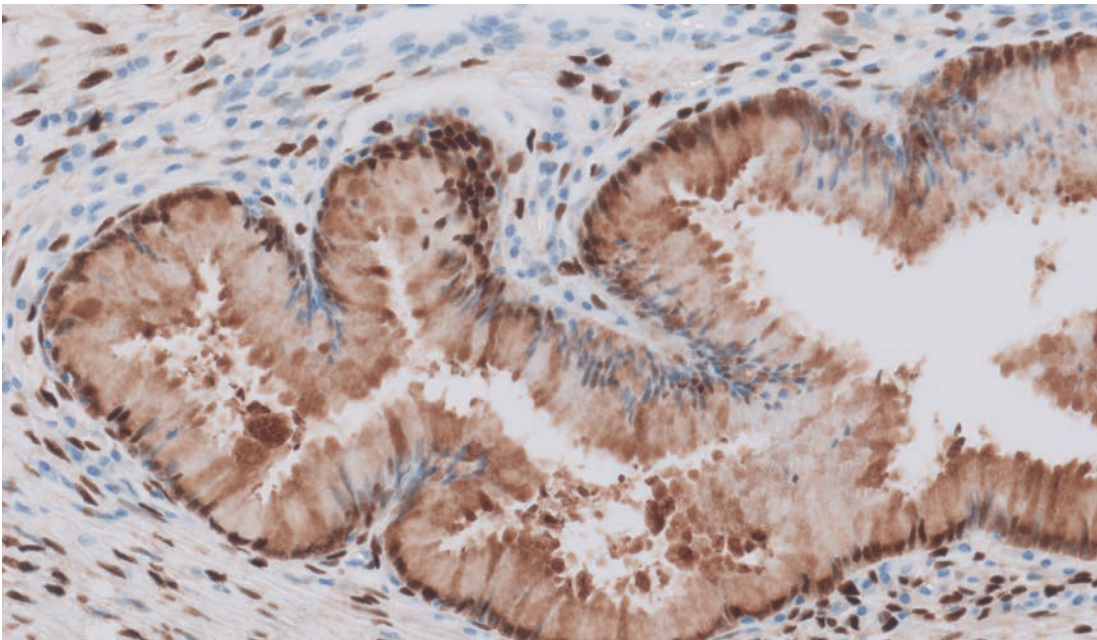


Colon adenocarcinoma (20x)

**Antibody:** Monoclonal Mouse Anti-Human  
**Clone:** Progesterone Receptor  
**Code:** PgR 636  
IR068

Reaction Location	Nucleus
Quality Control	Cervix
High Expression	Columnar epithelial cells and the stromal cells show a moderate to strong staining reaction.
Low Expression	NA
Non-expression	No staining reaction should be seen in tonsil.

Note: Some cytoplasmic staining is acceptable.

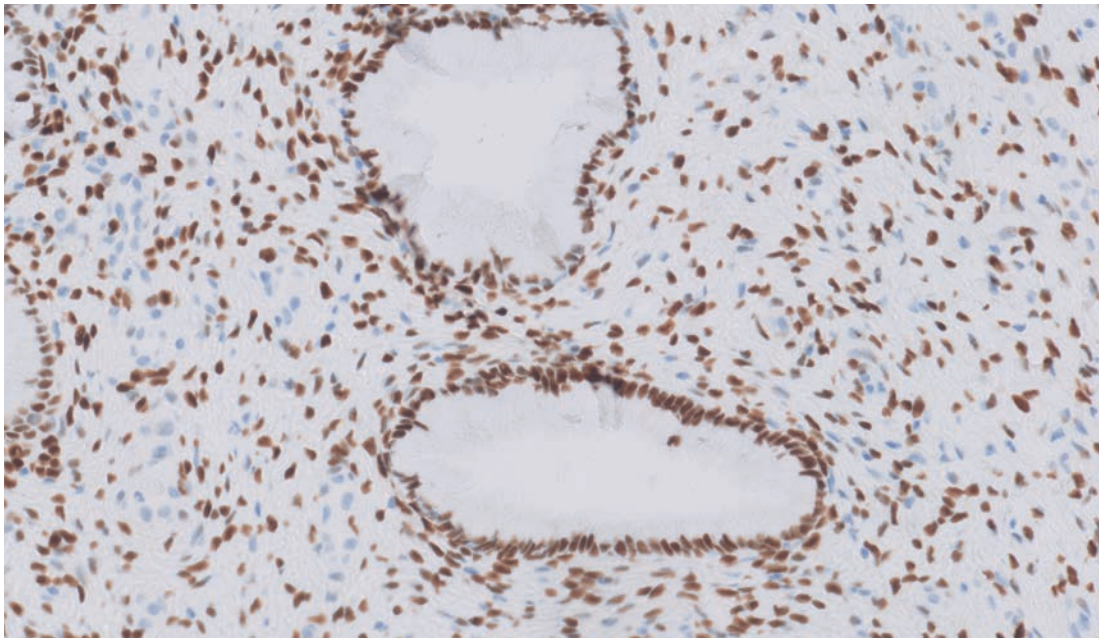


Cervix (20x)

**Antibody:** Monoclonal Mouse Anti-Human  
**Clone:** Progesterone Receptor  
**Code:** PgR 1294  
GA090

Reaction Location	Nucleus
Quality Control	Cervix
High Expression	Columnar epithelial cells show a moderate to strong staining reaction.
Low Expression	NA
Non-expression	No nuclear staining reaction should be seen in tonsil.

Note: Not all uterine cervix will show the described staining pattern. Cytoplasmic labeling, if observed, should be regarded as non-specific.



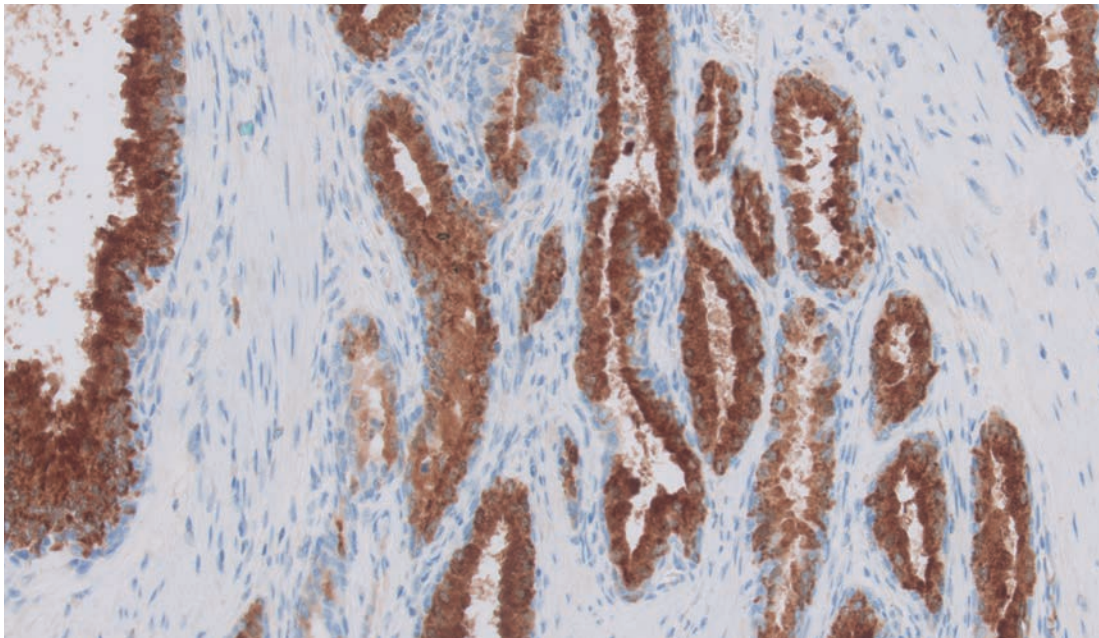
Cervix (20x)



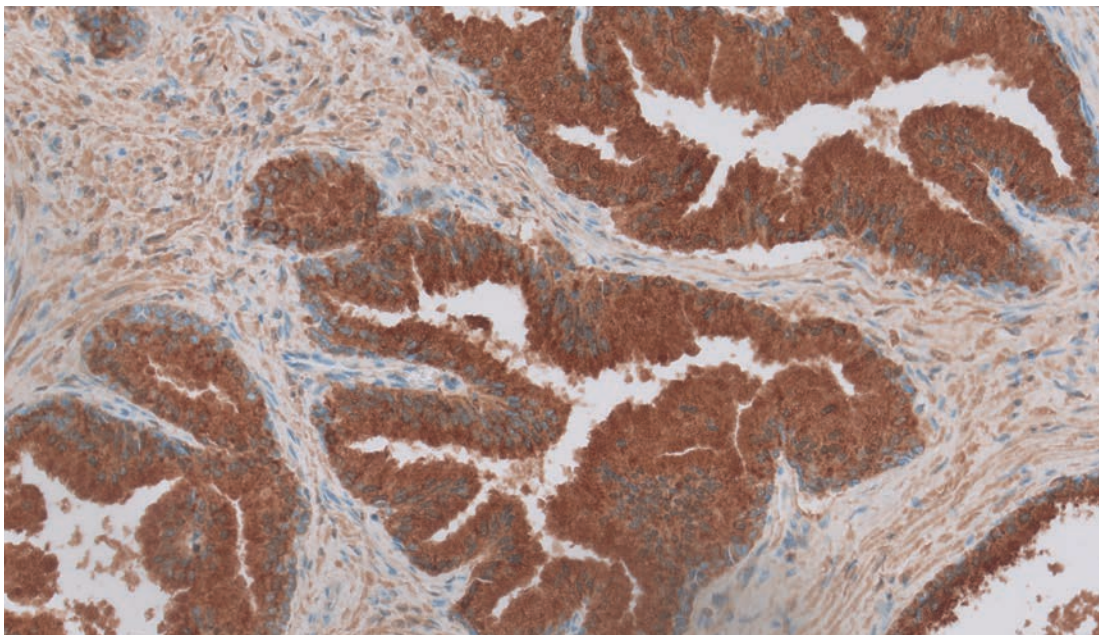
**Antibody:** Polyclonal Rabbit Anti-Human  
**Prostate-Specific Antigen**  
**Clone:** Polyclonal  
**Code:** GA514 | IR514

Reaction Location	Cytoplasm
Quality Control	<b>Prostate</b>
High Expression	Columnar epithelial cells show a moderate to strong staining reaction.
Low Expression	Due to leakage of the antigen in vicinity of the prostate glands, a weak staining reaction of the stromal compartment is accepted.
Non-expression	No staining reaction should be seen in kidney and appendix tissues.

Note: Although PSA can be considered prostate-specific, PSA expression has been detected at low levels in some non-prostatic tissues.



Prostate (20x)

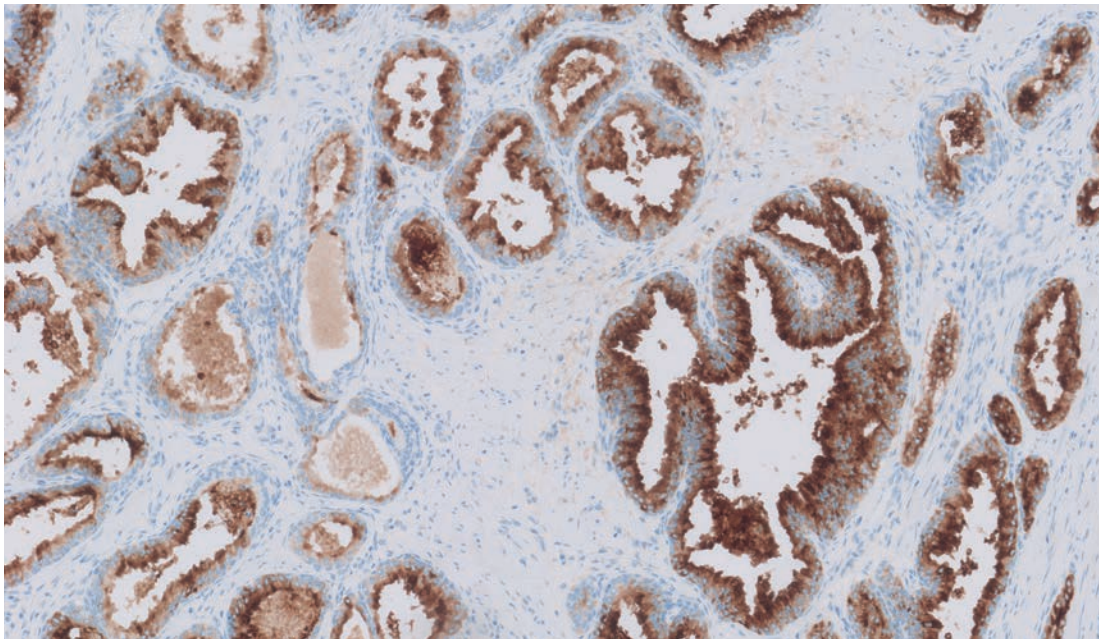


Prostate (20x)

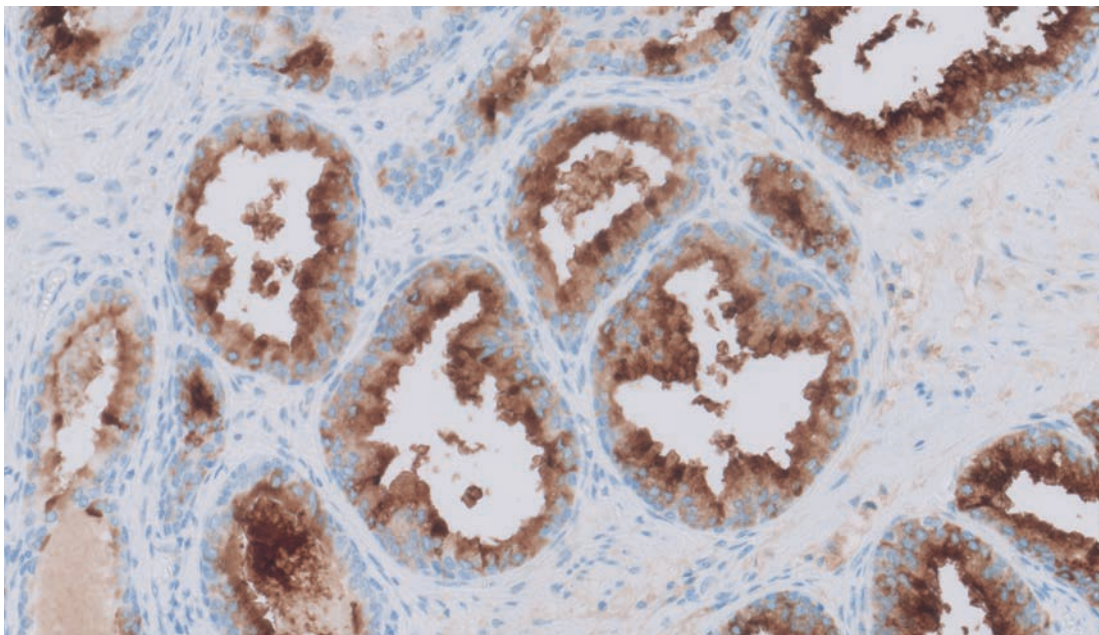
**Antibody:** Monoclonal Mouse Anti-Human  
**Prostate-Specific Membrane Antigen**  
**Clone:** 3E6  
**Code:** IR089

Reaction Location	Cytoplasm and/or membrane
Quality Control	<b>Prostate</b>
High Expression	Columnar epithelial cells show a moderate to strong staining reaction.
Low Expression	NA
Non-expression	NA

Note: Prostate-specific membrane antigen may also be expressed in a subset of non-prostatic tissues



Prostate (10x)

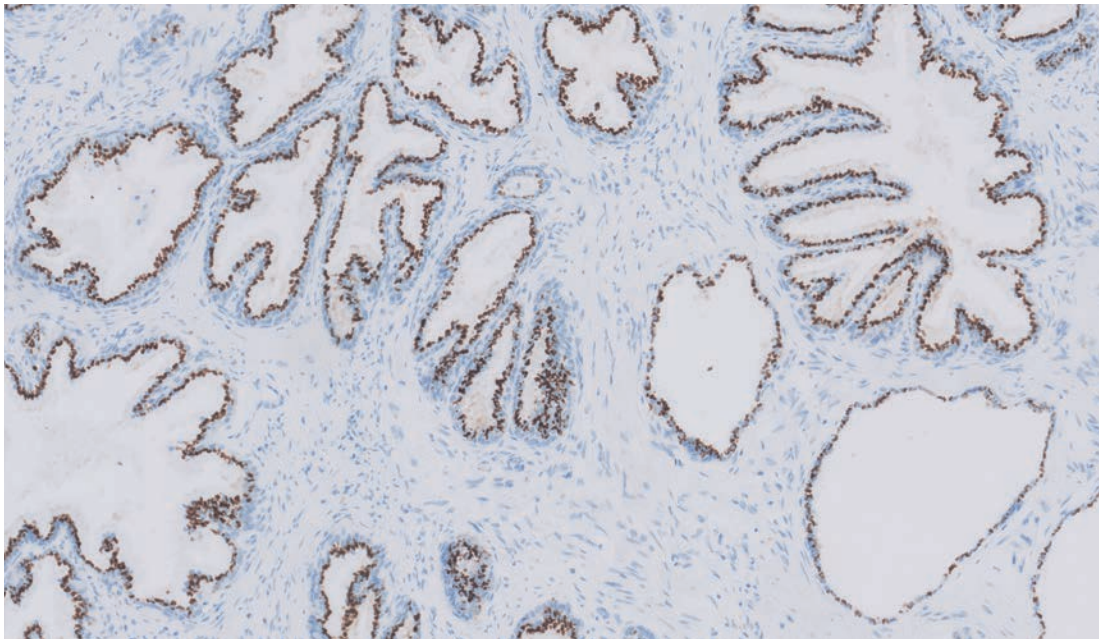


Prostate (20x)

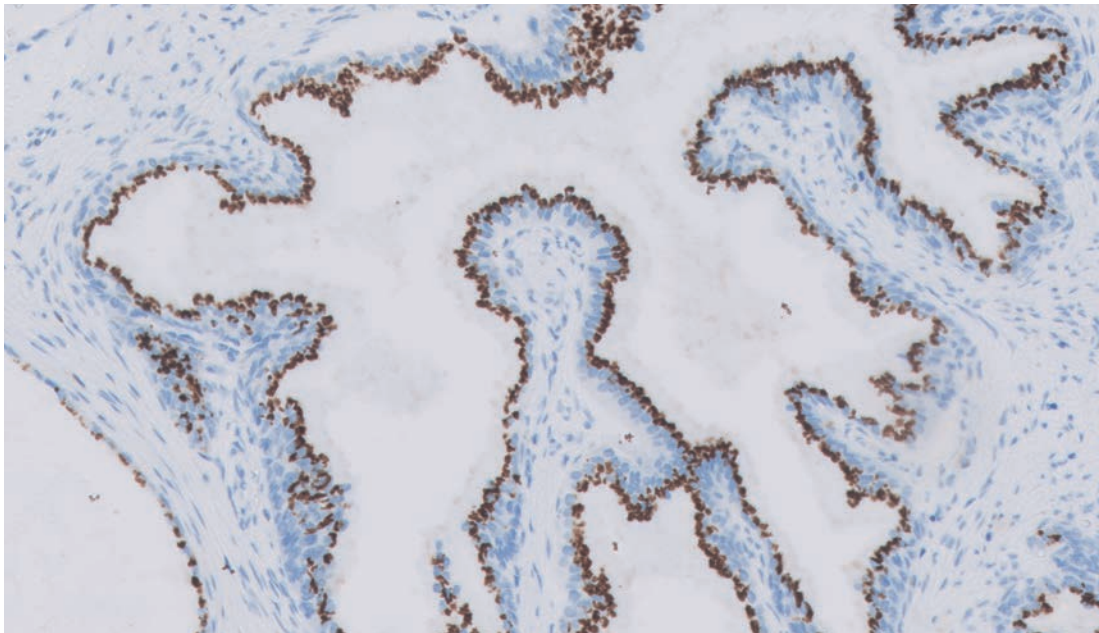
**Antibody:** Monoclonal Mouse Anti-Human  
**Clone:** Prostein  
**Code:** 10E3  
IR088

Reaction Location	Cytoplasm
Quality Control	Prostate
High Expression	Columnar epithelial cells show a moderate to strong granular staining reaction.
Low Expression	NA
Non-expression	All other cells in prostate.

Note: Prostein expression has not been detected in other normal or malignant glandular tissues with the exception of few urothelial carcinomas.



Prostate (10x)

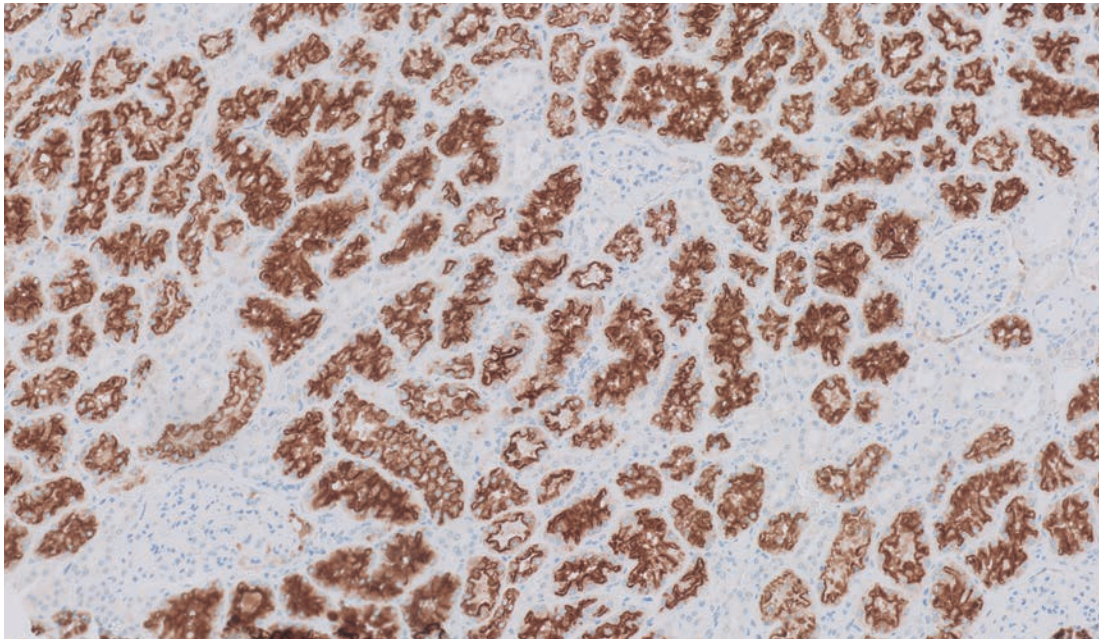


Prostate (20x)

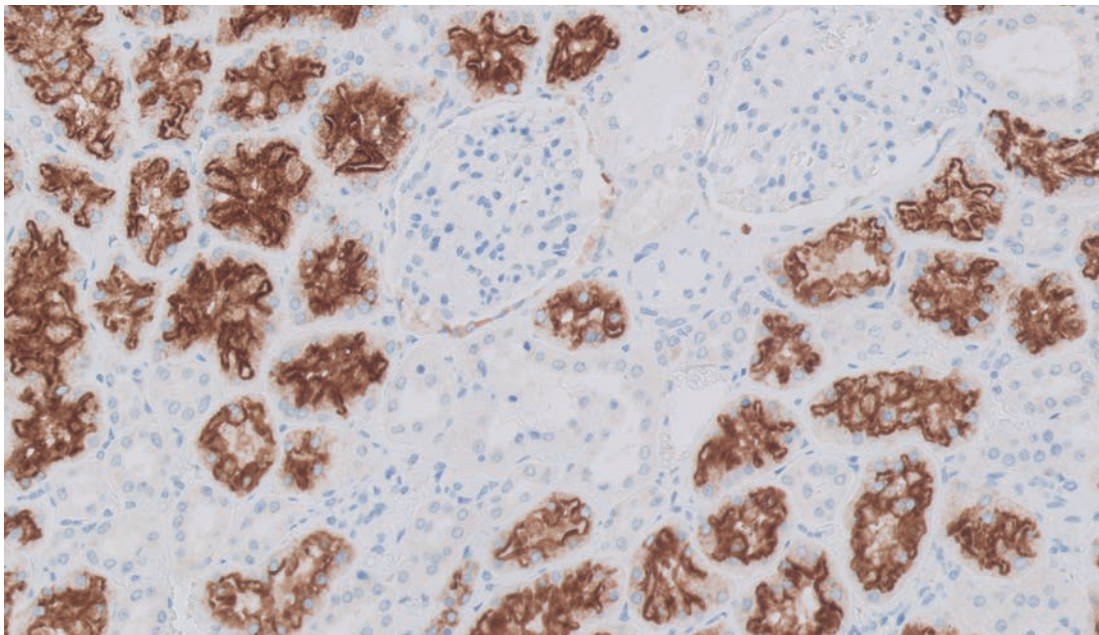
**Antibody:** Monoclonal Mouse Anti-Human  
**Renal Cell Carcinoma Marker**  
**Clone:** SPM314  
**Code:** GA075 | IR075

Reaction Location	Membrane
Quality Control	Kidney
High Expression	Epithelial cells of the proximal tubules show a moderate to strong, predominantly membranous, staining reaction.
Low Expression	Epithelial cells in focal areas of the Bowman's capsule show weak to moderate staining reaction.
Non-expression	NA

Note: Cytoplasmic staining may be observed.



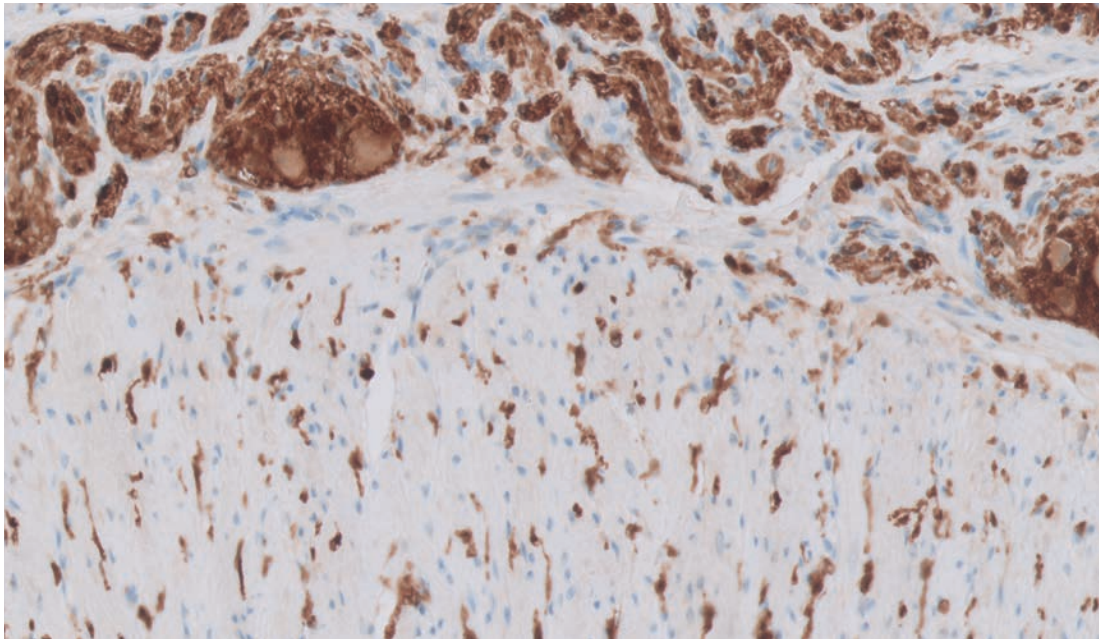
Kidney (10x)



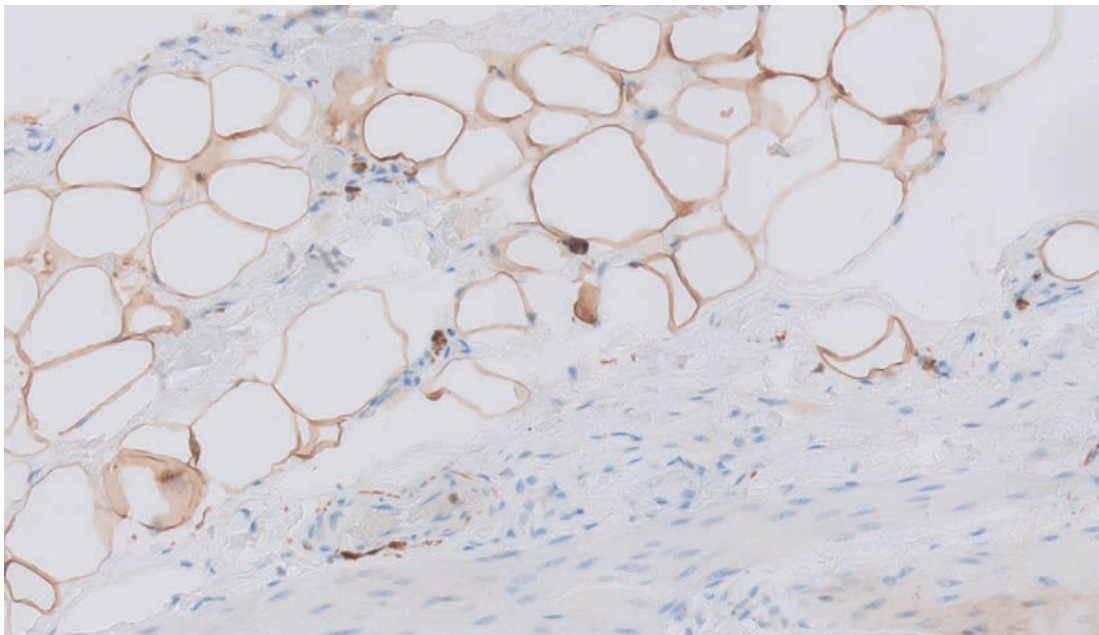
Kidney (20x)

**Antibody:** Polyclonal Rabbit Anti-S100  
**Clone:** Polyclonal  
**Code:** GA504 | IR504

Reaction Location	Nucleus and cytoplasm
Quality Control	Colon/Appendix
High Expression	Satellite and Schwann cells of the peripheral nerves in Auerbach's plexus show a moderate to strong staining reaction.
Low Expression	Adipocytes show a weak to moderate staining reaction.
Non-expression	Epithelial and smooth muscle cells.



Colon (20x)

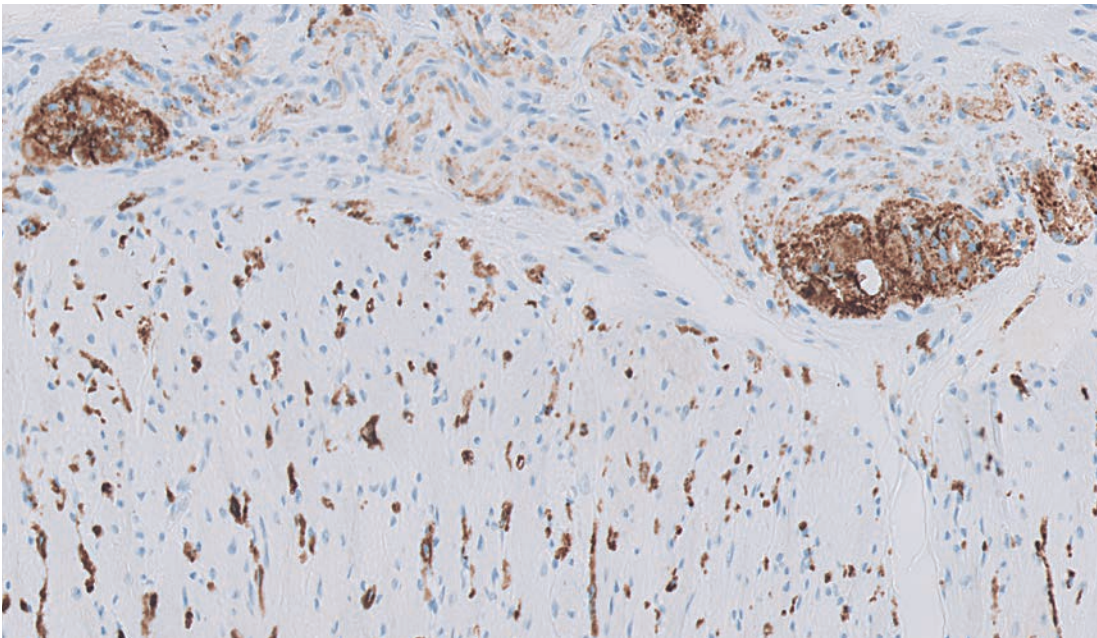


Colon (20x)

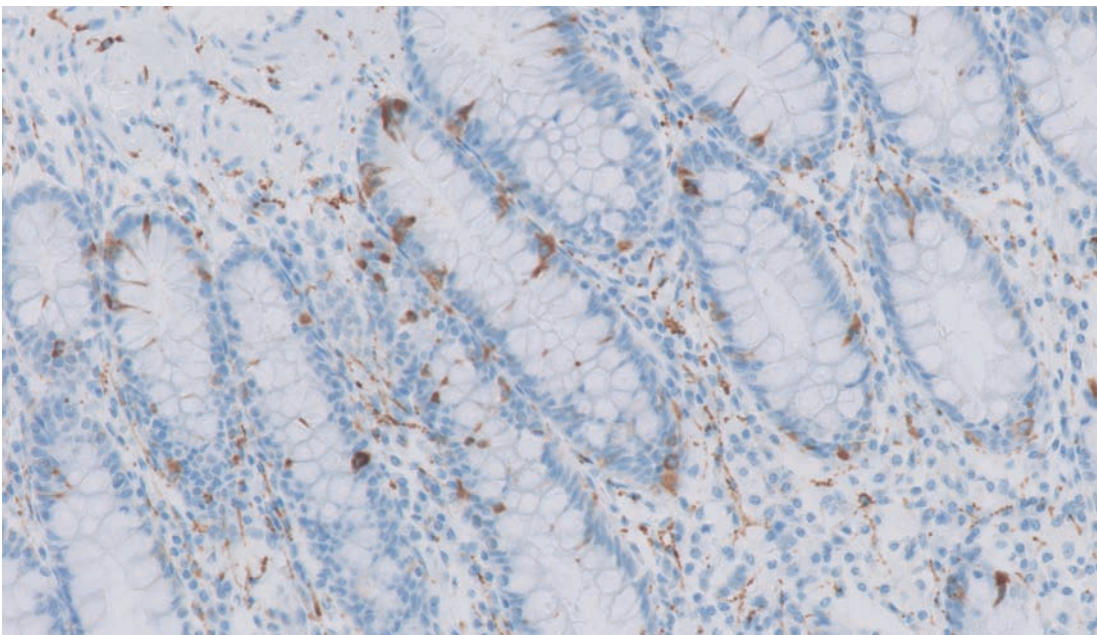
**Antibody:** Monoclonal Mouse Anti-Human  
**Clone:** **Synaptophysin**  
**Code:** DAK-SYNAP  
GA660 | IR660

Reaction Location	Cytoplasm
Quality Control	Colon/Appendix
High Expression	Peripheral nerves in the tunica muscularis show a moderate to strong staining reaction.
Low Expression	Endocrine cells in the epithelial surface show a weak to moderate staining reaction.
Non-expression	Epithelial cells.

Note: Occasionally, cytoplasmic labeling of goblet cells in colon and small intestine can be observed.



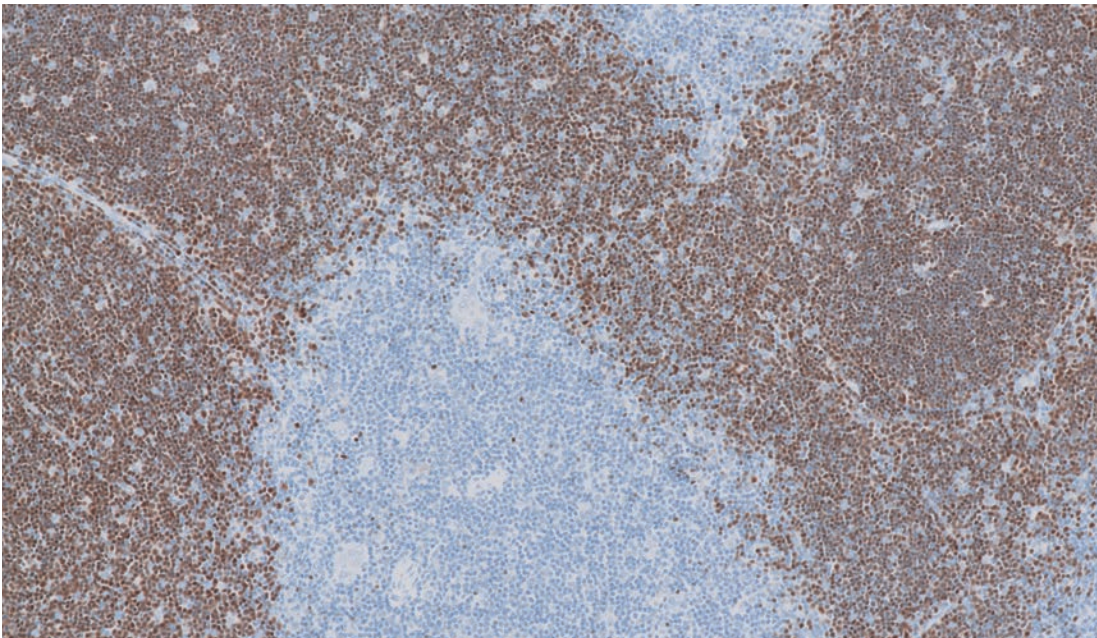
Colon (20x)



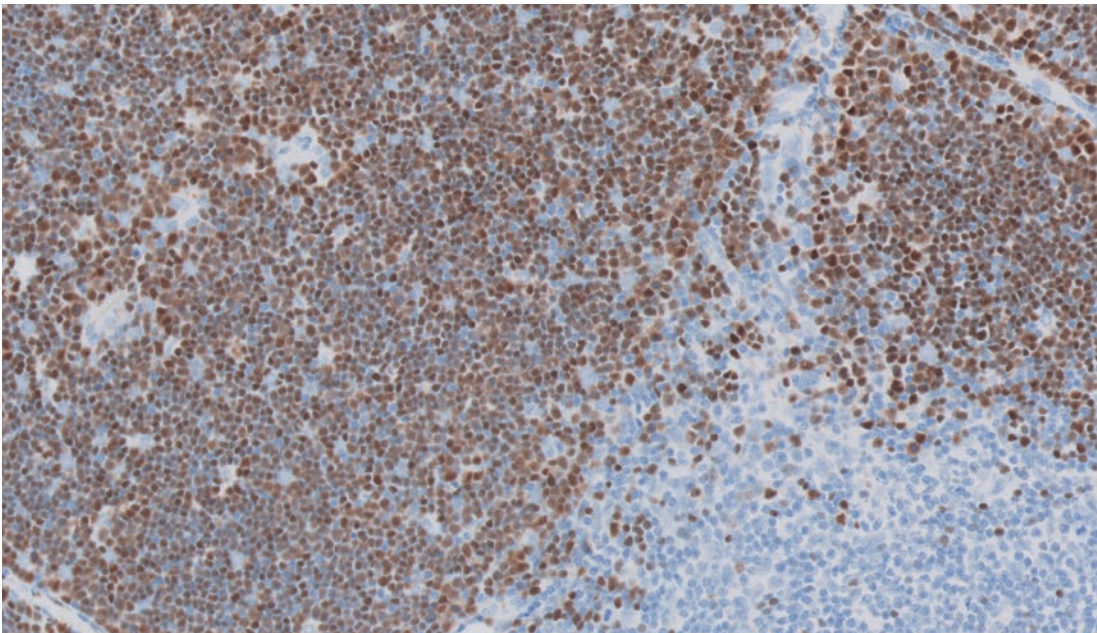
Colon (20x)

**Antibody:** Monoclonal Rabbit Anti-Human  
**Clone:** Terminal Deoxynucleotidyl Transferase (TdT)  
**Code:** EP266  
IR093

Reaction Location	Nucleus
Quality Control	Thymus
High Expression	The subcapsular and cortical thymocytes show a moderate to strong staining reaction.
Low Expression	NA
Non-expression	Medullar thymocytes.



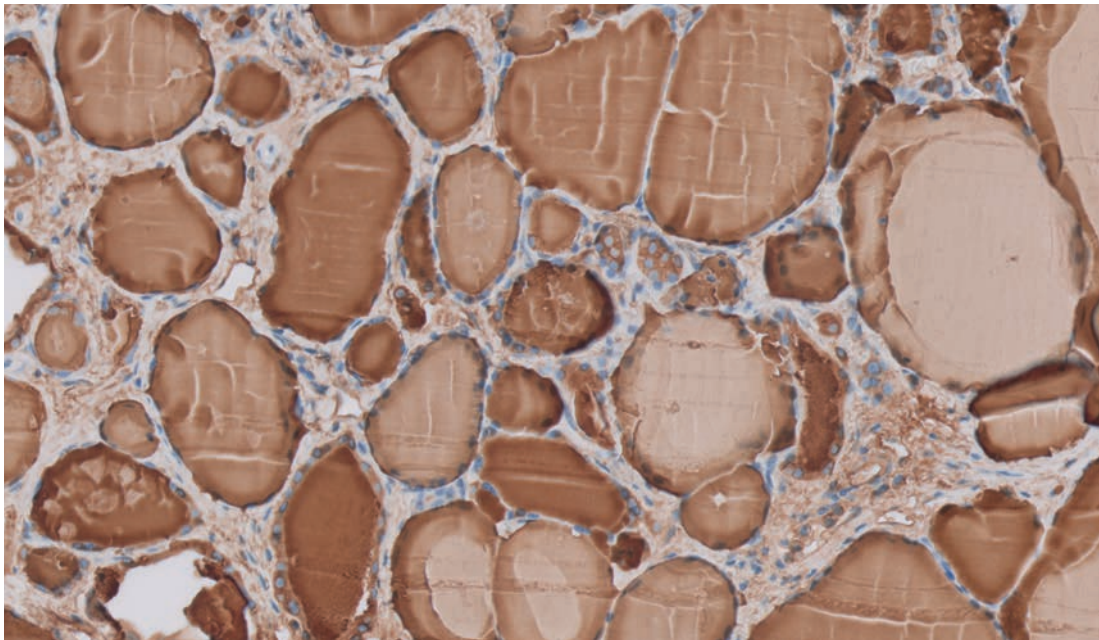
Thymus (10x)



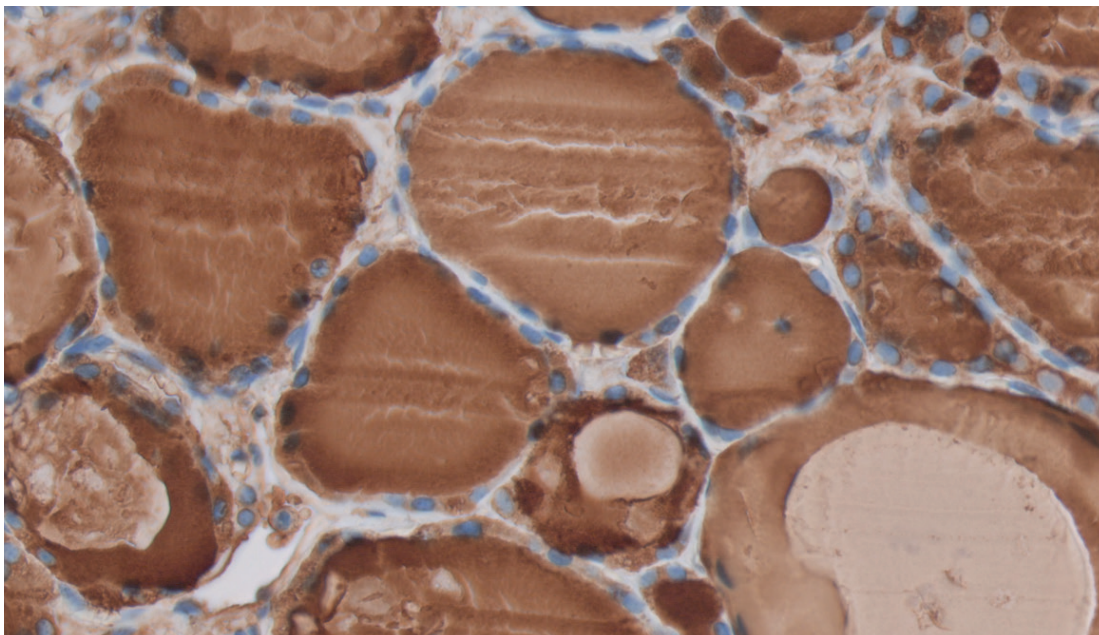
Thymus (20x)

**Antibody:** Polyclonal Rabbit Anti-Human  
**Clone:** Thyroglobulin  
**Code:** Polyclonal  
GA509 | IR509

Reaction Location	Cytoplasm
Quality Control	Thyroid
High Expression	Extracellular colloid shows a moderate to strong staining reaction.
Low Expression	Columnar follicular epithelial cells show a weak to moderate staining reaction.
Non-expression	NA



Thyroid (20x)



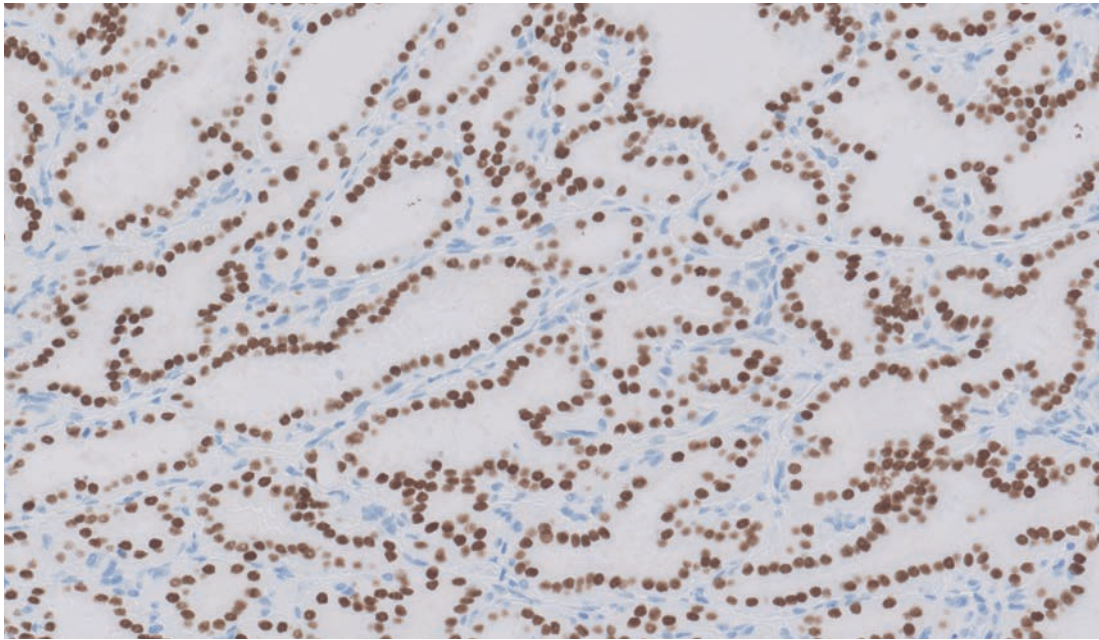
Thyroid (40x)



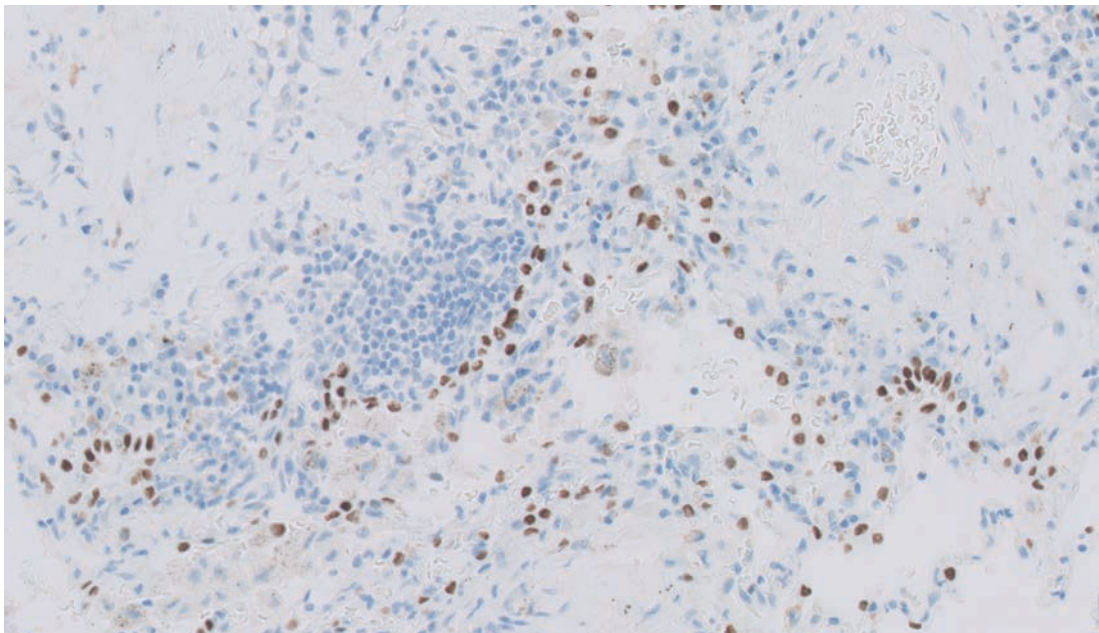
**Antibody:** Monoclonal Mouse Anti-  
**Thyroid Transcription Factor**  
**Clone:** 8G7G3/1  
**Code:** IR056

Reaction Location	Nucleus	
Quality Control	Thyroid	Lung
High Expression	Thyroid follicular epithelial cells show a moderate to strong staining reaction.	Type II pneumocyte cells lining the alveolar walls show a moderate to strong staining reaction.
Low Expression	NA	NA
Non-expression	NA	NA

Note: Occasionally, a weak staining reaction may be observed in columnar epithelial cells of the respiratory ducts.



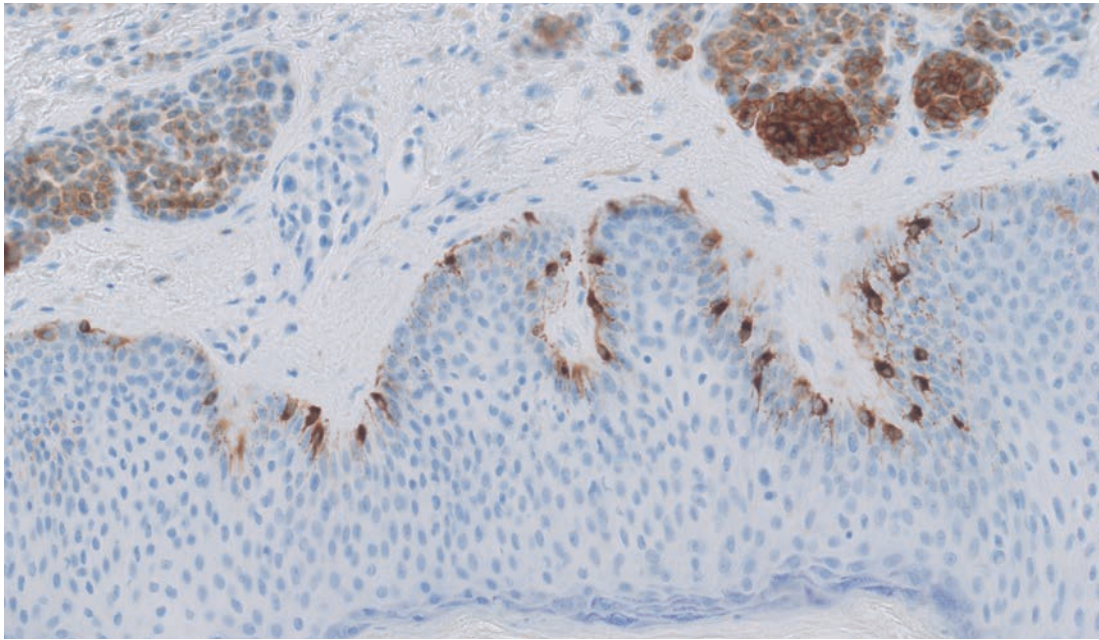
Thyroid (20x)



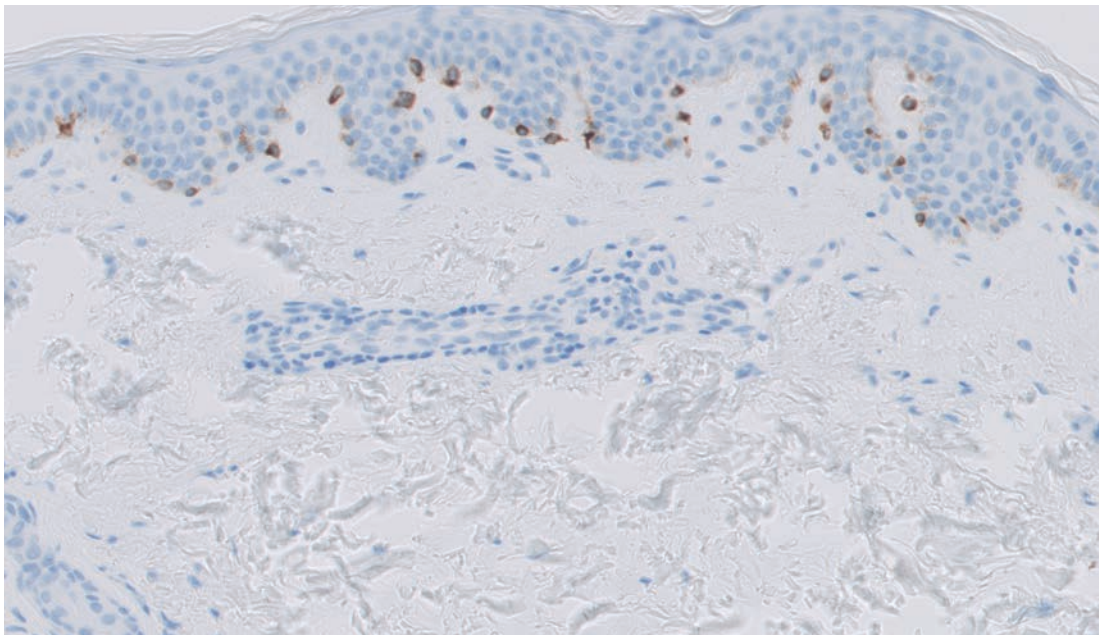
Lung (20x)

**Antibody:** Monoclonal Mouse Anti-Human Tyrosinase  
**Clone:** T311  
**Code:** IR061

Reaction Location	Cytoplasm	
Quality Control	Nevus	Skin
High Expression	Nevus cells of the dermis and the melanocytes in the basal layer of the epidermis show a moderate to strong staining reaction.	NA
Low Expression	NA	Melanocytes in the basal layer of the epidermis show a weak to moderate staining reaction.
Non-expression	Squamous epithelial cells.	NA



Nevus (20x)

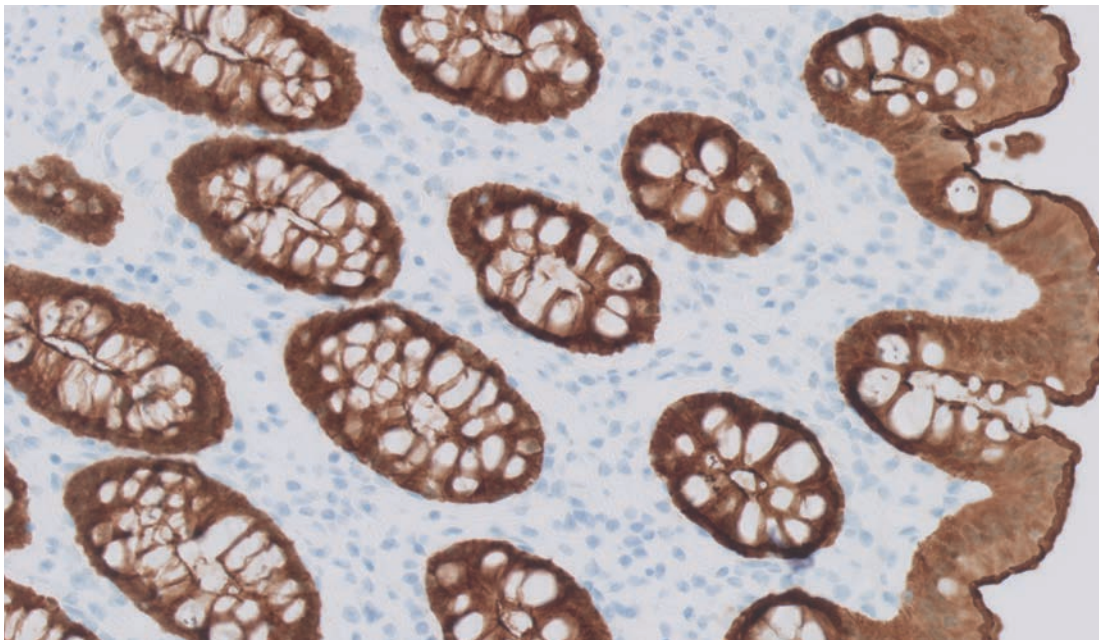


Nevus (20x)

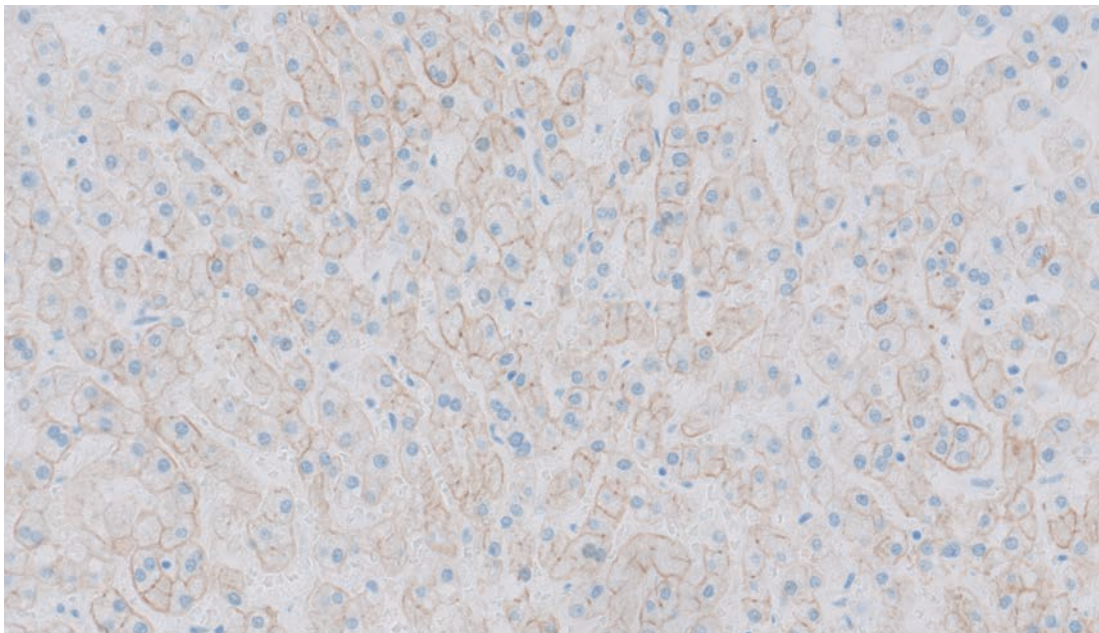
Antibody: Monoclonal Mouse Anti-Villin  
 Clone: 1D2 C3  
 Code: IR076

Reaction Location		Membrane and cytoplasm
Quality Control	Colon/Appendix	Liver
High Expression	Epithelial cells show a moderate to strong predominantly membranous staining reaction. The cytoplasm will typically show a diffuse and weak staining reaction.	NA
Low Expression	NA	Hepatocytes show a weak to moderate membranous staining reaction with no, or only a minimal, cytoplasmic staining reaction.
Non-expression	Lymphocytes in lamina propria.	NA

Note: Cytoplasmic staining may be accompanied by nuclear staining.



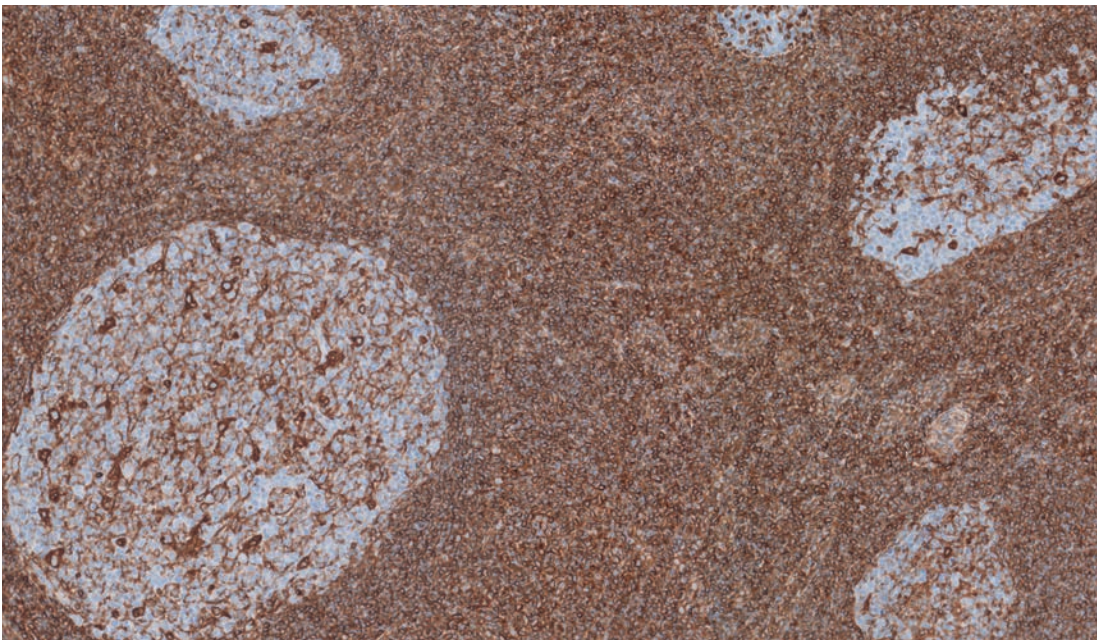
Colon (20x)



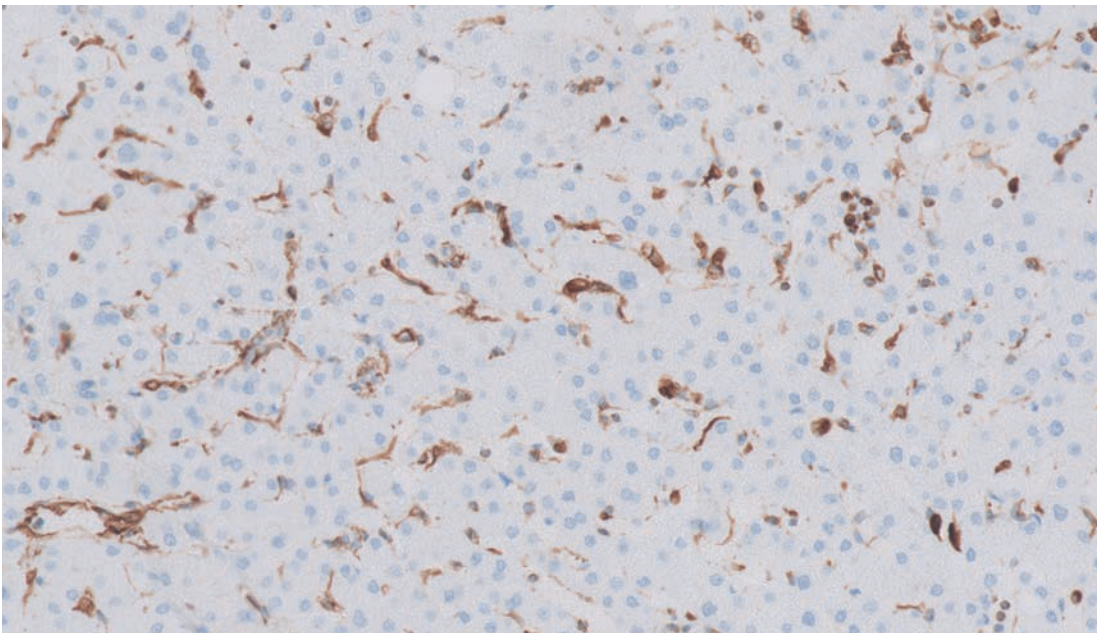
Liver (20x)

**Antibody:** Monoclonal Mouse Anti-Human  
**Clone:** Vimentin  
**Code:** GA630 | IR630

Reaction Location	Cytoplasm	
Quality Control	Tonsil	Liver
High Expression	Lymphocytes and endothelial cells show a moderate to strong staining reaction.	Kupffer cells and lymphocytes show a moderate to strong staining reaction.
Low Expression	NA	Sinusoid smooth muscle cells show a weak to moderate staining reaction.
Non-expression	NA	Hepatocytes



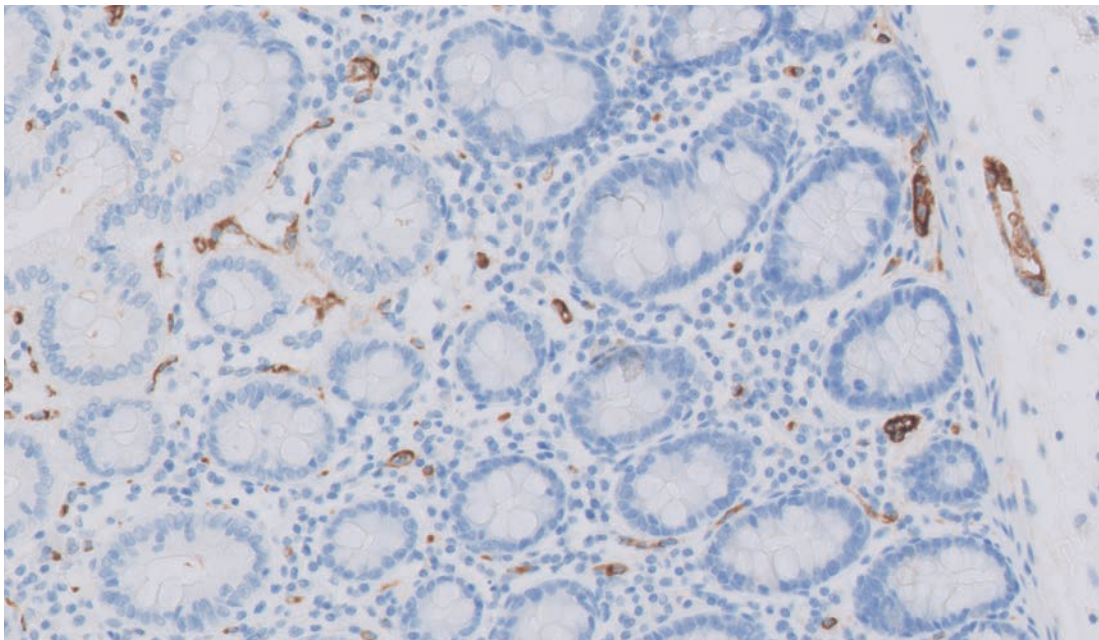
Tonsil (10x)



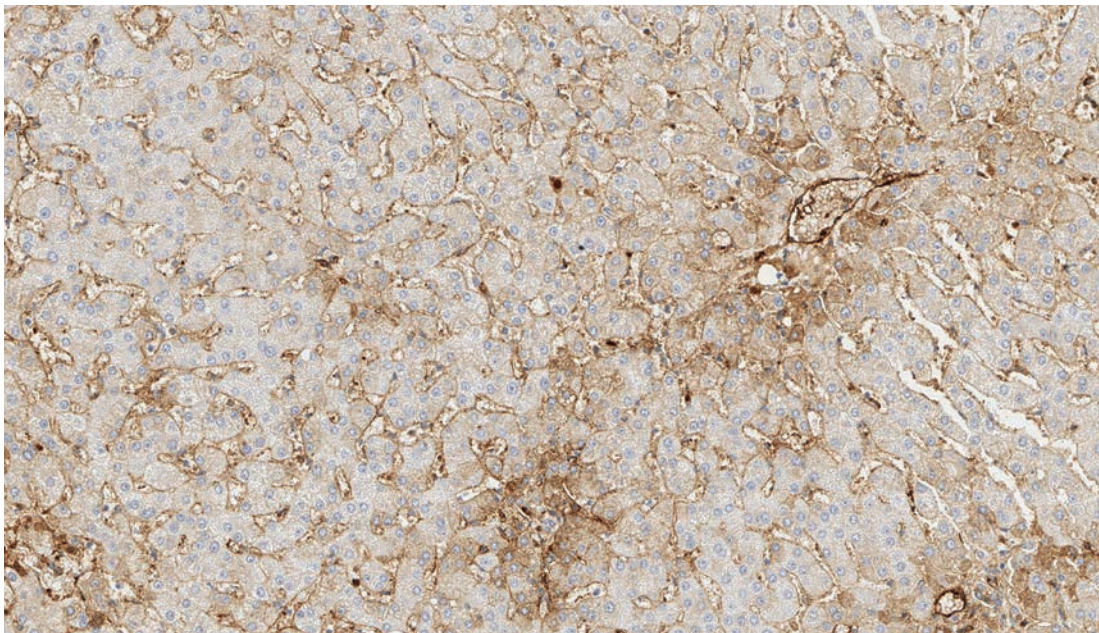
Liver (20x)

**Antibody:** Polyclonal Rabbit Anti-Human  
**Clone:** Von Willebrand Factor  
**Code:** Polyclonal  
 GA527 | IR527

Reaction Location		Cytoplasm	
Quality Control	Appendix/Colon	Liver	
High Expression	Endothelial cells in the vessels in the lamina propria show a moderate to strong staining reaction.	Endothelial cells in large vessels show a moderate to strong staining reaction.	
Low Expression	NA	Endothelial cells lining the sinusoids show a weak to moderate staining reaction.	
Non-expression	Epithelial cells.	NA	



Colon (20x)

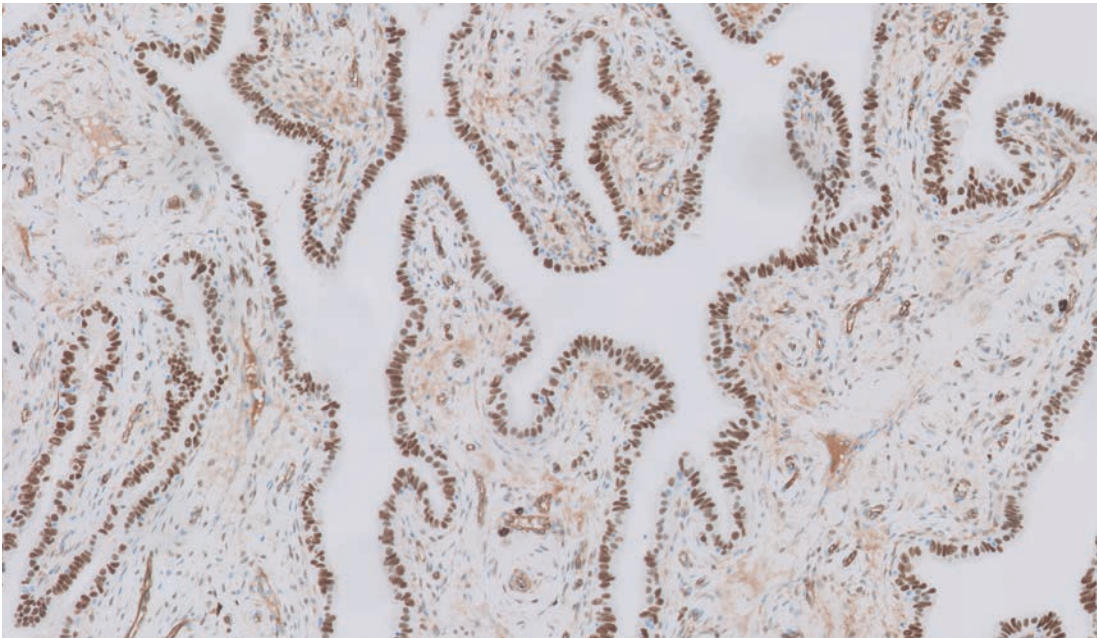


Liver (10x)

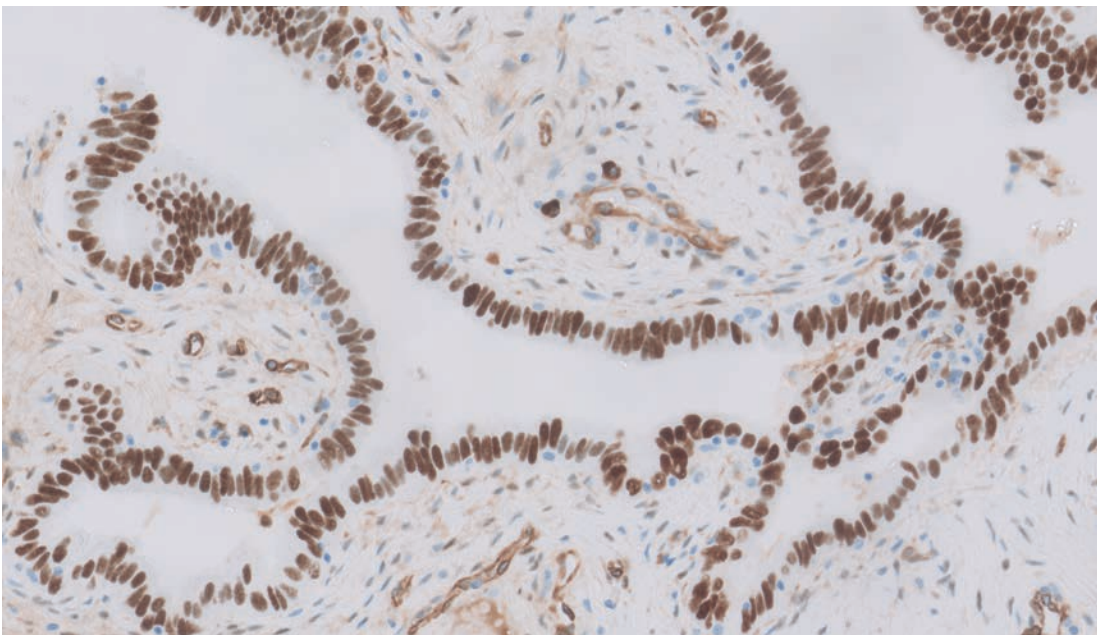
**Antibody:** Monoclonal Mouse Anti-Human  
**Clone:** Wilms' Tumor 1 Protein  
**Code:** 6F-H2e  
 IR055

Reaction Location	Nucleus
Quality Control	Fallopian tube
High Expression	Epithelial cells and the majority of stromal smooth muscle cells show a moderate to strong nuclear staining reaction. A weak cytoplasmic background staining in these cells is accepted.
Low Expression	NA
Non-expression	NA

Note: Endothelial cells will typically show a moderate to strong cytoplasmic staining reaction.



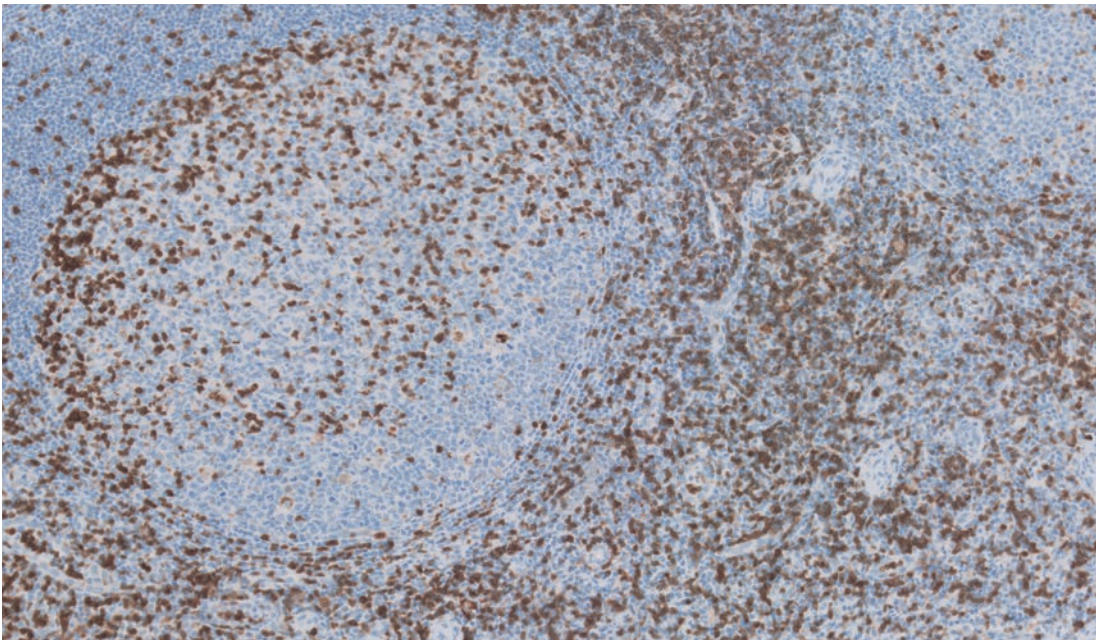
Fallopian tube (10x)



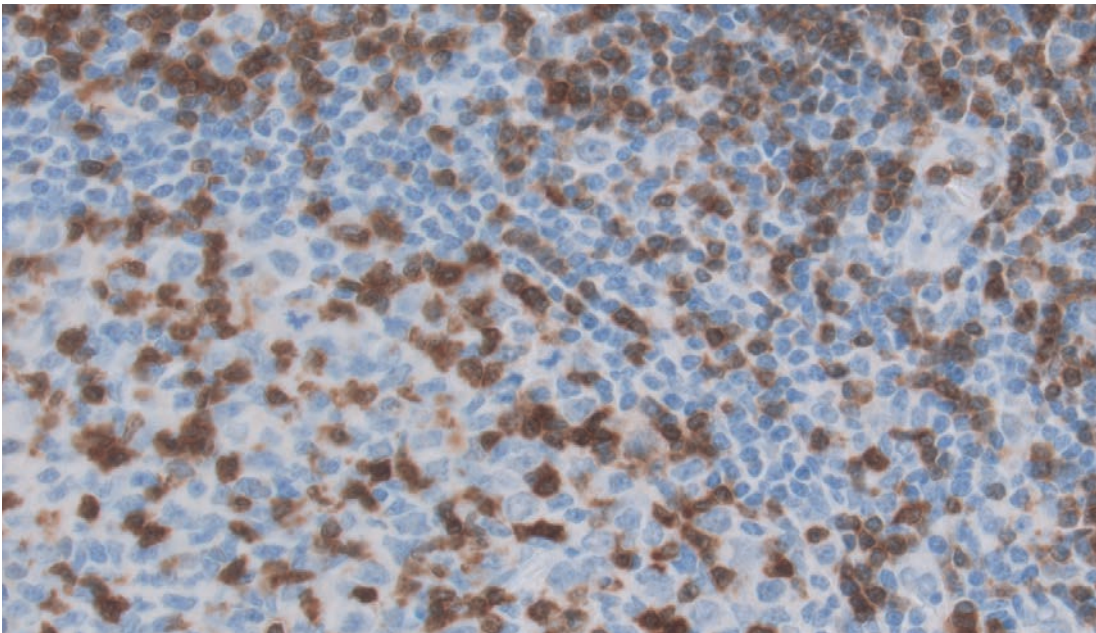
Fallopian tube (20x)

**Antibody:** Monoclonal Mouse Anti-Human  
**Clone:** ZAP-70  
**Code:** 2F3.2  
IR653

Reaction Location	Nucleus and cytoplasm
Quality Control	<b>Tonsil</b>
High Expression	Isolated T cells in the germinal center show a moderate to strong staining reaction.
Low Expression	Crowded T cells in the T zone show a weak to moderate staining reaction.
Non-expression	Germinal center B cells.



Tonsil (10x)



Tonsil (40x)

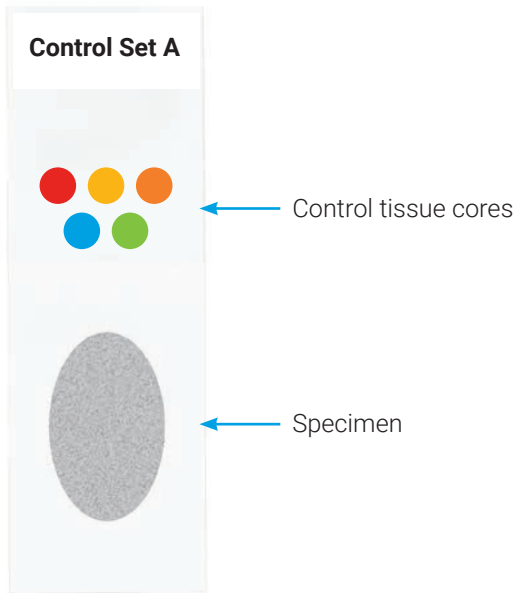
# Appendix

## On-slide controls

We recommend using small, core tissue sections attached to the same glass slide as the test specimen for each staining. For inspiration we have suggested three different, standard control sets of five tissue cores which will cover over 75% of the FLEX RTU antibodies in this Atlas of Controls.

Control Set A	Control Set B	Control Set C
Tonsil (Red)	Tonsil (Red)	Breast/Breast hyperplasia (White)
Colon (Yellow)	Kidney (Purple)	Skin/Nevus (Black)
Appendix (Orange)	Brain (Grey)	Placenta (Light Blue)
Liver (Blue)	Prostate (Pink)	Thyroid (Light Green)
Pancreas (Green)	Thymus (Dark Blue)	Cervix (Light Purple)

## Glass slide with on-slide control tissue



**The recommendation of on-slide control tissue cores in these combinations is by no means intended to override the Instructions for Use and the professional judgment of a certified pathologist. The contents are provided as information only, and Agilent Dako neither claims nor warrants the universal validity of the information provided as there are national and professional differences in the acceptance of the relevance of various markers and related quality control tissues.**



Antibody	Clone	Code		Quality Control #1	Quality Control #2	Control Set A	Control Set B	Control Set C
						Tonsil Colon Appendix Liver Pancreas	Tonsil Kidney Brain Prostate Thymus	Breast/Breast hyperplasia Skin/Nevus Placenta Thyroid Cervix
Actin (Muscle)	HHF35		IR700	Colon/Appendix	Tongue			
Actin (Smooth Muscle)	1A4	GA611	IR611	Colon/Appendix	Liver	A		
Alpha-1-Antitrypsin	Polyclonal	GA505	IR505	Tonsil	Liver	A		
Alpha-1-Fetoprotein	Polyclonal	GA500	IR500	Embryonal carcinoma	NA			
AMACR	13H4	GA060	IR060	Prostate adenocarcinoma	Benign prostatic hyperplasia			
Amyloid A	mc1	GA605	IR605	Kidney with amyloidosis	Colon with amyloidosis			
B-Cell-Specific Activator Protein	DAK-Pax5	GA650	IR650	Tonsil	NA	A		
BCL2 Oncoprotein	124		IR614	Tonsil	NA	A		
BCL6 Protein	PG-B6p	GA625	IR625	Tonsil	NA	A		
Beta-Catenin	β-Catenin-1	GA702	IR702	Colon/Appendix	Liver	A		
CA 125	M11	GA701	IR701	Fallopian tube	Appendix			
Calcitonin	Polyclonal	GA515	IR515	Thyroid	NA			C
Caldesmon	h-CD	GA054	IR054	Colon/Appendix	Breast or breast hyperplasia			
Calretinin	DAK-Calret 1		IR627	Colon/Appendix	NA	A		
Carcinoembryonic Antigen	II-7	GA622	IR622	Colon/Appendix	Tonsil	A		
CD1a	010		IR069	Tonsil	Thymus		B	
CD2	AB75	GA651	IR651	Tonsil	Colon/Appendix	A		
CD3	Polyclonal	GA503	IR503	Tonsil	Colon	A		
CD4	4B12		IR649	Tonsil	Liver	A		
CD5	4C7		IR082	Tonsil	NA	A		
CD7	CBC.37	GA643	IR643	Tonsil	Colon/Appendix	A		
CD8	C8/144B	GA623	IR623	Tonsil	NA	A		
CD10	56C6	GA648	IR648	Liver	Tonsil	A		
CD15	Carb-3	GA062	IR062	Tonsil	Kidney		B	
CD19	LE-CD19	GA656	IR656	Tonsil	Colon/Appendix	A		
CD20cy	L26	GA604	IR604	Tonsil	Liver	A		
CD21	1F8		IR608	Tonsil	NA	A		
CD23	DAK-CD23	GA781	IR781	Tonsil	NA	A		
CD30	Ber-H2	GA602	IR602	Tonsil	NA	A		
CD31, Endothelial Cell	JA70A	GA610	IR610	Colon/Appendix	Tonsil	A		
CD34, Class II	QBEnd 10	GA632	IR632	Liver	Colon/Appendix	A		
CD43	DF-T1	GA636	IR636	Tonsil	Colon/Appendix	A		
CD45, Leucocyte Common Antigen	2B11 + PD7/26	GA751	IR751	Tonsil	Brain		B	
CD56	123C3		IR628	Colon/Appendix	Tonsil	A		
CD57	TB01	GA647	IR647	Tonsil	Colon/Appendix	A		
CD68	KP1	GA609	IR609	Tonsil	Brain		B	
CD68	PG-M1	GA613	IR613	Tonsil	Brain		B	
CD79α	JCB117	GA621	IR621	Tonsil	NA	A		
CD99, Ewing's Sarcoma Marker	12E7		IR057	Thymus	NA		B	
CD138	MI15	GA642	IR642	Tonsil	Colon/Appendix	A		
CD246, ALK Protein	ALK1	GA641	IR641	Anaplastic large cell lymphoma with t(2;5) translocation	NA			
CDX-2	DAK-CDX-2	GA080	IR080	Appendix	Pancreas	A		
Chorionic Gonadotropin	Polyclonal	GA508	IR508	Placenta	NA			C

Antibody	Clone	Code		Quality Control #1	Quality Control #2	Control Set A	Control Set B	Control Set C
						Tonsil Colon Appendix Liver Pancreas	Tonsil Kidney Brain Prostate Thymus	Breast/Breast hyperplasia Skin/Nevus Placenta Thyroid Cervix
Cyclin D1	EP12	GA083	IS083	Tonsil	NA	A		
Cytokeratin	AE1/AE3	GA053	IR053	Liver	NA	A		
Cytokeratin 5/6	D5/16 B4	GA780	IS780	Tonsil	Prostate		B	
Cytokeratin 7	OV-TL12/30	GA619	IR619	Pancreas	NA	A		
Cytokeratin 8/18	EP17/EP30		IR094	Liver	Tonsil	A		
Cytokeratin 17	E3		IR620	Skin	Breast hyperplasia			C
Cytokeratin 18	DC10	GA618	IR618	Liver	NA	A		
Cytokeratin 19	RCK108	GA615	IR615	Liver	Tonsil	A		
Cytokeratin 20	Ks20.8	GA777	IR777	Colon/Appendix	NA	A		
Cytokeratin, High Molecular Weight	34βE12	GA051	IR051	Tonsil	Prostate		B	
Cytomegalovirus	CCH2 + DDG9		IR752	Cytomegalovirus infected tissue	NA			
Desmin	D33		IR606	Colon/Appendix	Striated muscle			
E-Cadherin	NCH-38	GA059	IR059	Colon/Appendix	Liver	A		
Epithelial Antigen	Ber-EP4	GA637	IR637	Colon/Appendix	Kidney			
Epithelial Membrane Antigen	E29	GA629	IR629	Tonsil	Breast			
Epstein-Barr Virus, LMP	CS.1-4		IR753	Burkitt lymphoma/ leukemia (EBV+)	EBV+ tissue			
ERCC1	4F9		IR091	Colon/Appendix	NA	A		
Estrogen Receptor α	1D5		IR657	Cervix	NA			C
Estrogen Receptor α	EP1	GA084	IR084	Cervix	Breast hyperplasia			
Ets-Related Gene (ERG)	EP111	GA659	IR659	Tonsil	Colon/Appendix	A		
Gastrin	Polyclonal	GA519	IR519	Stomach	NA			
GCDFP-15	22A3	GA077	IR077	Breast hyperplasia	Skin			C
Glial Fibrillary Acidic Protein	Polyclonal	GA524	IR524	Brain	Colon			
Helicobacter Pylori	Polyclonal	GA523	IR523	Gastric mucosa	NA			
Hepatocyte	OCH1E5	GA624	IR624	Liver	NA	A		
Herpes Simplex Virus Type 1	Polyclonal	GA521	IS521	Lesion with HSV	NA			
IgA	Polyclonal	GA510	IR510	Tonsil	NA	A		
IgD	Polyclonal		IR517	Tonsil	NA	A		
IgG	Polyclonal	GA512	IR512	Tonsil	NA	A		
IgM	Polyclonal	GA513	IR513	Tonsil	NA	A		
Inhibin α	R1	GA058	IR058	Testis	Placenta			
Insulin	Polyclonal		IR002	Pancreas	NA	A		
Kappa Light Chains	Polyclonal	GA506	IR506	Tonsil	NA	A		
Ki-67 Antigen	MIB-1	GA626	IR626	Tonsil	NA	A		
Lambda Light Chains	Polyclonal	GA507	IR507	Tonsil	NA	A		
Mammaglobin	304-1A5	GA074	IR074	Skin	Breast hyperplasia			C
Mast Cell Tryptase	AA1		IR640	Tonsil	Colon	A		
Melan-A	A103		IR633	Skin	Adrenal gland			
Melanosome	HMB45	GA052	IR052	Nevus	NA			C
MUC2	CCP58		IR658	Colon/Appendix	NA	A		
MUC5AC	CLH2		IR661	Cervix	Gastric			
MUM1 Protein	MUM1p	GA644	IR644	Colon/Appendix	Tonsil	A		
MutL Protein Homolog 1 (MLH1)	ES05		IR079	Colon/Appendix	Tonsil	A		
MutS Protein Homolog 2 (MSH2)	FE11		IR085	Colon/Appendix	Tonsil	A		

Antibody	Clone	Code		Quality Control #1	Quality Control #2	Control Set A	Control Set B	Control Set C
						Tonsil Colon Appendix Liver Pancreas	Tonsil Kidney Brain Prostate Thymus	Breast/Breast hyperplasia Skin/Nevus Placenta Thyroid Cervix
MutS Protein Homolog 6 (MSH6)	EP49		IR086	Colon/Appendix	NA	A		
Myeloperoxidase	Polyclonal	GA511	IR511	Liver	Tonsil	A		
Myogenin	F5D	GA067	IR067	Rhabdomyosarcoma	Leiomyosarcoma			
Myosin Heavy Chain (Smooth Muscle)	SMMS-1		IR066	Appendix	Uterus			
Neurofilament Protein	2F11	GA607	IR607	Colon/Appendix	NA	A		
Neuron-Specific Enolase	BBS/NC/VI-H14		IR612	Colon/Appendix	Pancreas	A		
Nucleophosmin	376	GA652	IR652	Liver	Brain			
Octamer-Binding Transcription Factor 3/4	N1NK		IR092	Seminoma	NA			
p53 Protein	DO-7	GA616	IR616	Colon adenocarcinoma	Colon/Appendix			
p63 Protein	DAK-p63	GA662	IR662	Tonsil	NA	A		
Placental Alkaline Phosphatase	8A9		IR779	Placenta	NA			C
Pneumocystis Jiroveci	3F6		IR635	Lung (P. jiroveci infection)	NA			
Podoplanin	D2-40		IR072	Appendix	NA	A		
Postmeiotic Segregation Increased 2 (PSM2)	EP51		IR087	Colon/Appendix	NA	A		
Progesterone Receptor	PgR 636		IR068	Cervix	NA			C
Progesterone Receptor	PgR 1294	GA090		Cervix	NA			C
Prostate-Specific Membrane Antigen	3E6		IR089	Prostate	NA		B	
Prostein	10E3		IR088	Prostate	NA		B	
Renal Cell Carcinoma Marker	SPM314	GA075	IR075	Kidney	NA		B	
S100	Polyclonal	GA504	IR504	Colon/Appendix	NA	A		
Synaptophysin	DAK-SYNAP	GA660	IR660	Colon/Appendix	NA	A		
Terminal Deoxynucleotidyl Transferase	EP266		IR093	Thymus	NA		B	
Thyroglobulin	Polyclonal	GA509	IR509	Thyroid	NA			C
Thyroid Transcription Factor	8G7G3/1		IR056	Thyroid	Lung			
Tyrosinase	T311		IR061	Nevus	Skin			C
Villin	1D2 C3		IR076	Colon/Appendix	Liver	A		
Vimentin	V9	GA630	IR630	Tonsil	Liver	A		
Von Willebrand Factor	Polyclonal	GA527	IR527	Colon/Appendix	Liver	A		
Wilms' Tumor 1 Protein	6F-H2		IR055	Fallopian tube	NA			
ZAP-70	2F3.2		IR653	Tonsil	NA	A		

This information is subject to change without notice.

© Agilent Technologies, Inc. 2020  
Published in the USA, February 24, 2020  
00230 D58532 2020FEB12

